

# Superficial digital flexor tendon and associated tenosynovial disorders in sport horses: a clinical case series

<sup>1</sup>Constantin Lazăr, <sup>1</sup>Iulian Mihăilă, <sup>1</sup>Iulia Straton, <sup>2</sup>Aude-Gaëlle Heitzmann-Ziegler, <sup>1</sup>Vasile Vulpe

<sup>1</sup> Department of Clinics, Faculty of Veterinary Medicine, "Ion Ionescu de la Brad" University of Life Sciences, Iași, Romania; <sup>2</sup> Clinique Vétérinaire de Grosbois, Domaine de Grosbois, 94470 Boissy-Saint-Léger, France. Corresponding author: V. Vulpe, vasile.vulpe@iuls.ro

**Abstract.** Injuries of the superficial digital flexor tendon (SDFT) are a leading cause of lameness and reduced athletic performance in sport horses due to the high cyclic strain experienced by this energy-storing tendon, which predisposes it to cumulative microdamage and progressive degeneration (Dowling et al 2000; Thorpe et al 2012). The aim of this study was to describe the clinical and imaging characteristics of SDFT and associated tenosynovial disorders through a descriptive case series involving three sport horses presenting at different stages of tendon pathology. Clinical examination included standardized locomotor assessment and palpation, while imaging evaluation was performed primarily using ultrasonography, complemented by radiography when indicated. Ultrasonographic findings revealed a continuum of lesions ranging from subacute inflammatory tendinopathy to acute core fiber rupture and chronic degenerative remodeling with secondary osseous adaptations. Ultrasonography proved highly sensitive for detecting structural tendon abnormalities, whereas radiography provided complementary information regarding chronic periarticular changes (Reef 2001; Dyson 2004). These results highlight the importance of early multimodal imaging for accurate diagnosis, lesion staging, and prognosis evaluation in equine flexor tendon injuries (Patterson-Kane & Firth 2009).

**Key Words:** tendinopathy, ultrasonography, lameness.

**Introduction.** Musculoskeletal injuries are a major limiting factor in the athletic longevity and performance of sport horses, with tendon disorders representing one of the most challenging conditions in equine orthopedic medicine. Among these, lesions of the superficial digital flexor tendon (SDFT) are particularly significant due to their high incidence, prolonged recovery time, and substantial risk of recurrence following return to exercise (Patterson-Kane & Firth 2009).

The SDFT plays a critical biomechanical role in equine locomotion by functioning as an energy-storing structure that undergoes substantial elastic deformation during the stance phase. This functional specialization allows efficient energy conservation but simultaneously exposes the tendon to repetitive high-strain loading that may approach its physiological limits (Bora et al 2025). As a result, cumulative microdamage develops within the collagen matrix over time, leading to progressive structural degeneration even in the absence of acute trauma (Thorpe et al 2012; O'Brien et al 2021). Such cumulative degenerative processes may reflect broader biological aging mechanisms, in which telomere dynamics have been proposed as potential correlates of tissue longevity and regenerative capacity in animals (Moldovan et al 2025).

At the microscopic level, tendon injury is characterized by disruption of collagen fiber alignment, increased proteoglycan deposition, neovascularization, and altered extracellular matrix composition. These changes reduce tensile strength and impair the tendon's regenerative capacity, explaining the prolonged healing period and high likelihood of reinjury commonly observed in equine athletes (Smith & McIlwraith 2012). Consequently, SDFT pathology is increasingly regarded as a chronic degenerative process rather than a purely inflammatory condition. Beyond biomechanical overload, systemic

and environmental factors may contribute to connective tissue vulnerability through oxidative stress and altered metabolic homeostasis, as suggested by recent findings on heavy metal bioaccumulation and associated hematological alterations in horses from anthropogenic landscapes (Popescu et al 2025).

In addition to intratendinous damage, involvement of surrounding tenosynovial structures is frequently observed in clinical cases. Pathology affecting tendon sheaths, retinacula, and associated ligaments may contribute to clinical signs, influence disease progression, and complicate diagnostic interpretation (Reef 2001). Therefore, comprehensive evaluation of equine flexor tendon injuries requires an integrated approach that considers both tendon integrity and associated anatomical structures.

Diagnostic imaging is essential for accurate assessment of SDFT pathology. Ultrasonography is widely regarded as the gold standard modality due to its ability to provide real-time visualization of tendon architecture, lesion distribution, and healing progression. Radiography, although limited in soft tissue assessment, offers valuable complementary information regarding insertional pathology and chronic osseous remodeling associated with long-standing biomechanical overload (Dyson 2004).

Although numerous studies have investigated equine flexor tendon injuries, clinical case-based descriptions illustrating the progressive continuum of superficial digital flexor tendon pathology—from early tendinopathy to severe fiber rupture and chronic degenerative remodeling with associated tenosynovial involvement—remain relatively limited. Most contemporary research has focused primarily on biomechanical mechanisms, microdamage accumulation, and regenerative therapeutic approaches rather than integrated clinical characterization across different stages of disease evolution (O'Brien et al 2021; Shojaee 2023; Bungărdean et al 2025a, 2025b). Additionally, recent epidemiological and imaging studies emphasize risk factor identification, early detection techniques, and advanced diagnostic modalities, such as power Doppler ultrasonography and elastography, rather than comprehensive clinical staging of lesions (Tamura et al 2024; Secchi et al 2021).

Therefore, the aim of the present study was to describe the clinical, ultrasonographic, and radiographic features of SDFT and associated tenosynovial disorders in sport horses through a descriptive case series representing different stages of disease evolution.

**Material and Method.** This study was conducted as a retrospective descriptive clinical case series involving three sport horses presented for evaluation of forelimb lameness or regional abnormalities suggestive of superficial digital flexor tendon (SDFT) pathology. All examinations were performed within a specialized equine locomotor pathology service.

Each horse underwent a standardized clinical examination protocol that included general physical assessment, static inspection of limb conformation, palpation of the metacarpal tendinous region, and evaluation of local signs such as swelling, heat, pain sensitivity, and structural deformity. Dynamic locomotor examination was performed at walk and trot in a straight line on a firm surface, and flexion tests were conducted when feasible to identify pain-related locomotor abnormalities, following established equine orthopedic examination principles (Dyson 2004).

Ultrasonographic evaluation was performed using a high-frequency linear transducer (7.5–12 MHz) according to standardized scanning protocols for equine metacarpal tendon assessment. Both transverse and longitudinal images were obtained at predefined levels along the metacarpal region. Parameters recorded included tendon cross-sectional area, echogenicity patterns, fiber alignment, lesion localization, and the presence of intratendinous hypoechoic areas or peri-tendinous abnormalities. Whenever possible, findings were compared with the contralateral limb to improve diagnostic accuracy (Reef 2001).

Radiographic examination was performed in cases where chronic pathology or osseous involvement was suspected. Standard dorsopalmar and oblique projections were obtained to evaluate periarticular remodeling, enthesophyte formation, and insertional changes associated with long-standing tendon pathology (Dyson 2004).

Clinical and imaging findings were analyzed descriptively, focusing on lesion morphology, anatomical distribution, severity of structural changes, and evolutionary stage of tendon pathology.

**Case description.** The three cases included in this series involved sport horses of varying ages and athletic disciplines presented for evaluation of forelimb lameness associated with pathology of the flexor apparatus.

Case 1 involved an adult sport mare used for show-jumping that presented with gradually progressive forelimb lameness, accompanied by localized swelling and pain on palpation of the distal metacarpal region.

Case 2 consisted of a middle-aged sport gelding examined for acute onset lameness characterized by heat, swelling, and marked sensitivity along the palmar aspect of the metacarpus.

Case 3 involved an older sport horse with a chronic history of lameness, reduced athletic performance, and palpable thickening of the flexor tendon region, consistent with long-standing structural pathology.

**Results and Discussion.** The three sport horses included in this case series presented with forelimb lameness associated with structural abnormalities of the superficial digital flexor tendon (SDFT) and related tenosynovial structures. Multimodal imaging combining ultrasonography and radiography enabled comprehensive evaluation of lesion morphology, severity, and chronicity, illustrating the progressive continuum of SDFT pathology in athletic horses.

In the first case, clinical examination revealed moderate swelling and localized pain on palpation of the palmar metacarpal region. Radiographic evaluation demonstrated preserved joint alignment with mild periarticular remodeling of the second metacarpal head, consistent with chronic insertional adaptation (Figure 1).

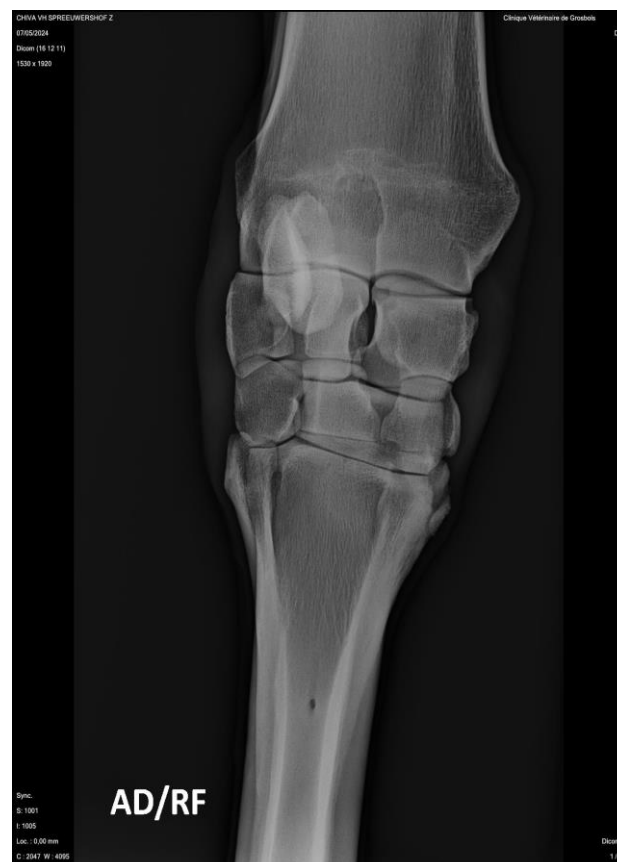

Figure 1. Dorsopalmar radiographic projection of the left carpus (Case 1) demonstrating osseous remodeling of the second metacarpal head, consistent with chronic carpometacarpal/periarticular change.

Ultrasonographic examination also revealed involvement of structures associated with the flexor apparatus at the level of the carpal canal, including synovial effusion and heterogeneous thickening of the flexor retinaculum (Figure 2). These findings are consistent with tendino-synovial pathology affecting peri-tendinous structures rather than the superficial digital flexor tendon itself. Similar ultrasonographic features have been reported in carpal canal disorders associated with flexor apparatus overload and chronic mechanical stress in sport horses (Dyson 2004; Smith et al 2014).

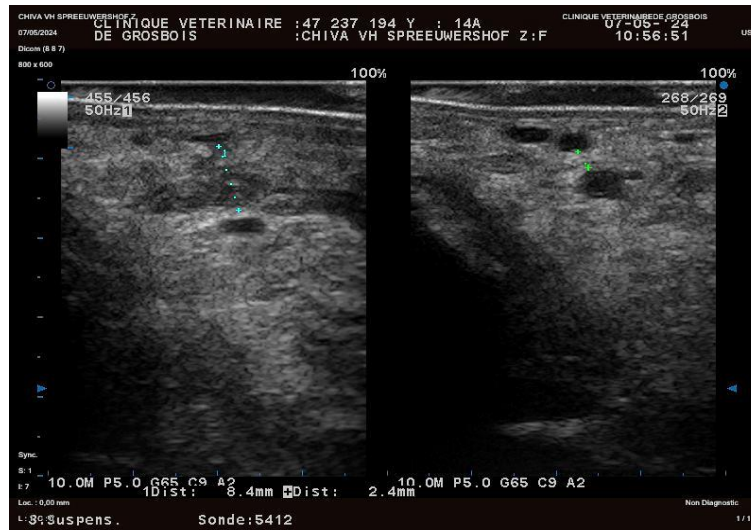


Figure 2. Ultrasonographic image of the left carpal canal in Case 1 showing synovial effusion and thickening of the flexor retinaculum, indicating involvement of structures associated with the flexor apparatus.

The second case presented with acute onset lameness accompanied by marked swelling and pronounced pain sensitivity on palpation of the affected tendon. Clinical inspection revealed clear regional enlargement and increased local heat, consistent with an acute inflammatory response. The degree of pain elicited during palpation suggested significant structural compromise rather than mild peritendinous inflammation, supporting the suspicion of a severe intratendinous lesion.

Ultrasonographic evaluation demonstrated severe tendon enlargement with diffuse loss of normal fibrillar architecture and a large central hypoechoic core lesion consistent with extensive intratendinous fiber rupture (Figure 3). The normal parallel echogenic lines representing organized collagen bundles were replaced by a heterogeneous, predominantly hypoechoic area, indicating fiber discontinuity and intralesional fluid accumulation. The cross-sectional area of the tendon was markedly increased, reflecting edema and hemorrhage secondary to acute fiber disruption.

Core lesions represent a hallmark of acute mechanical overload exceeding the tendon's elastic capacity and are associated with disruption of collagen alignment, increased proteoglycan content, and reduced biomechanical strength. Such lesions develop when tensile forces surpass the tendon's ability to dissipate strain, leading to macroscopic tearing within the central tendon matrix. The resulting structural disorganization compromises the hierarchical arrangement of collagen fibrils, directly affecting tensile strength and elasticity. Increased proteoglycan and water content further alter the mechanical properties of the tissue, contributing to reduced stiffness and diminished load-bearing capacity.

From a pathophysiological perspective, the acute phase involves hemorrhage, edema, and inflammatory cell infiltration, followed by fibroblast proliferation and reparative scar tissue formation. However, tendon healing is characterized by repair rather than true regeneration, with newly formed collagen exhibiting inferior organization and mechanical properties compared to the original structure. This incomplete structural restoration explains the high susceptibility to reinjury, and the guarded prognosis



Ultrasonographic evaluation revealed pronounced hypertrophy of the SDFT, severe disruption of fibrillar organization, and multiple intratendinous hypoechoic regions consistent with chronic degenerative remodeling accompanied by ongoing microdamage (Figure 5). Chronic SDFT injuries are characterized by progressive accumulation of structural fatigue, alterations in collagen cross-linking, and reduced elasticity, ultimately leading to irreversible matrix degeneration (Thorpe et al 2012; O'Brien et al 2021).

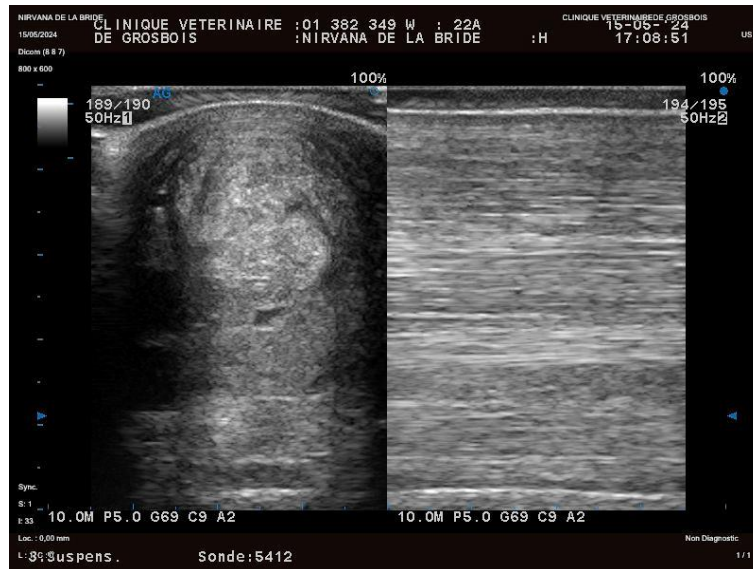

Figure 5. Split-screen ultrasonographic image (Case 3) combining transverse and longitudinal views of the superficial digital flexor tendon, illustrating heterogeneous intratendinous architecture compatible with chronic tendinopathy under clinical follow-up.

The comparative analysis of the three cases illustrates the well-recognized pathological continuum of equine SDFT injury, progressing from subacute inflammatory tendinopathy to acute fiber rupture and chronic degenerative remodeling. This progression reflects the combined effects of repetitive mechanical loading, insufficient biological repair, and gradual weakening of the tendon matrix. Similar evolutionary patterns have been reported in both experimental and clinical studies of equine flexor tendon pathology (Patterson-Kane & Firth 2009).

Ultrasonography proved to be the most sensitive diagnostic modality for detecting tendon enlargement, alterations in echogenicity, and disruption of fiber architecture, confirming its central role in the evaluation and monitoring of equine tendon injuries. Radiography, although limited in soft tissue assessment, provided valuable complementary information regarding chronic osseous remodeling and insertional pathology associated with long-standing tendon disease (Reef 2001; Dyson 2004).

Additionally, the frequent involvement of tenosynovial structures observed in this case series supports previous findings indicating that SDFT injuries rarely occur as isolated lesions. Synovial effusion, retinacular desmopathy, and peri-tendinous inflammation are commonly associated with tendon pathology and may significantly influence clinical presentation and prognosis (Reef 2001).

Overall, these observations emphasize the importance of early imaging diagnosis, as prompt detection of subclinical or early-stage lesions may improve prognosis, facilitate appropriate therapeutic intervention, and reduce the risk of reinjury in sport horses.

**Conclusions.** This case series highlights the broad clinical and imaging spectrum of superficial digital flexor tendon (SDFT) and associated tenosynovial disorders encountered in sport horses, ranging from subacute inflammatory tendinopathy to acute intratendinous fiber rupture and chronic degenerative remodeling with secondary osseous adaptation. The findings confirm that SDFT pathology rarely occurs as an isolated condition and frequently involves surrounding tenosynovial structures, including the flexor retinaculum and synovial compartments.

Ultrasonography proved to be the most sensitive diagnostic modality for detecting tendon enlargement, alterations in echogenicity, fiber disorganization, and focal intratendinous lesions, while radiography provided valuable complementary information regarding chronic periarticular remodeling and insertional changes. The combined use of these imaging techniques allowed accurate characterization of lesion severity, chronicity, and anatomical extent.

The progressive differences observed among the three cases illustrate the continuum of equine SDFT injury, in which repetitive biomechanical loading leads to cumulative microdamage, impaired tissue repair, and gradual structural degeneration. Early imaging diagnosis remains essential, as prompt detection of subclinical or early-stage lesions may improve prognosis, support appropriate therapeutic intervention, and reduce the risk of recurrence in athletic horses.

This study has several limitations inherent to clinical case series, including the small sample size and the descriptive, retrospective nature of the analysis, which restricts extrapolation of findings to larger populations. However, the cases illustrate a representative spectrum of superficial digital flexor tendon pathology encountered in sport horses. Prognosis in such conditions is closely related to lesion severity and chronicity, with acute intratendinous fiber disruption generally associated with more favorable outcomes compared to chronic degenerative remodeling, which carries an increased risk of recurrence and long-term performance limitations.

**Acknowledgements.** The authors would like to acknowledge the staff of the equine diagnostic imaging service for their technical assistance and support during the clinical examinations. Special thanks are extended to the horse owners for their cooperation and for allowing the use of clinical data and imaging records for scientific purposes.

**Conflict of interest.** The author declares that there is no conflict of interest.

## References

- Bora F. D., Rusu T., Popescu M., Coroian C. O., Petrescu-Mag I. V., 2025 Extremotolerant pioneer species for cold, arid, oligotrophic, low-pressure environments. *ELBA Bioflux* 17(1):15-21.
- Bungărdean D., Pall E., Daradics Z., Popescu M., Tripon M. A., Lupșan A. F., Marcus I., Morar I. A., Bora F. D., Crecan C. M., 2025a Regenerative intra-articular therapy with PRP and hyaluronic acid in equine stifle lameness: Integration with controlled exercise. *HVM Bioflux* 17(1):1-12.
- Bungărdean D., Pall E., Daradics Z., Popescu M., Tripon M. A., Lupșan A. F., Marcus I., Morar I. A., Bora F. D., Crecan C. M., 2025b Regenerative intralesional therapy with platelet-rich plasma and hyaluronic acid for equine proximal suspensory desmitis: Clinical outcomes following integration with controlled exercise. *HVM Bioflux* 17(1):13-25.
- Dowling B. A., Dart A. J., Hodgson D. R., Smith R. K., 2000 Superficial digital flexor tendonitis in the horse. *Equine Veterinary Journal* 32(5):369-378.
- Dyson S. J., 2004 Medical management of superficial digital flexor tendonitis: a comparative study in 219 horses (1992-2000). *Equine Veterinary Journal* 36(5):415-419.
- Moldovan B., Maxim A., Bora F. D., Kovacs E., Coroian C., Petrescu-Mag I. V., 2025 Telomeres and lifespan in animals: Limiting clock or correlated biomarker? *HVM Bioflux* 17(1):44-48.
- O'Brien C., Marr N., Thorpe C., 2021 Microdamage in the equine superficial digital flexor tendon. *Equine Veterinary Journal* 53(3):417-430.
- Patterson-Kane J. C., Firth E. C., 2009 The pathobiology of exercise-induced superficial digital flexor tendon injury in Thoroughbred racehorses. *The Veterinary Journal* 181(2):79-89.
- Popescu M., Tripon M. A., Lupșan A. F., Bungărdean D., Crecan C. M., Musteata M., Pașca P. M., Mârza S. M., Purdoi R. C., Papuc I., Lăcătuș R., Lăcătuș C. M., Panait L. C.,

- Patrichi T. S., Matei I.-R., Sisea C.-R., Bunea C. I., Călugăr A., Petrescu-Mag I. V., Daradics Z., Bora F.-D., 2025 Sentinel equines in anthropogenic landscapes: Bioaccumulation of heavy metals and hematological biomarkers as indicators of environmental contamination. *Toxics* 13(12):1064. <https://doi.org/10.3390/toxics13121064>
- Reef V. B., 2001 Superficial digital flexor tendon healing: ultrasonographic evaluation of therapies. *Veterinary Clinics of North America: Equine Practice* 17(1):159–178.
- Secchi V., Masala G., Corda A., Corda F., Potop E., Barbero Fernandez A., Pinna Parpaglia M. L., Sanna Passino E., 2021 Strain elastography of injured equine superficial digital flexor tendons: a reliability study of manual measurements. *Animals* 11(3):795. <https://doi.org/10.3390/ani11030795>
- Shojaee A., 2023 Equine tendon mechanical behaviour: prospects for repair and regeneration applications. *Veterinary Medicine and Science* 9(5):2053–2069.
- Smith R. K. W., McIlwraith C. W., 2012 Consensus on equine tendon disease: Building on the 2007 Havemeyer symposium. *Equine Veterinary Journal* 44(1):2–6.
- Smith R., McIlwraith W., Schweitzer R., Kadler K., Cook J., Catterson B., Dakin S., Heinegård D., Screen H., Stover S., Crevier-Denoix N., Clegg P., Collins M., Little C., Frisbie D., Kjaer M., van Weeren R., Werpy N., Denoix J.-M., Carr A., Goldberg A., Bramlage L., Smith M., Nixon A., 2014 Advances in the understanding of tendinopathies: a report on the Second Havemeyer Workshop on equine tendon disease. *Equine Veterinary Journal* 46(1):4–9.
- Tamura N., Yoshihara E., Seki K., Mae N., Kodaira K., Iimori M., Yamazaki Y., Mita H., Urayama S., Kuroda T., Ohta M., Kasashima Y., 2024 Prognostic value of power doppler ultrasonography for equine superficial digital flexor tendon injury in thoroughbred racehorses. *The Veterinary Journal* 306:106179. <https://doi.org/10.1016/j.tvjl.2024.106179>
- Thorpe C. T., Udeze C. P., Birch H. L., Clegg P. D., Screen H. R., 2012 Specialization of tendon mechanical properties results from interfascicular differences. *Journal of the Royal Society Interface* 9(76):3108–3117.

Received: 11 November 2025. Accepted: 08 December 2025. Published online: 30 December 2025.

Authors:

Constantin Lazăr, Department of Clinics, Faculty of Veterinary Medicine, "Ion Ionescu de la Brad" University of Life Sciences, Iași, Romania, 8 Mihail Sadoveanu Alley, 700489 Iași, Romania, e-mail: margivet\_srl@yahoo.com

Iulian Mihăilă, Department of Clinics, Faculty of Veterinary Medicine, "Ion Ionescu de la Brad" University of Life Sciences, Iași, Romania, 8 Mihail Sadoveanu Alley, 700489 Iași, Romania, e-mail: iulian.mihaila@iuls.ro

Iulia Straton, Department of Clinics, Faculty of Veterinary Medicine, "Ion Ionescu de la Brad" University of Life Sciences, Iași, Romania, 8 Mihail Sadoveanu Alley, 700489 Iași, Romania, e-mail: iulia.straton@iuls.ro

Aude-Gaëlle Heitzmann-Ziegler, Clinique Vétérinaire de Grosbois, Domaine de Grosbois, 94470 Boissy-Saint-Léger, France, e-mail: aude.heitzmann@grosbois.eu

Vasile Vulpe, Department of Clinics, Faculty of Veterinary Medicine, "Ion Ionescu de la Brad" University of Life Sciences, Iași, Romania, 8 Mihail Sadoveanu Alley, 700489 Iași, Romania, e-mail: vasile.vulpe@iuls.ro

This is an open-access article distributed under the terms of the Creative Commons Attribution License, which permits unrestricted use, distribution and reproduction in any medium, provided the original author and source are credited.

How to cite this article:

Lazăr C., Mihăilă I., Straton I., Heitzmann-Ziegler A.-G., Vulpe V., 2025 Superficial digital flexor tendon and associated tenosynovial disorders in sport horses: a clinical case series. *HVM Bioflux* 17(1):77-84.