

Importance of early diagnosis of atherosclerosis at the level of carotid artery on routine OPT

¹Anida-Maria Băbțan, ¹Claudia N. Feurdean, ¹Anca Ionel, ¹Willi A. Uriciuc, ¹Radu Chifor, ²Charles-Edouard Bizzari, ¹Aranka Ilea

¹IIIrd Department – Oral Rehabilitation, Faculty of Dentistry, “Iuliu Hațieganu” University of Medicine and Pharmacy, Cluj-Napoca, Romania; ² Graduated student of Faculty of Dentistry, “Iuliu Hațieganu” University of Medicine and Pharmacy, Cluj-Napoca, Romania.

Abstract. Objective: The study’s objective was to assess the degree of awareness in the dental community of Cluj-Napoca regarding the presence of atherosclerosis at the level of the common carotid artery that can appear on routine dental panoramic radiographs. Material and method: An online questionnaire including orthopantomographic images was distributed among the dental students in the 5th and 6th year as well as to the resident dental students and dentists, all studying either graduated from “Iuliu Hațieganu” University of Medicine and Pharmacy, Cluj-Napoca, Romania. Results: 90.7% of dental students in Cluj-Napoca (5th and 6th year as well as graduated dentists), were unaware to the calcified lesions present at the level of the common carotid artery on a panoramic radiograph, from which 100% lack of awareness in 5th year students’ group, 4% of awareness in 6th year students and 20% in experienced dentists. Conclusion: Panoramic radiographs are an indispensable diagnostic tool routinely used in dental examinations, which can contribute effectively to the early diagnosis of atherosclerosis, with no additional cost to either public or private health systems. It is important to increase the awareness of our dental community and remind us that we must provide a medical act not only as a dental practitioner but also as a health care provider able to consider all clinical findings and communicate them within the shortest time to the general medicine specialist.

Key Words: orthopantomography; atherosclerosis; dentist; diagnosis

Copyright: This is an open-access article distributed under the terms of the Creative Commons Attribution License, which permits unrestricted use, distribution, and reproduction in any medium, provided the original author and source are credited.

Corresponding Author: A.M. Băbțan, email: anidamaria.babtan@gmail.com

Introduction

Despite major advancements in prevention and treatment of stroke, according to the World Stroke Organization (WSO) we account 13,7 million of new stroke each year. Globally one over four people over the age of 25 will have a stroke in their lifetime (Wahlgren et al 2016). Most death in Romania are due to stroke, the standardized death rate of acute myocardial infarction was the highest in EU in 2014 and cerebrovascular diseases, the second highest in the EU, also contribute significantly to mortality (Country & Profile, 2017). Between 1994 and 2017, 6,281,873 persons died in Romania, stroke being registered as the underlying cause of death in 959,319 cases (Ioacara et al 2019). From the 13.7 million of annual stroke, 5.5 million are leading to death. Last but not least over 116 millions years of healthy life is lost each year due to stroke-related death and disability (Lindsay et al 2019). The statistics and guidelines of the WSO are significantly relevant and provide information that should be used to inform communication with all internal and external stakeholders in order to reduce the global burden of stroke. Atherosclerosis of the carotid artery is the most common cause of stroke and when such lesions are calcified, they may easily be identified on a panoramic radiograph since the carotid bifurcation lies within the field of a properly performed X-ray

(Almog et al 2004). Toxic lifestyles including smoking, sedentarism, poor diet, stress, alcohol abuse, are all contributing factors to the development of atherosclerosis, by increasing the blood pressure and changing the hemodynamic forces through the narrowed lumen, the endothelium lying plaque will eventually disrupt and create an ulcer where the thrombus formation will occur (Arai 2014).

Atherosclerosis is a multifactorial disease involving the interplay of genetic and environmental factors. Common Carotid Artery Plaque (CCAP) formation (Figure 1) is characterized initially by the disruption of the endothelium of the carotid artery, at the level of its bifurcation, due to a high blood pressure often combined with stress and cigarette smoking, and a lower shear rate caused by the flow separation (Arai 2014). From the damaged, hyper-permeable endothelium, infiltrate serum lipoproteins and platelets-derived growth factor (PDGF). The lipoproteins will lodge in the intima of the artery and PDGF will initiate the proliferation of smooth muscles cells (SMC). The elevated and thickened intima lesion will calcify, mainly at the intima-media level, and protrude into the vessel lumen. Therefore, with the contribution of hemodynamic forces of the blood flow through the narrowed lumen, the endothelium lying

plaque will eventually disrupt and create an ulcer where the thrombus formation will occur (Arai 2014).

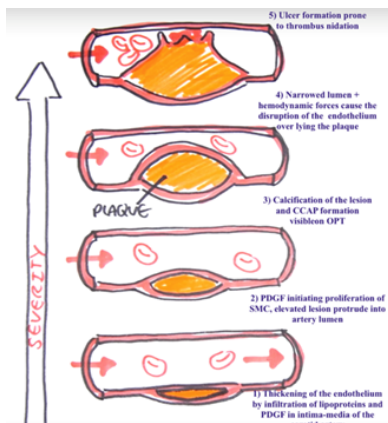


Figure 1 - Schematic drawing of CCAP and atherosclerosis pathogenesis steps and severity.

The CCAP is considered a dystrophic calcification where there are deposited calcium salts in chronically inflamed or necrotic tissues and the presence of an atheromatous plaque in the extra-cranial vascular path is the main cause for vasculo-cerebral embolism and obstructive disease (Kuriakose & Xiao 2020). The calcification appears as radio-opaque nodular mass or as two radio-opaque vertical lines adjacent to or right below the intervertebral spaces between C3 and C4. CCAP must be distinguished from other anatomical radio-opacities, such as styloid process, stylo-hyoid and stylo-mandibular ligaments, hyoid bone, greater horn of the hyoid bone, epiglottis, great horn of the thyroid cartilage (Badshah et al 2017). These anatomical landmarks should represent a help rather than a confusion in the identification of CCAP on OPT. The next schematic (Figure 2) represents different pathological calcified lesions, that can appear also as radio-opacities on panoramic radiographs and should

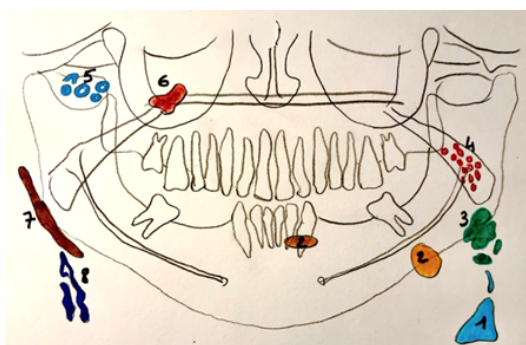


Figure 2: Schematic of physiological and pathological calcifications for the differential diagnosis of CCAP on panoramic radiographs. 1= Triticeous & Thyroid cartilage, 2= Sialoliths, 3= Calcified lymph nodes, 4= Tonsiloliths, 5= Phleboliths, 6= Anthrolith, 7= Ossified stylo-hyoid ligament, 8= Calcified Carotid Artery Plaque (CCAP).

be differentiated from CCAP. In dentistry, general health conditions can sometimes be primarily detected just from an accurate dental examination. In this study, we emphasize the utility of routine panoramic radiograph, which enable us, as dentist, to detect a general condition that might be critical. The interested region on the X-ray lies between the region of the ramus

and the angle of the mandible and the base of the neck, within the soft tissues, more precisely at or below the level of the intervertebral space of C3 and C4. From panoramic radiographs we identify these nodular or vertical radio-opacities as CCAP. It is in 1998, in an Australian dental journal that Friedlander Arthur and Friedlander Ida were published for the first time writing about atherosclerotic lesions occurring at the bifurcation of the common carotid artery visible on a panoramic radiograph (Friedlander & Friedlander, 1998). Cardiovascular disease can be prevented when risk factors are identified early. The incidence of CCAP on panoramic radiographs, and periodontitis have both been associated with increased risk of cardiovascular disease. The examination and ability to identify a CCAP by oral health care providers on panoramic films has therefore a significant role in the early diagnosis of atherosclerosis in the carotid artery (ACA) (Friedlander & Friedlander 1998). Hence it would be a great contribution from the community of dentist to be aware of CCAP lesion while the examination of panoramic radiograph taken routinely in their dental clinics and help to reduce the global burden of stroke. Friedlander mentioned that a particular attention should be given to patients over 55 years old and with a medical history of hypertension, diabetes mellitus, high blood cholesterol and coronary artery disease or patients with sedentary behaviours, including smoking, high alcohol consumption, or unhealthy diet coupled with overweight which are all well known to be associated with atherosclerosis and stroke (Friedlander & Friedlander 1998). The dental community ought to play their part and contribute within their means to the early diagnosis of patient at risk of having a cardiovascular attack, which means firstly by identifying a suspected CCAP and secondly by transferring, within the shortest time, the patient to a cardiovascular department that will proceed to the confirmation of the suspected diagnosis and initiate afterwards an adapted treatment preventing a potential stroke.

Image 1 shows in an edentulous patient, the main radioopaque structures of the two maxillas, the surrounding structures and the radiological appearance of the common carotid artery calcifications. Adapting image 1 by placing 4 vertical lines in order

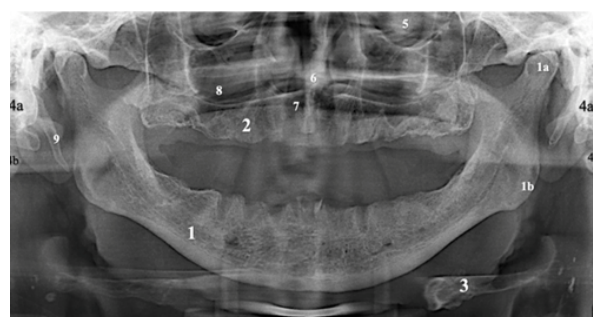


Image 1 - OPG of an edentulous patient presenting calcified lesion at the level of the bifurcation of the carotid artery. 1= Mandible body, 1a= mandible condyle, 1b= mandible angle, 1a= mandibular condyle, 1b= Mandible angle, 2= Maxilla, 3= Hyoid bone, 3a= Greater horn of the hyoid, 4= Cervical Vertebra (4a=C2, 4b=C3, 4c=C4), 5= Orbit, 6= Nasal septum, 7= Inferior nasal concha, 8= maxillary sinus, 9= Styloid process, 10= Triticeous cartilage, 11= Epiglottis, 12= superior horn of thyroid cartilage, 13= Bifurcation of the common carotid artery presenting nodular calcification. Written and informed consent obtained from (UFBA_UESC_DENTAL_IMAGES dataset).

to divide the panoramic into four identical rectangles, the reader can see that the red line represents the midline and the blue lines are separating each half (left and right) into lateral and medial quarter (Image 2). Sequent, RM & RL are standing for Right Medial and Right Lateral quarters, whereas LM & LL for Left Medial and Left Lateral quarters. Image 3 represents a

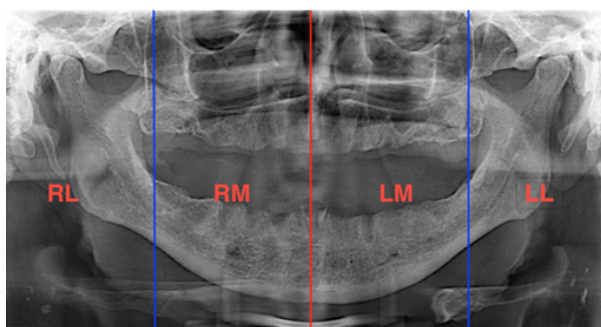


Image 2 - OPT of an edentate patient presenting calcified lesion at the level of the bifurcation of the carotid artery. Red line= Midline, right and left blue lines dividing the OPT into 4 rectangles, named: RL= right lateral, RM= right medial, LM= left medial, LL= left lateral.

magnification of LL rectangle in Image 2, with the purpose of visualizing the main area of this study: the bifurcation of the carotid artery. The image evidences the presence of three nodular radio-opacities. The common carotid artery originates from the aorta artery, it then branches into the internal and the external artery. The bifurcation level presents some variations, however it is usually found at the level of C4 or inter vertebral space level between C3 and C4 or at the upper margin of the thyroid cartilage (Kurkcuoglu *et al.*, 2017).

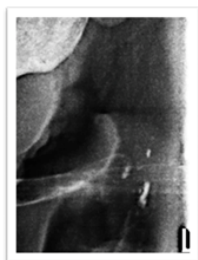

Image 3 - Calcification at the level of the common carotid artery (CCA).

Different articles mention the lack of awareness, among the dental community, towards CCAP lesion on OPT or even that dentists have historically limited their participation in the prevention of stroke (Friedlander & Friedlander 1998; Kats *et al* 2018; Roldán-Chicano *et al* 2006a). To this date nonetheless, no scientific studies have been conducted in order to evaluate the degree of awareness of the dental community and support this statement. The study will be conducted with the hypothesis that there is a significant lack of awareness among our dental community of Cluj-Napoca towards a potential life-threatening lesion, the presence of atherosclerosis at the level of the common carotid artery that can appear on routine dental panoramic radiographs.

Material and method

The study will assess the degree of awareness of dental community of Cluj-Napoca, Romania regarding atherosclerosis opacities on panoramic radiographs. We hypothesize that >50% would not notify CCAP lesions on panoramic X-rays. In order to achieve a relevant representation of our dental community awareness, we chose to make a statistical analysis from answers obtained through an online questionnaire distributed among the dental students in the 5th and 6th year as well as to the resident dental students and dentists that would represent a sample with more experiences.

Inclusion criteria

The most important inclusion criteria relative to this study was to represent the dental community of Cluj-Napoca, that are or will work routinely on panoramic radiographs. In addition, we include only the dental professional that are actually studying or have already graduated from the same university - "Tuliu Hatieganu" University of Medicine and Pharmacy, Cluj-Napoca, Romania.

Exclusion criteria

In the same manner the exclusion criteria are all dental practitioners and dental students coming from another dental community and university. Any students in medicine and pharmacy are also excluded from the study.

Questionnaire development

In the aim to facilitate the collection of answers and to represent as good as possible the dental community of Cluj-Napoca, the study has been conducted by the mean of a google form which was distributed online on different student and dentist platforms. This method was able to reach a fair amount of the targeted community and allowed a good distribution between students and graduated dentists.

The online questionnaire was divided into two sections. In the first section, the subject must mention if he or she is a dental student or a graduated dentist. In the second section, the questionnaire is composed of 5 open questions with the possibility to respond by short answers. The choice to address only 5 questions was to promote a high number of answers and maintain an optimal level of awareness among the subjects. Each one of the 5 open question includes a panoramic radiograph all independent from each other. From these panoramic radiographs, we ask the same following question: "From the following radiographs, please observe carefully and describe the first pathological radio-opacity appearing to your eyes". Within the 5 panoramic radiographs, two panoramic x-rays were randomly placed in the questionnaire, representing the studied lesion (CCAP). The three other panoramic x-rays had a role to represent "non-CCAP" OPT obtained during a usual day of practice in a dental clinic. They were in this case representing respectively the following pathological calcification: pulp stones at the level of the teeth 1.5 and 2.6, hypercementosis in lower arch and the third x-ray an impacted wisdom tooth - 4.8 due to an odontoma. The panoramic radiographs used in this study were obtained from UFBA_UESC_DENTAL_IMAGES dataset, who allowed us, after signing an agreement, to demonstrate these radiographs in the context of academic publication and presentations. We

obtained from UFBA_UESC_DENTAL_IMAGES dataset an informed and written consent.

Data collection

From the first multiple choice question of the questionnaire, requesting one single answer we can obtain, by the mean of excel software, a statistical distribution between dental student, residents and dentist with and without specialty who have answered the form. Concerning the collection of data from the open questions we have proceeded by a content analysis, meaning that we have gathered all the answers and to sort them into 2 different categories. The first category would gather all the answers that were not describing the atherosclerosis lesion at the level of the CCA. And the second category, would be all the answers describing the pathological opacification in the CCA on at least one of the 2 OPG that presented the lesion in the questionnaire. Once we have proceeded to the content analysis, we obtain binary results, simply identifiable by “yes” and “No”, or “aware” and “not aware”, the results have been placed then in an Excel Table, which then have allowed us to illustrate our results under the forms of graphics.

Results

In total, the dental community population who answered the questionnaire was represented by 10 dentists with specialization, 8 dentists without specialization, 13 residents in dental specialty and 68 students, which was respectively divided into 10 students in the 5th year and 45 students in the 6th year (Table 1, Figure 3).

Table 1: Socio-demographic distribution among the dental community of Cluj-Napoca answering the questionnaire

Status in dentistry	Sample Number (Total = 86)	% Percentage distribution
5 th year Student	10	11.6%
6 th year Student	45	52.3%
Resident	13	15.1%
Dentist without specialty	8	9.3%
Dentist with specialty	10	11.6%

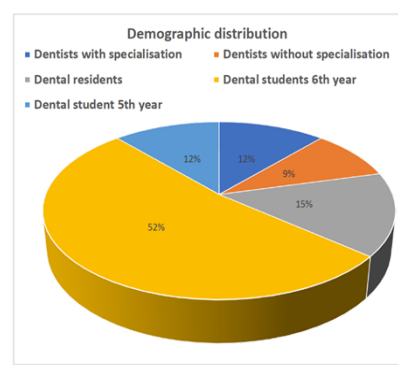


Figure 3: Distribution of the dental community answering the questionnaire

We can see from this graphical illustration and from the Table 1, that we obtained most answers from the students, especially from the student in the 6th year with 45 answers, representing 52% of all answers. The second majority of the subjects are represented by the dental resident with 13 answers, representing 15% of all our subjects. In third position come together in the same proportion the subgroup of dentists with specialty as well as the subgroup of dental student in the 5th year. Finally, we have the dentists without specialty who encountered 9% of the total sample collected.

After the analysis of the content of our open questions individually (Table 2), we have obtained the following results:

Table 2: Distribution of awareness among each subgroup of the sample population of the dental community of Cluj-Napoca

Sample subgroups	Aware practitioners (positive answers)	Unaware practitioners (negative answers)
5 th year Student	0	10
6 th year Student	2	45
Residents	0	13
Dentist without specialty	2	6
Dentist with specialty	4	9

The next graphic (Figure 4) will show us the repartition of the individuals who have recognize the atherosclerosis sign at least once out of the 2 OPG on the questionnaire that presented the lesion. The repartition of the individuals who correctly identified the CCAP lesions, on at least one out of the 2 OPG which presented the lesion, while answering our questionnaire are 50% the subcategory representing the dentists with specialty, 25% from the subcategory of the dentist without specialty and finally 25% from the group of the dental students in the 6th year. From

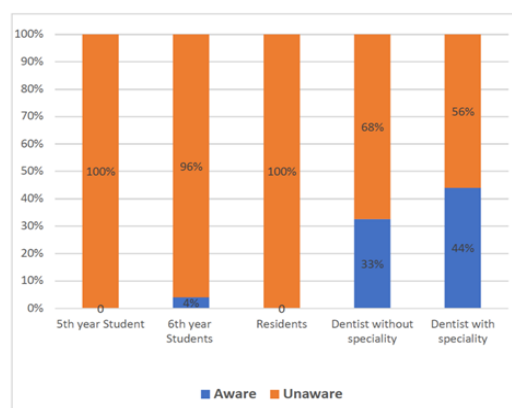


Figure 4: Histogram representing the percentage of awareness among each subcategory of the sample population of the dental community of Cluj-Napoca

the representation of the histogram (Figure 4), we can identify that the subcategory who showed the best awareness regarding CCAP lesion is by 44% the dentists with specialty, secondly, we find another experimented subcategory, the one from the dentist without specialty having 33% of awareness and the last

subcategory who has described the lesion by two individuals is the one represented by the 6th year students with 4% of awareness. On the other hand, the 5th year students' group and the residents has shown 100% of unawareness towards the atherosclerosis lesion present on the 2 panoramic radiographs in the questionnaire. In the first category of the population, the one gathering the dentists, who have more experiences, we obtain 20% of awareness. In the second group, representing the students, who have less experience, we obtain 4% of awareness towards CCAP lesions. Over the whole sample population studied, we have obtained 91% of unawareness concerning calcified carotid artery plaque, present on the 2nd and 4th OPG of our questionnaire.

Discussion

In this study, we wanted to evaluate the awareness of the dental community of Cluj-Napoca regarding CCAP lesions on OPT. For this purpose, we used an online questionnaire distributed among a sample of our target population, followed by the statistical analysis and the graphics' illustration, using Microsoft Excel 2020. We presently showed that from the results we found, there is >50% of dental practitioner and dental students shared between the 6th and 5th year, who have failed to identify, or describe in any way the atherosclerosis lesion at the level of the CCA. This CCAP lesion were present on 2 panoramic radiographs out of 5 used in the questionnaire. The percentage obtained after our calculation is even larger than expected, reaching 91% of our sample population, which further confirms our initial hypothesis. We have noticed of course better results from the experimented groups, such as the dentists with specialty having 44% of awareness, but even though in this subcategory was more aware, the remaining 56% are also not aware of CCAP lesion on OPG and once again the result confirms our hypothesis. However, the results obtained might also have been subjected to various sources of errors, first we have created a questionnaire that was asking for subjective answers in order to increase the sincerity level of the subjects and to leave the possibility to describe the CCAP lesion, but as a consequence asking for the interpretation of the first pathological radioopacity that would appear to the eye of the subject could become too subjective and never incorrect. So, we did not indicate specifically what kind of lesion we were looking at.

For instance, it would have been possible to increase the degree of awareness among each individual by adding at the end of the questionnaire, an additional question asking to place the same 5 previous X-rays in an order of severity. Hence, the radiograph considered, by each of our subject, to represent the most severe case would place in the 1st position and the least severe case would be put in the last position. This way we could have insisted on the severity aspect of our study's subject and incite each individual to give at least one second attentive look at each one of the 5 panoramic radiographs of the questionnaire. Moreover, the access to our database of study, didn't provide the expected quality radiographs that one should obtain in dental clinics, that is to say with a balance intensity, without intense dark areas, which was mentioned by some of our subjects concerning the OPG from question n°1, or any blurry images or ghost shadows. Some ghost shadows were present, although they did not interfere with the appearance of

atherosclerotic lesions. A new aspect also important to mention, that would have eventually affected our results, is that a dentist have usually always the possibility to analyze thoroughly his panoramic radiographs taken in his office, by increasing or decreasing the intensities and voltages of his image, that allows the examiner to increase the brightness and the visibility of the image's darker regions, where the regions of the cervical spine and the bifurcation of the common carotid artery are often subjected. We might have run into some more complex situations with a doubt

concerning the differential diagnosis of other possible calcified anatomical structures present in the same region where CCAP occurs, which sometimes require the experimented eye of a maxilla-facial surgeon or radiologist (Roldán-Chicano *et al* 2006b). However, from the analyse of the short-written answers, we have never encountered the description of any anatomical structures included in the region where we could observe the CCAP lesions. We have reviewed previously in the general part of the study, that the differential diagnosis concerns for most of situations the calcified triticeous cartilage and less likely the superior horn of calcified thyroid cartilage (Carter 2000; Roldán-Chicano *et al* 2006b). In case of lack of experiences or confusions with a differential diagnosis, we can note that even with the general knowledge of CCAP

lesions, some errors could be still done by the dental partitioner. Moreover, it exists anatomical variations from one individual to another in the cervical area (Roldán-Chicano *et al.*, 2006b). It is also important to precise that the panoramic image is a two-dimensional projection of a three-dimensional object that can only give a preliminary estimate and in case of a suspected pathology, such as CCAP,

an additional study is required, usually a three-dimensional imaging examination, typically a Doppler Ultrasonography (Arthur H Friedlander & Friedlander, 1998). Unfortunately, from our statistical analysis and also according to the literature, we can understand that the CCAP lesions are not in the specific area which dental practitioners usually focus on (Kats *et al* 2018). An additional study confirms this neglect and describe CCAP lesion as being clearly visible on OPT but unfortunately is prone to be underexamined by dental practitioner (Kats *et al* 2018). As a result, the pathology remains undetected and some of these asymptomatic patients miss to be diagnosed at an early stage and act with adapted medical measures in order to prevent a cardiovascular event that is most likely to occur. However, knowledge and skills to detect CCAP on OPG among our dental community can be improved, if we act accordingly and take measures (Khambete *et al* 2014). We could manage to inform and educate a large amount of dental practitioner and hopefully reach soon enough a sufficient diagnostic level that would impact on the burden of stroke in Cluj-Napoca.

A first suggestion would be to sensibilize our dental community, especially through the education provided by the teachers at Faculty of Dentistry of Cluj-Napoca, thus reaching already the future generations of dentists. One should better understand that we have to act and adapt to any kind of situations in which we can fulfill our doctors' responsibilities. Even if it is not our main domain of work, it remains a detectable lesion that could appear on routine panoramic radiograph and might represent an important tool to prevent fatal cardio-vascular event. Beside

we can also suggest to distribute information charts to a great amount dental cabinets in Cluj-Napoca, illustrating the chain of preventive actions against strokes and the short description of the lesion with the possible differential diagnosis that could occur in this area. Recently a scientific study has tried to develop another kind of

solution in order also to contribute to a higher number of diagnostic levels, by the mean of routine panoramic radiographs (Kats et al 2018). The study concept was to create an algorithm that would be joined to panoramic x-rays, and by automatic detection analysis, the algorithm could diagnose atherosclerosis lesion if the dental practitioner would not see it, thus become a central help in the daily work of the dental practitioner as it would contribute to increase the chances of timely detection of atherosclerosis at the level of the bifurcation of the carotid artery and as a consequence increase the prevention against possible strokes.

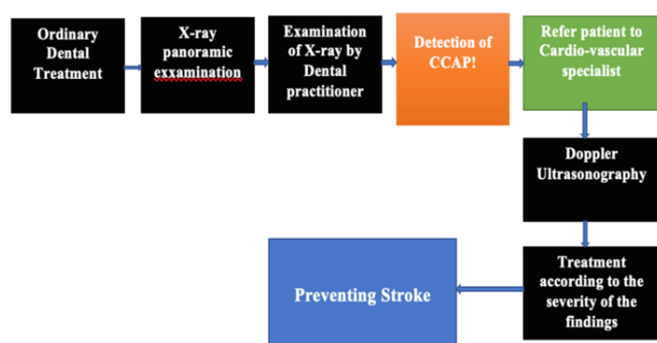


Figure 5 - Flow-chart preventive chain for stroke based on early detection of CCAP on OPG

Conclusion

Panoramic radiographs are an indispensable diagnostic tool routinely used in dental examinations. We have reviewed from the literature, that the same panoramic radiograph may present a distinctive pathological radio-opacity at the level of the CCA which indicate potentially an imminent stroke attack. In addition, we have also reviewed that an early detection of atherosclerotic lesion may have a key-role in the diminution of the burden of stroke in the world. As a consequence, panoramic radiographs within its limitations contribute effectively to the early diagnosis of atherosclerosis, with no additional cost to either public or private health systems. We have demonstrated that from a sample population in Cluj-Napoca, 90.7% of dental students in the 5th and 6th year as well as graduated dentists, were unaware to the calcified lesions present at the level of the CCA on a panoramic radiograph, therefore 90.7% would have been unable to refer their patients to a medical specialist for further medical tests and treatment, failing to their professional responsibility. We come to the conclusion that it is of utmost importance to increase the awareness of our dental community and remind us that we must provide a medical act not only as a dental practitioner but also as a health care provider able to take into account all clinical findings and communicate them within the shortest time to a specialist, thus fulfilling one's ought in the precious chain of our medical community.

References

- Akkemik O, Kazaz H, Tamsel S, Dündar N, Sahinalp S & Ellidokuz H. A 5 years follow-up for ischemic cardiac outcomes in patients with carotid artery calcification on panoramic radiographs confirmed by doppler ultrasonography in Turkish population. *Dento Maxillo Facial Radiology* 2020;49(4). <https://doi.org/10.1259/dmfr.20190440>
- Almog DM, Illi KA, Carter LC, Friedlander AH, Brooks S & Grimes RM. Diagnosis of non-dental conditions. Carotid artery calcifications on panoramic radiographs identify patients at risk for stroke. *The New York State Dental Journal* 2004;70(8):20–25.
- Alves N, Deana NF & Garay I. Detection of common carotid artery calcifications on panoramic radiographs: prevalence and reliability. *International Journal of Clinical and Experimental Medicine* 2014;7(8):1931–1939.
- Arai H. Oxidative modification of lipoproteins. *Sub-Cellular Biochemistry* 2014;77(1):103–114. https://doi.org/10.1007/978-94-007-7920-4_9.
- Badshah M, Soames R, Ibrahim M, Khan MJ & Khan A. Surface anatomy of major anatomical landmarks of the neck in an adult population: A Ct Evaluation of Vertebral Level. *Clinical Anatomy* 2017 (New York, N.Y.);30(6):781–787. <https://doi.org/10.1002/ca.22907>
- Bayer, S., Helfgen, E.-H., Börs, C., Kraus, D., Enkling, N., & Mues, S. (2011). Prevalence of findings compatible with carotid artery calcifications on dental panoramic radiographs. *Clinical Oral Investigations*, 15(4), :563–569. <https://doi.org/10.1007/s00784-010-0418-6>
- Beckstrom BW, Horsley SH, Scheetz JP, Khan Z, Silveira AM, Clark SJ, Greenwell H & Farman A. G. Correlation between carotid area calcifications and periodontitis: a retrospective study of digital panoramic radiographic findings in pretreatment cancer patients. *Oral Surgery, Oral Medicine, Oral Pathology, Oral Radiology, and Endodontics* 2007;103(3):359–366. <https://doi.org/10.1016/j.tripleo.2006.08.016>
- Bengtsson VW, Persson GR, Berglund J & Renvert S. A cross-sectional study of the associations between periodontitis and carotid arterial calcifications in an elderly population. *Acta Odontologica Scandinavica* 2016;74(2):115–120. <https://doi.org/10.3109/00016357.2015.1050603>
- Bengtsson VW, Persson GR & Renvert S. Assessment of carotid calcifications on panoramic radiographs in relation to other used methods and relationship to periodontitis and stroke: a literature review. *Acta Odontologica Scandinavica* 2014;72(6):401–412. <https://doi.org/10.3109/00016357.2013.847489>
- Brand HS, Mekenkamp WCG & Baart JA. Prevalence of carotid artery calcification on panoramic radiographs. *Nederlands tijdschrift voor tandheelkunde* 2009;116(2):69–73.
- Carrizales-Sepúlveda EF, Ordaz-Farías A, Vera-Pineda R & Flores-Ramírez R. Periodontal Disease, Systemic Inflammation and the Risk of Cardiovascular Disease. *Heart, Lung & Circulation* 2018; 27(11):1327–1334. <https://doi.org/10.1016/j.hlc.2018.05.102>
- Carter LC. Discrimination between calcified triticeous cartilage and calcified carotid atheroma on panoramic radiography. *Oral Surgery, Oral Medicine, Oral Pathology, Oral Radiology, and Endodontics* 2000;90(1):108–110. <https://doi.org/10.1067/moe.2000.106297>
- Choi H, Dey AK, Priyamvara A, Aksentijevich M, Bandyopadhyay D, Dey D, Dani S, Guha A, Nambiar P, Nasir K, Jneid H, Mehta NN, Lavie CJ & Amar S. Role of Periodontal Infection, Inflammation and Immunity in Atherosclerosis. *Current Problems in Cardiology* 2021;46(3):100638. <https://doi.org/10.1016/j.cpcardiol.2020.100638>
- Desvarieux M, Demmer RT, Jacobs DR, Papapanou PN, Sacco RL & Rundek T. Changes in clinical and microbiological periodontal profiles relate to progression of carotid intima-media thickness: the Oral Infections and Vascular Disease Epidemiology study. *Journal of the American Heart Association* 2013;2(6):1–10. <https://doi.org/10.1161/JAHA.113.000254>

- Dumitrescu AL. Influence of periodontal disease on cardiovascular diseases. *Romanian Journal of Internal Medicine = Revue Roumaine de Medecine Interne* 2005;43(1-2):9-21.
- Friedlander AH & Friedlander IK. Identification of stroke prone patients by panoramic radiography Arthur. *Australian Dental Journal* 1998;32(1):51-54.
- Friedlander AH, Aghazadehsanai N, Chang TI, Harada N, & Garrett NR. Prevalence of calcified carotid artery atheromas on panoramic images of individuals with primary hyperparathyroidism. *Dento Maxillo Facial Radiology* 2013;42(8):20130118. <https://doi.org/10.1259/dmfr.20130118>
- Friedlander AH, El Saden SM, Hazboun RC, Chang TI, Wong WK & Garrett NR. Detection of carotid artery calcification on the panoramic images of post-menopausal females is significantly associated with severe abdominal aortic calcification: a risk indicator of future adverse vascular events. *Dento Maxillo Facial Radiology* 2015;44(7):20150094. <https://doi.org/10.1259/dmfr.20150094>
- Friedlander AH & Friedlander IK. Identification of stroke prone patients by panoramic radiography. *Australian Dental Journal* 1998;43(1):51-54. <https://doi.org/https://doi.org/10.1111/j.1834-7819.1998.tb00153.x>
- Friedlander AH & Scully C. Diagonal ear lobe crease and atherosclerosis: a review of the medical literature and oral and maxillofacial implications. *Journal of Oral and Maxillofacial Surgery: Official Journal of the American Association of Oral and Maxillofacial Surgeons* 2010;68(12):3043-3050. <https://doi.org/10.1016/j.joms.2010.07.009>
- Guerreiro da Silva Jr N, Pedreira EN, Tuji FM, Warmling LV & Ortega KL. Prevalence of calcified carotid artery atheromas in panoramic radiographs of HIV-positive patients undergoing antiretroviral treatment: a retrospective study. *Oral Surgery, Oral Medicine, Oral Pathology and Oral Radiology* 2014;117(1):67-74. <https://doi.org/10.1016/j.oooo.2013.08.022>
- Hallikainen D. History of panoramic radiography. *Acta Radiologica* 1996;37(3 Pt 2):441-445. <https://doi.org/10.1177/02841851960373P207>
- Hirschmann PN. The current status of panoramic radiography. *International Dental Journal* 1987;37(1):31-37.
- Ioacara S, Tiu C, Panea C, Nicolae H, Sava E, Martin S & Fica S. Stroke Mortality Rates and Trends in Romania, 1994-2017. *Journal of Stroke and Cerebrovascular Diseases: The Official Journal of National Stroke Association* 2019;28(12):104431. <https://doi.org/10.1016/j.jstrokecerebrovasdis.2019.104431>
- Ishizaka N, Ishizaka Y, Toda EI, Hashimoto H, Nagai R & Yamakado M. Hypertension is the most common component of metabolic syndrome and the greatest contributor to carotid arteriosclerosis in apparently healthy Japanese individuals. *Hypertension Research: Official Journal of the Japanese Society of Hypertension* 2005;28(1):27-34. <https://doi.org/10.1291/hypres.28.27>
- Kats L, Vered M, Zlotogorski-Hurvitz A, Harpaz I. Atherosclerotic carotid plaque on panoramic radiographs: neural network detection. *Int J Comput Dent* 2019;22(2):163-169. PMID: 31134222.
- Kebschull M, Demmer RT, & Papapanou PN. "Gum bug, leave my heart alone!"-epidemiologic and mechanistic evidence linking periodontal infections and atherosclerosis. *Journal of Dental Research* 2010;89(9):879-902. <https://doi.org/10.1177/0022034510375281>
- Khambete N, Kumar R, Risbud M & Joshi A. Reliability of digital panoramic radiographs in detecting calcified carotid artery atheromatous plaques: a clinical study. *Indian Journal of Dental Research: Official Publication of Indian Society for Dental Research* 2014;25(1):36-40. <https://doi.org/10.4103/0970-9290.131052>
- Kuriakose D Xiao Z. Pathophysiology and treatment of stroke: Present status and future perspectives. *International Journal of Molecular Sciences* 2020;21(20):1-24. <https://doi.org/10.3390/ijms21207609>
- Kurkuoglu A, Pelin C, Oktem H & Aytekin C. Localization of the Carotid Bifurcation According to Hyoid Bone and Mandibular Angle. *International Journal of Morphology* 2017;35(3):901-906. <https://doi.org/10.4067/s0717-95022017000300017>
- Lindsay MP, Norrving B, Sacco RL, Brainin M, Hacke W, Martins S, Pandian J & Feigin V. World Stroke Organization (WSO): Global Stroke Fact Sheet 2019. *International Journal of Stroke* 2019;14(8):806-817. <https://doi.org/10.1177/1747493019881353>
- Mukherjee D, & Patil CG. Epidemiology and the global burden of stroke. *World Neurosurgery* 2011;76(6 Suppl): S85-90. <https://doi.org/10.1016/j.wneu.2011.07.023>
- Nasseh I & Aoun G. Carotid Artery Calcification: A Digital Panoramic-Based Study. *Diseases (Basel, Switzerland)* 2018;6(1). <https://doi.org/10.3390/diseases6010015>
- Persson RE, Hollender LG, Powell VL, MacEntee M, Wyatt CCL, Kiyak HA & Persson GR. Assessment of periodontal conditions and systemic disease in older subjects. II. Focus on cardiovascular diseases. *Journal of Clinical Periodontology* 2002;29(9):803-810. <https://doi.org/10.1034/j.1600-051x.2002.290903.x>
- Pomprasertsuk-Damrongsri S, Virayavanich W, Thanakun S, Siriwongpairat P, Amaekchok P & Khovidhunkit W. The prevalence of carotid artery calcifications detected on panoramic radiographs in patients with metabolic syndrome. *Oral Surgery, Oral Medicine, Oral Pathology, Oral Radiology, and Endodontics* 2009;108(4):e57-62. <https://doi.org/10.1016/j.tripleo.2009.05.021>
- Qaja E & Theetha Kariyanna P. Carotid Artery Surgery. 2021;9(14):1208.
- Ramesh A & Pabla T. Panoramic radiographs: a screening tool for calcified carotid atheromatous plaque. *Journal of the Massachusetts Dental Society* 2007;56(2):20-21.
- Ramesh A, Soroushian S & Ganguly R. Coincidence of calcified carotid atheromatous plaque, osteoporosis, and periodontal bone loss in dental panoramic radiographs. *Imaging Science in Dentistry* 2013;43(4):235-243. <https://doi.org/10.5624/isd.2013.43.4.235>
- Roldán-Chicano R, Oñate-Sánchez RE, López-Castaño F, Cabrerizo-Merino MC & Martínez-López F. Panoramic radiograph as a method for detecting calcified atheroma plaques. *Review of literature. Medicina Oral, Patología Oral y Cirugía Bucal* 2006a;11(3):261-266.
- Roldán-Chicano R, Oñate-Sánchez RE, López-Castaño F, Cabrerizo-Merino MC & Martínez-López F. Panoramic radiograph as a method for detecting calcified atheroma plaques. *Review of literature. Medicina Oral, Patología Oral y Cirugía Bucal* 2006b;11(3):E261-6.
- Rushon VE & Horner K. The use of panoramic radiology in dental practice. *Journal of Dentistry* 1996;24(3):185-201. [https://doi.org/10.1016/0300-5712\(95\)00055-0](https://doi.org/10.1016/0300-5712(95)00055-0)
- Ruttimann UE, Groenhuis RA & Webber RL. Restoration of digital multiplane tomosynthesis by a constrained iteration method. *IEEE Transactions on Medical Imaging* 1984;3(3):141-148. <https://doi.org/10.1109/TMI.1984.4307670>
- Takle A, Maru S, Karagir A, Ghodake D, Mujawar N & Takle A. Principles of panoramic radiography (orthopantography) 2015;16(October):628-633.
- Tonetti MS & Van Dyke TE. Periodontitis and atherosclerotic cardiovascular disease: Consensus report of the Joint EFP/AAP Workshop on Periodontitis and Systemic Diseases. *Journal of Clinical Periodontology* 2013;40(SUPPL. 14):24-29. <https://doi.org/10.1111/jcpe.12089>

Wahlgren N, Moreira T, Michel P, Steiner T, Jansen O, Cognard C, et al. Mechanical thrombectomy in acute ischemic stroke: Consensus statement by ESO-Karolinska Stroke Update 2014/2015, supported by ESO, ESMINT, ESNR and EAN. *International Journal of Stroke: Official Journal of the International Stroke Society* 2016;11(1):134–147. <https://doi.org/10.1177/1747493015609778>

Authors

- Anida-Maria Băbțan, IIIrd Department – Oral Rehabilitation, Faculty of Dentistry, “Iuliu Hațieganu” University of Medicine and Pharmacy, 8 Victor Babes Street, Cluj-Napoca, Romania, email: anidamaria.babtan@gmail.com
- Claudia N. Feurdean, IIIrd Department – Oral Rehabilitation, Faculty of Dentistry, “Iuliu Hațieganu” University of Medicine and Pharmacy, 8 Victor Babes Street, Cluj-Napoca, Romania, email: cbaitoru@yahoo.com
- Anca Ionel, IIIrd Department – Oral Rehabilitation, Faculty of Dentistry, “Iuliu Hațieganu” University of Medicine and

Pharmacy, 8 Victor Babes Street, Cluj-Napoca, Romania, email: anca_ionel@yahoo.com

- Willi A. Uriciuc, IIIrd Department – Oral Rehabilitation, Faculty of Dentistry, “Iuliu Hațieganu” University of Medicine and Pharmacy, 8 Victor Babes Street, Cluj-Napoca, Romania, email: willi.uriciuc@umfcluj.ro
- Radu Chifor, IIIrd Department – Oral Rehabilitation, Faculty of Dentistry, “Iuliu Hațieganu” University of Medicine and Pharmacy, 8 Victor Babes Street, Cluj-Napoca, Romania, email: chiforradu@gmail.com
- Charles-Edouard Bizzari, Graduated student of Faculty of Dentistry, “Iuliu Hațieganu” University of Medicine and Pharmacy, 8 Victor Babes Street Cluj-Napoca, Romania, email: ch.bizzari@gmail.com
- Aranka Ilea, IIIrd Department – Oral Rehabilitation, Faculty of Dentistry, “Iuliu Hațieganu” University of Medicine and Pharmacy, 8 Victor Babes Street, Cluj-Napoca, Romania, email: arankailea@yahoo.com

Citation Băbțan AM, Feurdean CN, Ionel A, Uriciuc WA, Chifor R, Bizzari CE, Ilea A. Importance of early diagnosis of atherosclerosis at the level of carotid artery on routine OPT. *HVM Bioflux* 2024;16(1):27-34.

Editor Antonia Macarie

Received 25 June 2024

Accepted 12 December 2024

Published Online 29 December 2024

Funding None reported.

**Conflicts/
Competing
Interests** None reported.