

Spontaneous heterotopic pregnancy with live birth – a case report, clinical and ultrasonographical aspects

¹Mihaela Oancea, ¹Cezarin Todea, ²Mihaela Muresan, ¹Razvan Ciortea, ¹Doru Diclescu, ¹Alexandra A. Poienar, ³Mihaela Grigore, ¹Dan Mihu

¹ Second Department of Obstetrics and Gynaecology, “Iuliu Hatieganu” University of Medicine and Pharmacy, Cluj-Napoca, Romania; ² Department of Pathology, County Emergency Hospital Cluj-Napoca, Romania; ³ Department of Obstetrics and Gynaecology, “Grigore T. Popa” University of Medicine and Pharmacy, Iasi, Romania.

Abstract. Heterotopic pregnancy represents the coexistence of an intrauterine and an ectopic pregnancy. It is a rare pathology and it usually is a consequence of medical assisted reproduction. We present the rare case of a heterotopic pregnancy after spontaneous conception with normal intrauterine pregnancy and live birth at term.

Key Words: pregnancy, heterotopic, diagnosis, conception

Copyright: This is an open-access article distributed under the terms of the Creative Commons Attribution License, which permits unrestricted use, distribution, and reproduction in any medium, provided the original author and source are credited.

Corresponding Author: A. A. Poienar, email: Alexandra.poienar@umfcluj.ro

Introduction

Heterotopic pregnancy is a rare pathology, in which an intrauterine and an extrauterine pregnancy coexist. It can be a life-threatening condition (Hassani 2010). The incidence is approximately 1 in 30000 spontaneous pregnancies (Lee 2016). The incidence in cases of medical assisted reproduction is 1-3 in 100 pregnancies (Levine 2007). The incidence has increased in recent years as a consequence of the more frequent use of medical assisted reproduction techniques (Li 2016). The risk factors for heterotopic pregnancy are the same as those for ectopic pregnancy (Rasuli 2020). A history of pelvic inflammatory disease, prior tubal and pelvic surgery, as well as tubal damage can increase the incidence of heterotopic pregnancy (Karkee 2019). Heterotopic pregnancy presents with no specific symptoms, thus early diagnosis is difficult. The symptoms are similar to those of ectopic pregnancy, adnexal torsion or cyst and tubo-ovarian abscess; therefore, every fertile patient presenting with amenorrhea, acute lower abdominal pain, peritoneal irritation or signs of hypovolemic shock should be suspected of ruptured ectopic or heterotopic pregnancy (Li-Ping 2018). The differential diagnosis can be made with a bicornuate uterus with gestation in both cavities, or intra-uterine gestation with hemorrhagic corpus luteum (Stanic 2020).

Case report

Patient ETM, age 31, presented in the emergency department of our hospital with acute abdominal pain, mild vaginal bleeding and 8 weeks of amenorrhea. She had a medical history of repeated pneumothorax.

The clinical exam revealed tenderness in the lower abdomen, of higher intensity in the left iliac fossa. The vaginal exam revealed mild bleeding with fresh blood, tenderness in the left vaginal sack and enlarged uterus. Rectal exam revealed tenderness.

The ultrasonographic exam showed a normal intrauterine pregnancy, with a normal embryo, a crown-lump length (LCC) of 4 mm (Fig. 1) and a fetal heart rate (FHR) of 157 b/min (Fig. 2), without any signs of hematoma.

On the left side of the uterus the ultrasonography revealed the left ovary with the corpus luteum and a lateral-uterine mass of 43.5/ 38.4 mm, with inhomogeneous content resembling an embryo (Fig 3). A Pulse Wave Doppler exam revealed a positive embryonic cardiac activity. The Douglas sack had a fine hypoechoic line interpreted as normal liquid.

Regarding the patient history, the anaesthesiology team recommended an open surgical approach and spinal anesthesia. We performed a Pfannensteil laparotomy that revealed the normal pregnant uterus, a dilated left fallopian tube, a yellow body located on the left ovary and a small amount of blood intraabdominally. We performed a left salpingectomy. The fallopian tube was sent to the pathology department for histopathological examination.

The patient had a good postoperative recovery. She was administered 200 mg of progesterone intravaginally as supportive therapy for the intrauterine pregnancy. Dismissal was in the third day. The macroscopic evaluation was performed after fixation in 10% Formaldehyde. The investigated tissue consisted of fallopian wall with intraluminal haematic material.

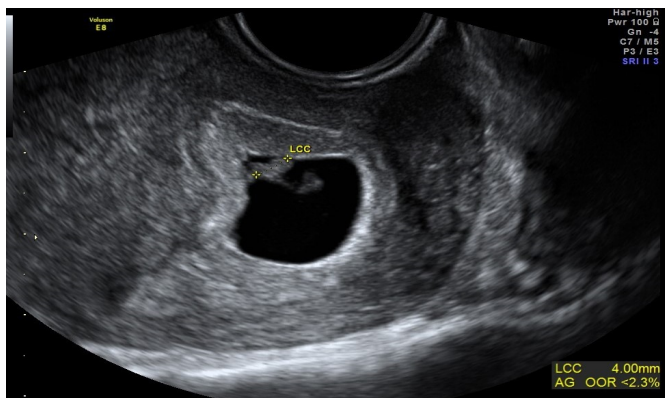


Fig. 1. Intrauterine embryo with LCC of 4 mm

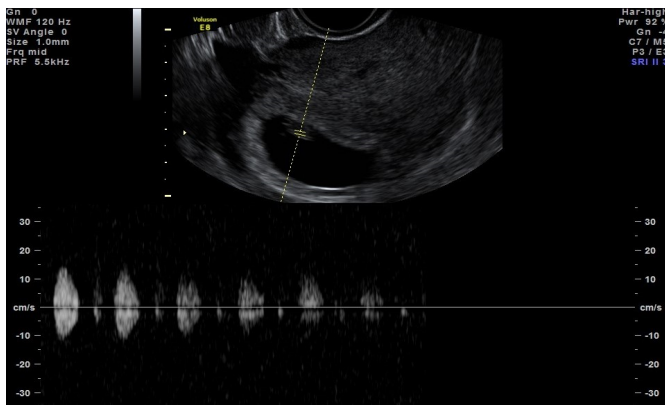


Fig. 2. FHR of intrauterine embryo

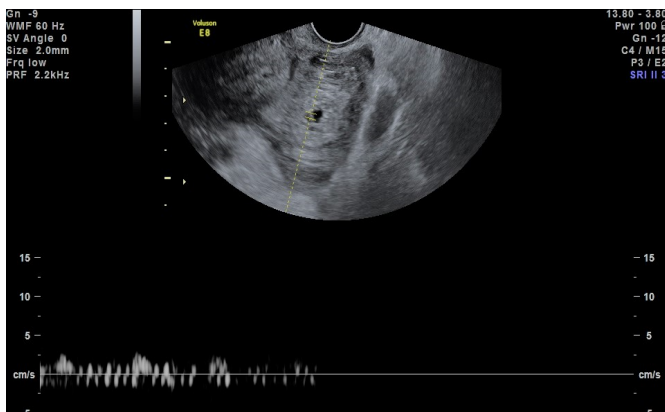


Fig. 3. Latero-uterine masse with embryo with FHR present

Multiple paraffin segments were examined after Hematoxylin-Eosin coloration. The pathology department used a Leica DMC 2900 microscope.

The pathology report confirmed the existence of an ectopic pregnancy through the presence of chorionic structures and decidualisation (Fig 4,5).

After the surgery, the patient had a normal pregnancy follow-up. She delivered by caesarean section at 39 weeks and 4 days a healthy boy with a birth weight of 3450g and an APGAR score of 10.

Discussions

Heterotopic pregnancy is difficult to diagnose before 9 weeks of gestation (Wang 2014). The gold standard in diagnosis is represented by transvaginal ultrasonography which identifies

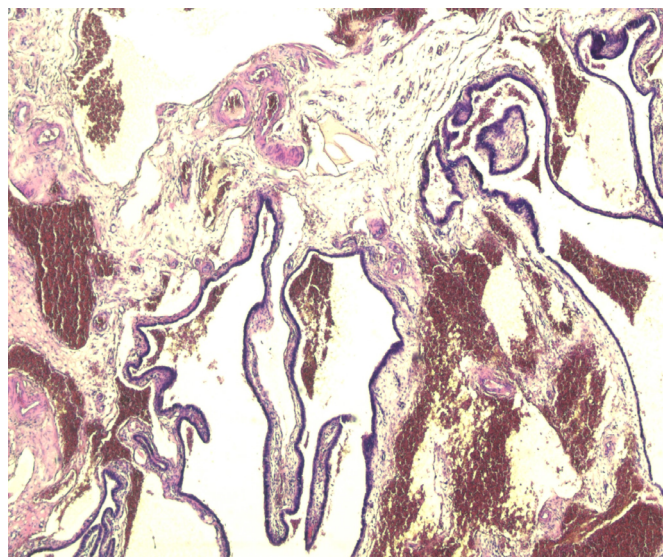


Fig. 4. Coloration HE, 40X: fallopian wall with oedema, stasis, and areas of haemorrhage

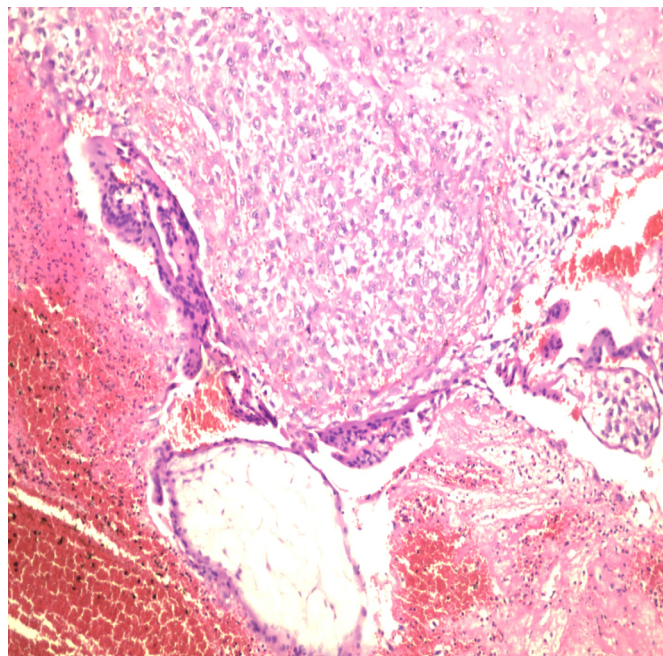


Fig 5: Coloration HE, 100 X: areas of decidualisation and necrosis next to a chorion villi

an intrauterine pregnancy as well as the characteristic lateral-uterine mass with a gestational sac (Petrides 2015).

Human chorionic gonadotropin levels are difficult to interpret because of the intrauterine pregnancy that can increase them accordingly (Stanic 2020).

Management of the ectopic pregnancy can be conservative or non-conservative. The in-situ injection of potassium chloride or methotrexate can be used, but the literature describes cases of infection, internal haemorrhage or fetal toxicity for the intra-uterine pregnancy when following this approach (Li 2016). Potassium chloride or a hyperosmolar solution can be considered in the event of unusual extrauterine locations that would be challenging for a surgical approach (e.g. at the cervix), or in the presence of caesarean scars (Talbot 2011).

There are no teratogenic effects known to occur secondary to the anesthesia medications (Ninke 2015).

Although many studies claim that the laparoscopic approach is the gold standard of surgical management, mainly because of minimal manipulation of the uterus, better operative field exposure and less postoperative pain (Guan 2017), there is no consensus regarding this aspect (Chadee 2016).

Conclusion

Heterotopic pregnancy is a condition that should be suspected in all fertile patients with amenorrhea and abdominal pain. Early management has a vital impact on the patient's life and the outcome of the intrauterine pregnancy. Patient consent was obtained for publication of this manuscript.

References

- Chadee A, Rezaei S, Kirby C, et al. Spontaneous Heterotopic Pregnancy: Dual Case Report and review of Literature. *Case Reo Obstet Gynecol* 2016;2145937.
- Guan Y & Ma C. Clinical outcomes of patients with heterotopic pregnancy after surgical treatment. *J Minim Invasive Gynecol* 2017;24(7):1111–1115.
- Hassani KIM, El Bouazzaoui A, Khatouf M, Mazaz K. Heterotopic pregnancy: A Diagnosis we should suspect more often. *J Emerg Trauma Shock* 2010;3(3):304.
- Karkee R, Sharma A, Dangal B. Heterotopic pregnancy: a challenge in early diagnosis. *J Nepal Health Res Counc* 2019;17(44): 413-5.
- Lee JS, Cha HH, Han AR, Lee AG, Seong WJ. Heterotopic pregnancy after a single embryo transfer. *Obstet Gynecol Sci* 2016;59(4):316-318.
- Levine D. Ectopic pregnancy. *Radiology* 2007;245(2): 385-397.
- Li JB, Kong LZ, Yang JB, Niu G, Fan L, et al. Management of Heterotopic Pregnancy. Experience from 1 Tertiary Medical Center. *Medicine* 2016;95(5):e2570.
- Li-Ping H, Hui-Min Z, Jun-Bi G, Chao-Yue T, Ziao-Xiao H. Management and Outcome of Heterotopic Pregnancy. *Ann Clin Lab Res* 2018;6(1):228.
- Ninke T, Thoma-Jennerwein S, Blunk J, Annecke T. Anesthesia and pain management during pregnancy. *Anesthesist* 2015;64(5):347-356.
- Petrides A, Mahboob S, Sayegh S. Heterotopic pregnancy: A not so rare entity. *Ultra Med Bio* 2015;41:123-124.
- Rasuli B, Weerakkody Y. 2005-2020. Radiopedia.org. [Online]. Available at: <https://radiopaedia.org/articles/heterotopic-pregnancy>. [Accessed 14 09 2020].

Stanic Z, Roje D, Matic D. Spontaneous Heterotopic Pregnancy as an Uncommon Clinical Problem. *Z Geburtshilfe Neonatol* 2020;224(4):223-226.

Talbot K, Simpson R, Price N, Jackson SR. Heterotopic pregnancy. *J Obstet Gynaecol* 2011;31(1):7-12.

Wang LL, Chen X, Ye DS, et al. Misdiagnosis and delayed diagnosis for ectopic and heterotopic pregnancies after in vitro fertilization and embryo transfer. *J Huazhong Univ Sci Technolog Med Sci* 2014;34(1):103-107.

Authors

- Mihaela Oancea, Second Department of Obstetrics and Gynaecology, “Iuliu Hatieganu” University of Medicine and Pharmacy, Dominic Stanca Clinic, 57 21st of December 1989 Boulevard, Cluj-Napoca, Romania; email: mihaelaoancea321@yahoo.com
- Cezarin Todea, Second Department of Obstetrics and Gynaecology, “Iuliu Hatieganu” University of Medicine and Pharmacy, 57 21st of December 1989 Boulevard, Cluj-Napoca, Romania; email: cezarintodea@gmail.com
- Mihaela Muresan, Department of Pathology, County Emergency Hospital, 3-5 Clinicilor Street Cluj-Napoca, Romania; email: michi_muresan@yahoo.com
- Razvan Ciorte, Second Department of Obstetrics and Gynaecology, “Iuliu Hatieganu” University of Medicine and Pharmacy, 57 21st of December 1989 Boulevard, Cluj-Napoca, Romania; email: r_ciortea@yahoo.com
- Doru Diculescu, Second Department of Obstetrics and Gynaecology, “Iuliu Hatieganu” University of Medicine and Pharmacy, 57 21st of December 1989 Boulevard, Cluj-Napoca, Romania; email: ddiculescu@yahoo.com
- Alexandra A. Poienar, Second Department of Obstetrics and Gynaecology, “Iuliu Hatieganu” University of Medicine and Pharmacy, 57 21st of December 1989 Boulevard, Cluj-Napoca, Romania; email: alexandra.poienar@gmail.com
- Mihaela Grigore, Department of Obstetrics and Gynaecology, “Grigore T. Popa” University of Medicine and Pharmacy, Medis center, 7C Balti Street Iasi, Romania; email: mihaela.grigore@edr.ro
- Dan Mihiu, Second Department of Obstetrics and Gynaecology, “Iuliu Hatieganu” University of Medicine and Pharmacy, 57 21st of December 1989 Boulevard, Cluj-Napoca, Romania; email: dan.mihui@yahoo.com

Citation

Oancea M, Todea C, Muresan M, Ciorte R, Diculescu D, Poienar AA, Grigore M, Mihiu D. Laparoscopic surgical treatment for renal tumors. Spontaneous heterotopic pregnancy with live birth – a case report, clinical and ultrasonographical aspects. *HVM Bioflux* 2021;13(2):53-55.

Editor Antonia Macarie

Received 2 February 2021

Accepted 28 February 2021

Published Online 9 April 2021

Funding None reported

**Conflicts/
Competing
Interests** None reported