

# Rapidly progressive renal failure in a case of Immunoglobulin A nephropathy

**Roxana Popitean, Ina Kacso, Crina Rusu, Alina Potra, Dacian Tirinescu, Maria Ticala, Anca Coman, Diana Moldovan**

Department of Nephrology, University of Medicine and Pharmacy “Iuliu Hatieganu” Cluj-Napoca, Romania.

**Abstract.** Even though IgA nephropathy is considered to be one of the most common nephropathy in the developed world, its association with crescent formation and rapidly progressive renal failure is considered rare. Thus, in the current case report, we present the case of a noncompliant young male that initially presented with a mild nephritic syndrome due to a mesangial proliferative glomerulonephritis. What can be observed in the current case report is the unfavorable evolution of the glomerulonephritis in relation with the lack of compliance of the patient to the doctors' recommendations during the four years between the initial diagnosis of his IgA nephropathy and the diagnosis of chronic renal failure. This shows the importance of rapid correct management in patients with immunoglobulin A (IgA) nephropathy, with the current case getting to a point where the main therapeutic approach remaining was represented by chronic dialysis. This case report shows the importance of timely initiation of appropriate therapeutic strategy.

**Key Words:** rapid progressive glomerulonephritis, IgA nephropathy, hemodialysis, renal biopsy, nephrotic syndrome

**Copyright:** This is an open-access article distributed under the terms of the Creative Commons Attribution License, which permits unrestricted use, distribution, and reproduction in any medium, provided the original author and source are credited.

**Corresponding Author:** R. Popitean; e-mail: roxi\_sandu06@yahoo.com

## Introduction

Rapidly progressive glomerulonephritis is the cause of rapid loss of renal function. It is a rare syndrome, but has a high rate of associated renal failure and morbidity. Even though IgA nephropathy is considered to be one of the most common nephropathies in the developed world, the association with crescent formation and subsequent rapidly progressive renal failure is considered rare (Iftikhar et al 2019), its main pattern of evolution being a slow progression. Efforts have been made to determine clinical and histological features associated with an evolution to rapidly progressive glomerulonephritis.

The treatment of IgA nephropathy in any individual patient should be tailored to that patient's presentation, given the conflicting results of many studies of this disease. All patients should be given supportive therapy with renin-angiotensin system blockade and dietary sodium restriction. Tonsillectomy is appropriate only for patients with recurrent tonsillar infections. The association with rapidly progressive glomerulonephritis is important because the need of steroid with immunosuppressors use; although able to manage the rapidly progressive glomerulonephritis, its benefic effects can be counterbalanced by the side effects (Arimura et al 2016; Rauen et al 2015).

Thus, in the current case report we presented the case of a young male that initially presented with IgA nephropathy and further had a severe evolution eventually to chronic renal failure.

## Case presentation

A young man, aged 23, Caucasian, diagnosed with mesangial proliferative glomerulonephritis four years earlier, addresses

the Nephrology department for a specialized evaluation, accusing asthenia and fatigue.

At the time of the diagnosis, the patient had normal renal function, mild positive antinuclear antibodies 1/160, mild proteinuria of 1.5 g/24h and microscopic hematuria. The kidney biopsy revealed an IgA nephropathy with minimal mesangial proliferation and only IgA deposits in immunofluorescence. He did not appear for nephrological re-evaluation and did not perform para-clinical investigations in other services, despite the indications of the nephrologist who recommended the introduction into the treatment plan of angiotensin converting enzyme inhibitors (ACEI) and nephrological monitoring.

Two months before the presentation in our service, the young man complained of a headache with a sudden onset. After this, he was diagnosed with hypertension and initiated antihypertensive treatment with ACEI, a diuretic and a calcium channel blocker. The latest paraclinical investigations performed showed a slight decrease of renal function with a creatinine of 1.74 mg/dl, hematuria and nephrotic proteinuria, albuminuria values exceeding 6 g/24h.

From a clinical point of view, the young man was in a relatively good general condition, but had skin pallor and bilateral leg edema, mostly malleolar.

Renal ultrasound showed both kidneys having preserved size and thickness of the parenchyma.

The patient was hospitalized in our service in order to extend the specialized investigations that reveal an important aggravation of the renal insufficiency with serum creatinine values up to 7.1 mg/dl and serum urea levels over 300 mg/dl. Taking into

account the severity of renal failure, it was decided to insert a central venous catheter and perform emergency hemodialysis. He had an active urine sediment with hematuria, red blood cell casts and a severe nephrotic syndrome with proteinuria over 10 g/24h accompanied by low serum albumin of 2 g/dl.

Subsequently, the paraclinical assessment was completed by lung radiograph (without significant changes) and by immunological tests, of which ANA and the other autoantibodies assessed were negative. No criteria for systemic lupus erythematosus were present.

As an evaluation of possible chronic kidney disease complications, there was an imbalance in mineral metabolism represented by mild secondary hyperparathyroidism, hypocalcemia and hyperphosphatemia.

Considering the rapid progression of the disease and after assessing the risk / benefit ratio, we decided to perform a kidney biopsy hoping to identify for elements of reversibility. The morphopathological result revealed the presence of crescentic extracapillary proliferative glomerulonephritis with active and chronic lesions represented by fibro-cellular crescents.

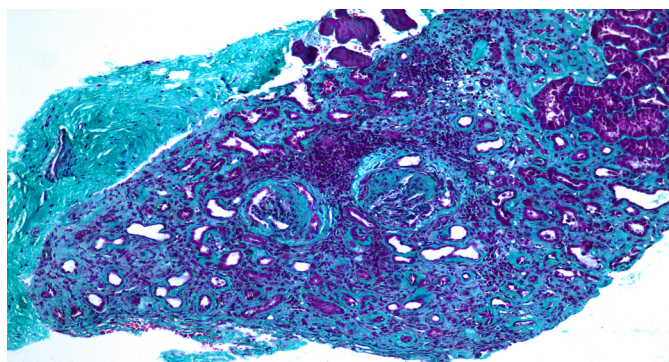


Figure 1. Optical microscopy - trichrome staining

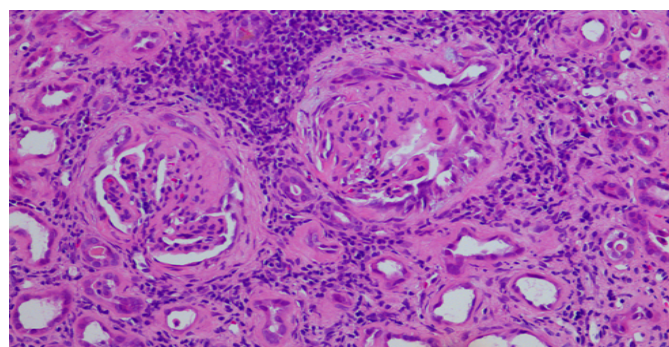


Figure 2. Optical microscopy - periodic acid-Schiff staining

The immunofluorescence test showed IgA, kappa and lambda light chains deposits.

The case was interpreted as an extracapillary proliferative glomerulonephritis with rapidly progressive evolution added to a background of chronic kidney disease.

The pathogenetic treatment is initiated using pulses of Methylprednisolone up to a total of 3 g, continued by Prednisone and Cyclophosphamide in adjusted body weight doses.

Hemodialysis was continued as needed.

After one month the patient was admitted for reevaluation. He displayed anxiety, depression, anemia and thrombocytopenia. The psychiatric consult raised the problem of adverse effects from the corticosteroid medication; renal failure persisted.

Considering the lack of effectiveness of the Prednisone and Cyclophosphamide regimen on the disease and the associated side effects (anemia and thrombocytopenia), the Cyclophosphamide is discontinued, and the Prednisone dose was tapered and then stopped. Currently, the patient performs chronic hemodialysis and his performance status, clinical and psychological status are very good. He is on the waiting list for a kidney transplant, and he is optimistic.

## Discussion

In the current case report, we presented the case of a young male that initially presented with IgA nephropathy and further developed chronic renal disease.

Rapidly progressive glomerulonephritis is a clinical and pathological syndrome; a term used to describe the following: a) rapid loss of renal function over a very short period (days to weeks); b) nephritic urine analysis: proteinuria, micro or macroscopic hematuria, dysmorphic red blood cells (RBC), RBC casts; c) histopathological characteristic on renal biopsy finding; cellular crescent formation in the glomeruli; which is proliferative cellular response seen outside the glomerular tuft within Bowman's capsule and because of its crescentic shape called crescentic glomerulonephritis (Moroni & Ponticelli 2014).

In IgA nephropathy, hematuria episodes that are preceded by upper respiratory infections, arterial hypertension and proteinuria and microhematuria of variable degrees can be the most characteristic clinical findings. Dominant or co-dominant mesangial deposits of IgA, with or without IgG and C3, are the typical findings in renal biopsy immunofluorescence (Barratt & Feehally 2005). Even though the IgA nephropathy is the most common primary glomerulonephritis in the Western world, this disorder is thought to follow a benign course in most cases. However, a number of patients are at risk for slow progression to end-stage kidney disease, which develops in approximately 15% of patients by 10 years and 20% by 20 years, though these percentages depend on how the disease is defined (Huang *et al* 2019). What can be observed in the current case report is represented by the lack of compliance of the patient to the doctors' recommendations during the four years between the initial diagnosis of IgA nephropathy and the subsequent diagnosis of renal failure. As the corticosteroid and cyclophosphamide determined severe psychiatric and hematological side effects in this patient, cyclophosphamide was discontinued and the prednisone dose reduced, that could worsen the patient prognosis (Warrington & Bostwick 2006; Weycker *et al* 2019). This shows the importance of rapid correct management in patients with IgA nephropathy, with the current case getting to a point where the main therapeutic approach remaining was represented by chronic dialysis. As it has been shown that these patients can benefit from ACEI more than any other anti-hypertensive medication (Praga *et al* 2003), it is possible that the current case could have benefited from a better prognosis. Also, the lack of monitoring led to the impossibility to capture the moment when the extracapillary proliferation with cellular crescents occurred, in order to be treated efficiently. Added to this, it has been shown that IgA nephropathy with crescentic glomerulonephritis can benefit from cyclophosphamide associated with prednisone (Tumlin *et al* 2003). Nonetheless, in our case presented here, it can be observed that this approach does not have good results when the

disease is too advanced and might actually induce certain side effects without any benefit.

## Conclusions

In the current case report, we presented a case report of a young male that initially present-ed with IgA nephropathy and further down the line developed end-stage renal failure. This case report shows the importance of timely initiation of appropriate therapeutic strategy and thorough nephrological monitoring.

## References

- Arimura Y, Muso E, Fujimoto S, Hasegawa M, Kaname S, Usui J, et al. Evidence-based clinical practice guidelines for rapidly progressive glomerulonephritis 2014. *Clinical and experimental nephrology* 2016;20(3):322–341. <https://doi.org/10.1007/s10157-015-1218-8>
- Barratt J, Feehally J. IgA nephropathy. *J Am Soc Nephrol* 2005; 16: 2088–2097.
- Iftikhar H, Saleem M, Kaji A. A Case Report of IgA Nephropathy Coexisting with Focal Segmental Glomerulosclerosis. *Cureus* 2019;11(6): e5040. <https://doi.org/10.7759/cureus.5040>
- Moroni G, Ponticelli C. Rapidly progressive crescentic glomerulonephritis: Early treatment is a must. *Autoimmun Rev*. 2014 Jul;13(7):723-9.
- Huang PP, Shu DH, Su Z, Luo SN, Xu FF, Lin F. Association between lifestyle, gender and risk for developing end-stage renal failure in IgA nephropathy: a case-control study within 10 years. *Renal Failure*. 2019;41:914–920.
- Praga M, Gutiérrez E, González E, Morales E, Hernández E. Treatment of IgA nephropathy with ACE inhibitors: A randomized and controlled trial. *Journal of the American Society of Nephrology: JASN* 2003;14(6):1578–1583. <https://doi.org/10.1097/01.asn.0000068460.37369.dc>
- Rauen T, Eitner F, Fitzner C, Sommerer C, Zeier M, Otte B, et al. Intensive Supportive Care plus Immunosuppression in IgA Nephropathy. *New England Journal of Medicine* 2015;373(23):2225–2236. <https://doi.org/10.1056/NEJMoa1415463>
- Tumlin JA, Lohavichan V, Hennigar R. Crescentic, proliferative IgA nephropathy: Clinical and histological response to methylprednisolone and intravenous cyclophosphamide. *Nephrology, Di-alysis, Transplantation: Official Publication of the European Dialysis and Transplant Association - European Renal Association* 2003;18(7):1321–1329.

Warrington TP, Bostwick JM. Psychiatric adverse effects of corticosteroids. *Mayo Clin Proc*. 2006 Oct;81(10):1361-7. doi: 10.4065/81.10.1361. PMID: 17036562.

Weycker D, Hatfield M, Grossman A. et al. Risk and consequences of chemotherapy-induced thrombocytopenia in US clinical practice. *BMC Cancer* 2019;19:151. <https://doi.org/10.1186/s12885-019-5354-5>

## Authors

- Roxana Popitean, Department of Nephrology, University of Medicine and Pharmacy “Iuliu Hatieganu” Cluj-Napoca, Romania, 3-5 Clinicilor street, 400006, Cluj-Napoca, Romania, E-mail: roxi\_sandu06@yahoo.com
- Ina Kacso, Department of Nephrology, University of Medicine and Pharmacy “Iuliu Hatieganu” Cluj-Napoca, Romania, 3-5 Clinicilor street, 400006, Cluj-Napoca, Romania, E-mail: ina-kacso@yahoo.com
- Crina Rusu, Department of Nephrology, University of Medicine and Pharmacy “Iuliu Hatieganu” Cluj-Napoca, Romania, 3-5 Clinicilor street, 400006, Cluj-Napoca, Romania, E-mail: crinaclau-diarusu@yahoo.ro
- Alina Potra, Department of Nephrology, University of Medicine and Pharmacy “Iuliu Hatieganu” Cluj-Napoca, Romania, 3-5 Clinicilor street, 400006, Cluj-Napoca, Romania, E-mail: alinalen@yahoo.com
- Tirinescu Dacian, Department of Nephrology, University of Medicine and Pharmacy “Iuliu Hatieganu” Cluj-Napoca, Romania, 3-5 Clinicilor street, 400006, Cluj-Napoca, Romania, E-mail: daci-an\_tirinescu@yahoo.com
- Maria Ticala, Department of Nephrology, University of Medicine and Pharmacy “Iuliu Hatieganu” Cluj-Napoca, Romania, 3-5 Clinicilor street, 400006, Cluj-Napoca, Romania, E-mail: dr.mariacosa@yahoo.com
- Anca Coman, Department of Nephrology, University of Medicine and Pharmacy “Iuliu Hatieganu” Cluj-Napoca, Romania, 3-5 Clinicilor street, 400006, Cluj-Napoca, Romania, E-mail: ancalaura-coman@yahoo.com
- Diana Moldovan, Department of Nephrology, University of Medicine and Pharmacy “Iuliu Hatieganu” Cluj-Napoca, Romania, 3-5 Clinicilor street, 400006, Cluj-Napoca, Romania, E-mail: dnmoldovan@yahoo.com

**Citation** Popitean R, Kacso I, Rusu C, Potra A, Tirinescu D, Ticala M, Coman A, Petra C, Botan E, Moldovan D. Rapidly progressive renal failure in a case of Immunoglobulin A nephropathy. *HVM Bioflux* 2021;13(4):138-140.

**Editor** Antonia Macarie

**Received** 11 September 2021

**Accepted** 15 October 2021

**Published Online** 1 November 2021

**Funding** None reported

**Conflicts/  
Competing  
Interests** None reported