

Body posture improvement after occlusal correction- a case report

¹Simona M. Iacob, ¹Andrea M. Chisnoiu, ¹Mirela I. Fluerasu, ¹Liana M. Lascu, ²Ioana Iacob, ³Radu Chisnoiu, ¹Laurentiu Pascu

¹Department of Prosthodontics “Iuliu Hațieganu” University of Medicine and Pharmacy, Cluj-Napoca, Romania; ²Faculty of General Medicine, “Iuliu Hațieganu” University of Medicine and Pharmacy, Cluj-Napoca, Romania; ³Department of Odontology, “Iuliu Hațieganu” University of Medicine and Pharmacy, Cluj-Napoca, Romania.

Abstract. Dental occlusal dysfunction can influence the temporomandibular joint (TMJ) and the orofacial muscles as well as the body's posture. This paper presents the clinical examination and therapeutic protocol of a 32-year-old patient with painful TMJ and throat syndrome. Materials and methods. The patient was examined clinically, evaluating the TMJ, oro-facial muscles, static and dynamic dental occlusion. Axiographic evaluation was also performed using CADIAX System, posture evaluation with the use of PostureScreen Mobile digital application and MRI of the TMJ. Results. The initial clinical evaluation revealed limited mouth opening and right lateral guidance, painful orofacial muscles (on pain scale from 2 to 5), presence of occlusal interferences. Axiography confirmed these findings. No pathological modifications of TMJ were observed on MRI. Body posture evaluation showed significant pathological modifications. The therapeutic protocol consisted in occlusal splint appliance and occlusal adjustments. The final evaluation after treatment showed pain disappearance, significant improvement of mandibular movements and body posture correction. Conclusion. A pathological dental occlusion creates a tonus imbalance in the masticatory muscles that triggers a series of compensatory mechanisms, modifying the tonus of the spinal muscles and therefore the posture. Minimum non-invasive treatments are often indicated in the initial stages for disabling symptoms elimination.

Key Words: body posture, dental occlusion, axiography, digital evaluation.

Copyright: This is an open-access article distributed under the terms of the Creative Commons Attribution License, which permits unrestricted use, distribution, and reproduction in any medium, provided the original author and source are credited.

Corresponding author: A. M. Chisnoiu, email: maria.chisnoiu@umfcluj.ro

Introduction

Dento-maxillo-facial disorders are no longer an exclusively dentist-centered concern. The influence of such disorders on other systems is obvious.

In recent years, the role of the dento-maxillary apparatus on the musculoskeletal system and implicitly on the posture is increasingly discussed in the literature. Dento-maxillary apparatus dysfunction is a general term that pertains to both the stomatognathic muscular system and the temporomandibular joint (TMJ). (Baldini et al 2015, Rocha et al 2017).

The stomatognathic system is a complex functional unit constituted of a bone structure (maxillary jaw and mandible), dental arches, soft tissue (salivary glands, vascularly-nervous structures), temporomandibular joint and masticatory muscles. All of these structures, acting together in harmony, allow, in addition to their role in posture, the realization of complex functions such as speech, mastication and swallowing. The temporomandibular joint through its muscular and ligamentous connections to the cervical region forms a functional complex called the « craniocervico-mandibular system ». At cerebral level, the stomatognathic system has a wide area of representation in both the motor and the sensory cortex (Nakahara et al 2004).

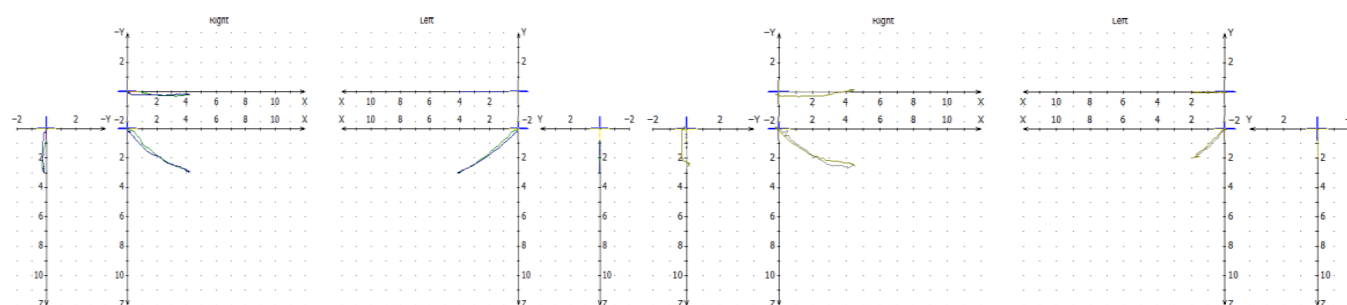
Posture represents the body's state of spatial equilibrium, which is maintained in both static and dynamic circumstances. It is controlled by the central nervous system that activates

the muscular system involved in the posture, helping the body adapt to gravity. According to the postural concept man is a complex adaptive dynamic system in permanent evolution and life-long development.

A normal posture is the result of the position of the eyes, ears, shoulders and hips being at the same level. The legs must be positioned forward, the sagittal plane crossing between them. From a frontal plane perspective, the vertical axis intersects the philtrum, the sternal fork and the pubic symphysis. Its descent continues between the knees and the legs.

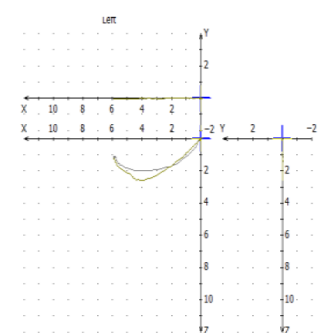
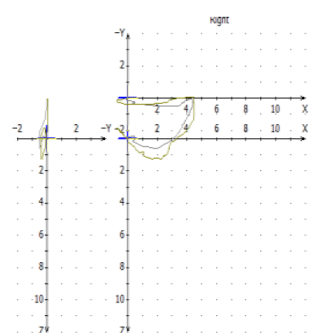
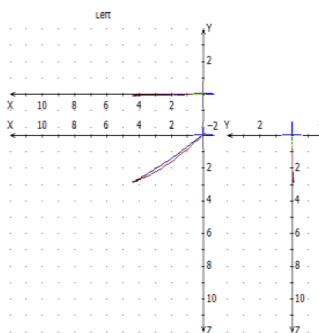
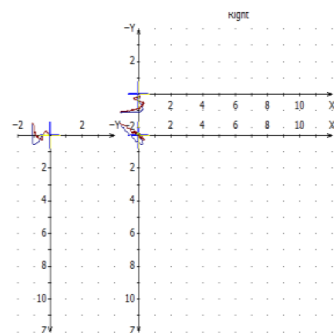
From a lateral plane perspective, the vertical axis intersects the tragus, the middle of the shoulder, the midline of the hip and the lateral malleolus of the ankle joint (Ivanenko et al 2018) A normal posture keeps the bones and joints in a correct position, which would otherwise lead to an overexertion of the muscles. This, together with the build-up of muscular tension, could be the main reason behind the etiology of neck and lower back pain syndrome. (Makofsky et al 2011, Silva et al 2009)

Postural adjustments are influenced by information received from the visual, vestibular and somatosensory receptors, which are integrated into a complex regulatory system (Ries et al 2008, Baldini et al 2017). Posture is controlled by the central nervous system that analyzes information sent from peripheral sensors (visual, vestibular and / or somatosensation: exteroceptive and proprioceptive). Thus the central nervous system automatically



Anterior guidance

Left lateral guidance



Right lateral guidance

Mouth opening - closure

Fig. 1. Initial axiographic records – 2016

adjusts posture, helping maintain the body’s ability to perform daily activities. Being a reflex activity, postural adjustment is improved through learning and exercise (Kandel et al 2012)

A scientific literature review by Chaves et al (2014) revealed a correlation between temporomandibular dysfunction (TMD) and cervical posture.

Furthermore, a recent study, carried out by Rocha et al (2017), showed no sign of postural changes in patients both with and without unilateral disc displacement. However, the authors selected patients with painful temporomandibular symptomatology which could lead to false positive results due to the need for postural adjustment to pain; therefore, postural change is an effect and not the cause of the symptoms (Manfredini et al 2012). Based on the results of the fore mentioned researches, we considered useful to present the clinical examination and therapeutic protocol of a 32-year-old patient with painful TMJ and throat syndrome.

Material and method

This paper presents the case of a 32-year-old patient who came to the dental office accusing spontaneous earache on the right side. She also described pain in the right latero-cervical area. On a scale from 0 to 10 (where 0 is the complete absence of pain and 10 is intense pain), the patient graded the ache as being a 4, partially subsiding after analgesic medication. The patient did not report any dental symptoms.

Due to earache and latero-cervical pain, the patient initially consulted an ENT specialist. The doctor couldn’t find any pathological changes and directed the patient to a dental office.

The clinical examination began with a short anamnesis and continued with the evaluation of the patient’s dento-maxillary apparatus while also requesting a panoramic dental X-ray. During the clinical examination, the patient was asked to open her mouth.

This revealed a slight limitation of the opening accompanied by chin deviation to the right.

A wider opening of the oral cavity caused the patient tenderness that she graded as a 3. TMJ palpation revealed an asymmetric condylar descent due to limiting of the right condylar path. Palpation also caused tenderness in the right TMJ area that the patient described as being a grade 2.

The orofacial masticatory and cervical muscles were also examined. A slight contraction of the right masseter muscle (both the superficial and deep portion), the right pterygoid (both the lateral and medial), right trapezius and right sternocleidomastoid was noticed. Palpation of these muscles revealed soreness of different degrees depending on the muscle: 2 - the pterygoid and superficial masseter; 3 - deep masseter and sternocleidomastoid; 5 - the trapezius. The examination of the left orofacial muscles had no pathological significance.

The odontal examination revealed the presence of numerous treated carious lesions, none of which, however, justifying the symptoms accused by the patient during the consult. Radiological examination dismissed the possibility of a pathological change that could explain the symptoms.

Teeth 1.5 and 4.6 were absent. The edentulous space caused by the absence of tooth 1.5 was reduced due to the mesial tipping of tooth 1.6 and was treated using a fixed partial prosthesis with 1.6 as pontic and 1.5 mesial cantilever. The edentulous space caused by the absence of tooth 4.6 was reduced by 4 mm due to the mesial tipping of both tooth 4.7 and 4.8. This resulted in a significant alteration of the plane of occlusion.

Static occlusion was within normal parameters. Subsequently, dynamic occlusion was examined.

The anterior guidance was functional, without any active interferences or premature contacts.

Passive interferences were however present: tooth 1.7’s disto-vestibular (DV) cusp with DV cusp of tooth 4.8 hindered the

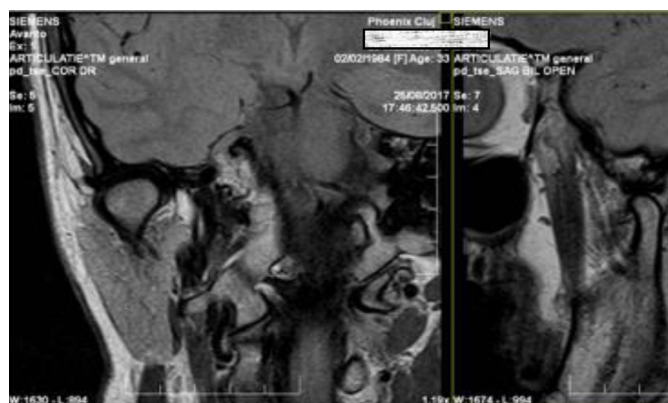
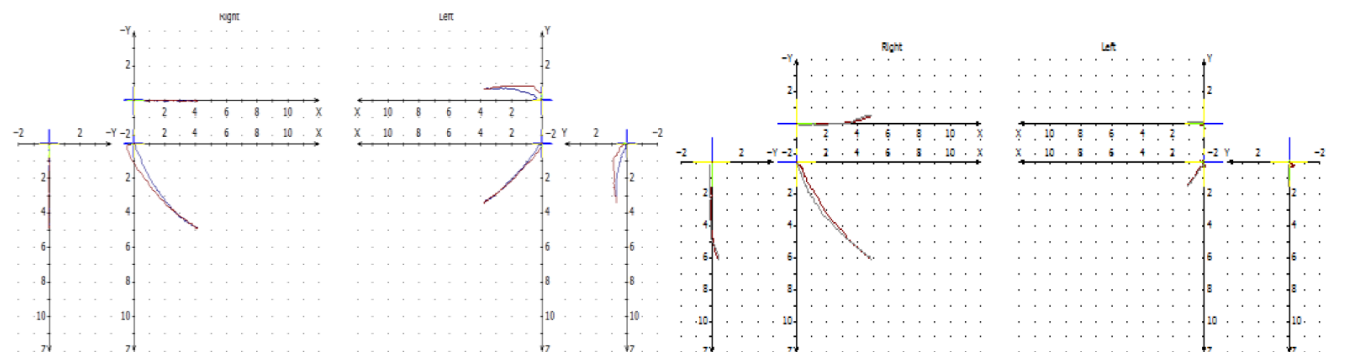


Fig. 2. MRI images of TMJ

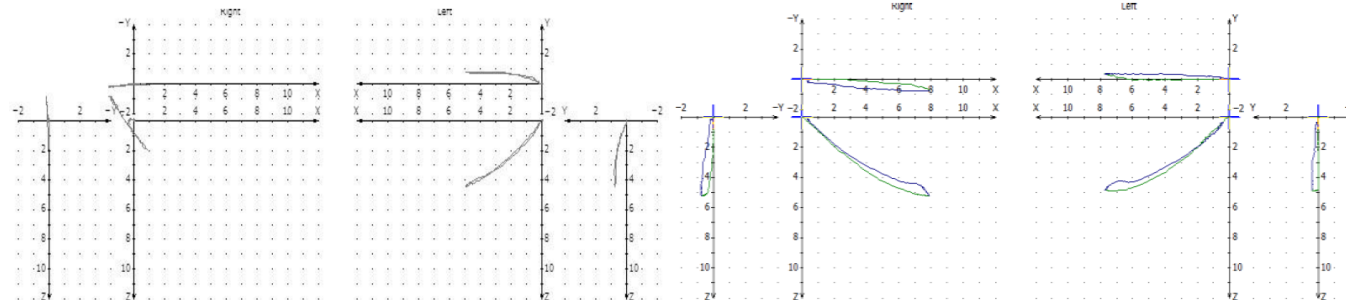
Table 1. Variables studied with the PostureScreen Mobile application

Frontal examination	Lateral examination
Head deviation (cm)	Estimated head weight (kg)
Angle of head deviation (degrees)	Calculated head weight (kg)
Shoulder deviation (cm)	Head deviation (cm)
Angle of shoulder deviation (degrees)	Shoulder deviation (cm)
Thoracic cage deviation (cm)	Hip deviation (cm)
Hip deviation (cm)	Knee deviation (cm)
Angle of hip deviation (degrees)	



Anterior guidance

Left lateral guidance



Right lateral guidance

Mouth opening - closure

Fig. 3. Axiographic records at the end of the occlusal treatment

propulsion. These same teeth also acted as premature contacts - the DV cuspid of tooth 1.7 in contact with the distal marginal ridge of tooth 4.8. This explained the sinusoid propulsive path that descended towards the left.

On the patient's right side, lateral guidance was based on a functional canine-guided occlusion, with the absence of both interferences and premature contacts. On the left side, however, the lateral anterior guidance was affected by the presence of passive interferences (DV cusp tooth 4.7 – distal marginal ridge tooth 1.6; DV cusp tooth 4.8- mesio-lingual cusp tooth 1.7) thus diverting the glide path.

Furthermore, during the examination, the patient described an intense pain (graded 7), which limited the movement during left lateral guidance.

To exemplify and elucidate what had been observed clinically, a computerized axiogram was performed, using a Cadiax diagnostic device. Axiography helps create a graphical representation of the condilar movements. By comparing these results to

standard condilar paths one can diagnose different clinical forms of temporomandibular pathology (muscular, reversible or irreversible discal displacement, osteoarthritis). Furthermore, axiography facilitates the early detection of meniscal pathologies and helps monitor the patient's evolution. (Popsor et al 2002, Piancino et al 2008)

In the present case, axiography revealed a limitation of the mouth opening on the right side with the consequent ipsilateral deviation of the menton. Anterior guidance was normal, the graphic paths (from maximum intercuspation to maximum propulsion and back) overlapping. Axiography of the left lateral guidance revealed a slight limitation whereas right lateral movement appeared to be severely limited (Figure1).

As an additional examination, a bilateral contrast-free MRI of the TMJ was indicated. The MRI revealed no significant meniscal changes in the anterior, posterior or intermediate bands. No meniscal dislocation was detected in either closed mouth or dynamic maneuvers during the MRI scan. The mobility of

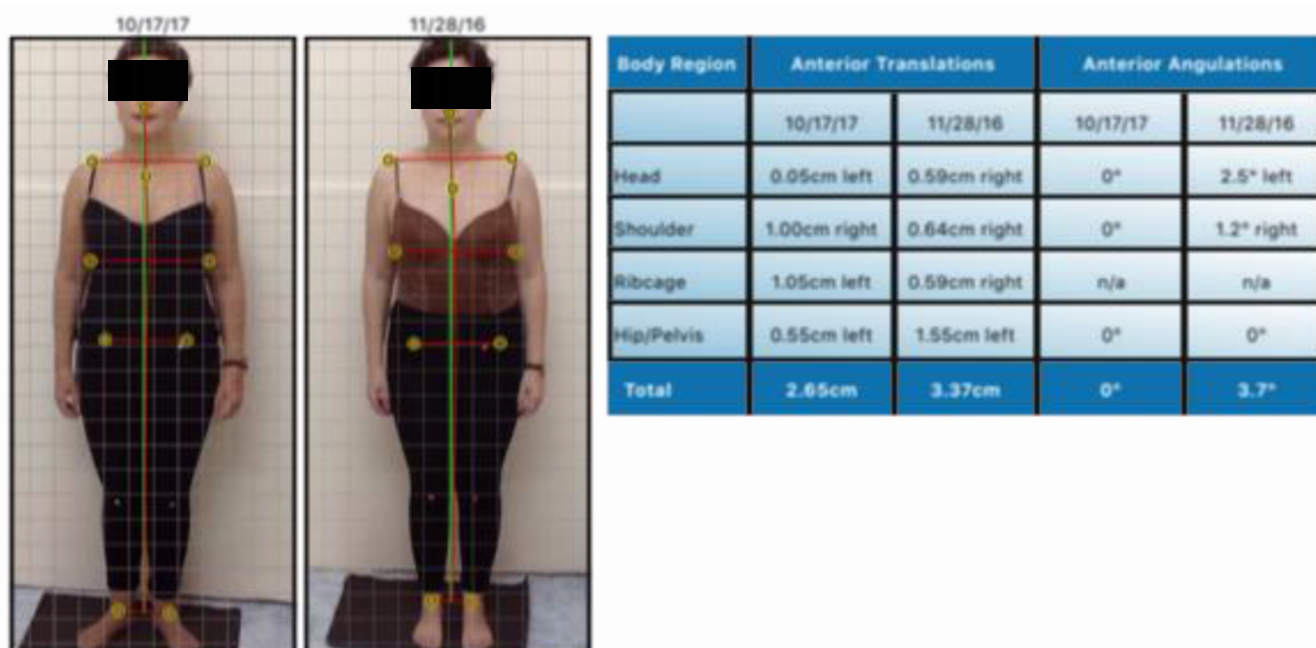


Fig. 4. Posture displacement between initial and final examination.-anterior view

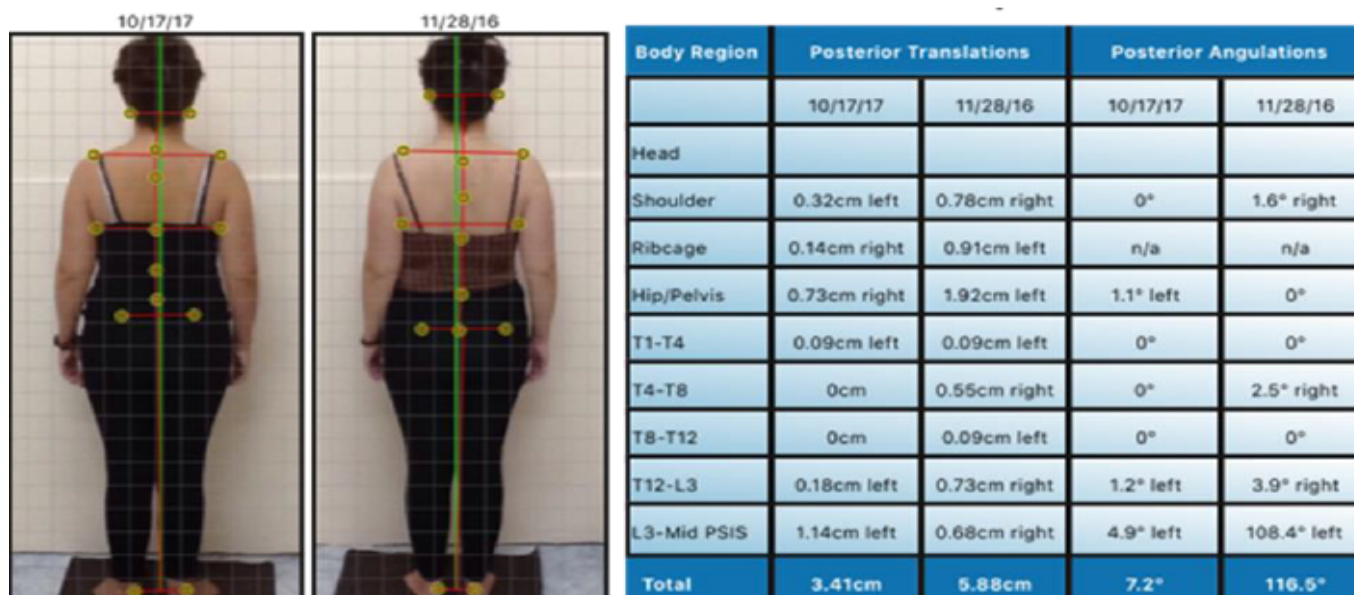


Figure 5. Posture displacements- posterior view.

the meniscus was preserved. The temporomandibular articular space was preserved, without any changes in bone structure and without intra-articular fluid collection (Figure2).

Subsequently, a photographic postural examination was performed using the PostureScreen Mobile app, installed on an IPAD 2. This application is in fact the digitalization of a validated posture evaluation method - the vertical photographic method using a vertical mark, also known as the lead wire method. This examination is simple, fast, and easily reproducible and does not require an in-depth knowledge of posturology. The markers were manually placed on each photo.

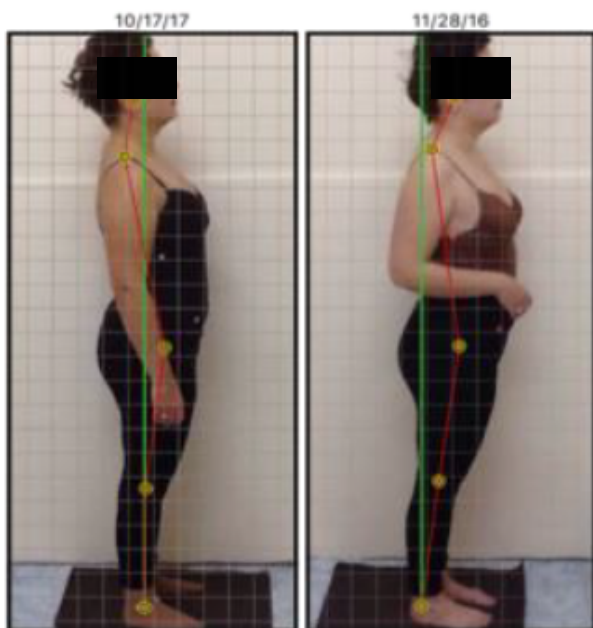
The measurements were then automatically made using the PostureScreen Mobile application. Several variables and their left/right deviations from the median line (for the frontal examination) and forward/backward from the vertical line (for

the lateral examination) were analyzed. The studied variables are listed in Table 1.

The therapeutic decision was to make a deconditioning maxillary splint (a permissive full coverage occlusal splint), based on the cast models mounted in centric relation in an A7 plus, semi-adjustable Bio-Art articulator. Once fabricated, the splint was applied to the patient's maxillary jaw. All interferences in maximum intercuspation and those identified during the mandible's functional movements were eliminated. The patient was advised to wear the splint at night and as frequent as possible during the day.

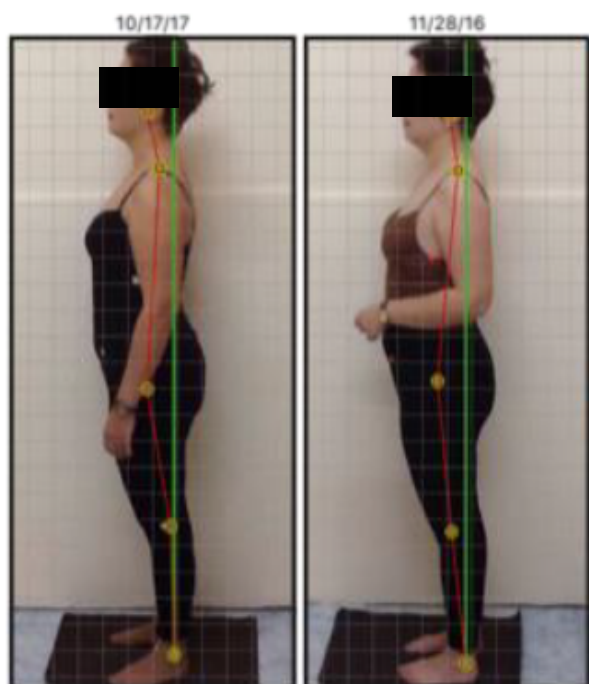
Results

The painful symptoms (both spontaneous and stimulated) resided after wearing the splint for two days. The patient also



Body Region	Lateral Translations		Lateral Angulations	
	10/17/17	11/28/16	10/17/17	11/28/16
Head	2.37cm anterior	6.47cm anterior	8.13° flexed	22.91° flexed
Shoulder	11.22cm posterior	7.66cm posterior	11.42° extended	7.62° extended
Hip/Pelvis	5.38cm anterior	5.74cm anterior	7.49° flexed	8.32° flexed
Knees	0.27cm anterior	4.74cm anterior	0°	7.43° flexed
Total	19.25cm	24.62cm	27.0°	-46.3°

Fig. 6. Right posture displacements.



Body Region	Lateral Translations		Lateral Angulations	
	10/17/17	11/28/16	10/17/17	11/28/16
Head	3.38cm anterior	2.19cm anterior	12.28° flexed	7.90° flexed
Shoulder	3.47cm posterior	5.75cm posterior	3.36° extended	5.83° extended
Hip/Pelvis	6.57cm anterior	4.01cm anterior	10.15° flexed	5.68° flexed
Knees	1.00cm anterior	4.01cm anterior	1.67° flexed	6.50° flexed
Total	14.41cm	15.96cm	27.5°	25.9°

Fig. 7. Left posture displacements.

reported she was no longer waking up with sore facial muscles and a dull pain in the TMJ area.

Subsequently, all interferences and premature dental contacts detected during occlusal dynamics were removed.

The patient was recalled periodically for orofacial and postural reevaluation, using the same methods, performed by the same clinician each time.

By comparing the examination performed during the initial consult with those carried out approximately a year later, the results speak for themselves.

Clinically, the patient becomes asymptomatic.

There was no pathological change (clinical or symptomatic) evident during the examination of the orofacial muscles. Occlusion was functional both statically and dynamically, without interferences or premature contacts.

The axiographic examination revealed the following results: the opening of the mouth was done within physiological limits, without menton deviation; anterior guidance was normally accomplished, the graphic paths (from maximum intercuspation to maximum propulsion and back) overlapping. Lateral guidance was also within physiologic parameters (Figure 3). 2017

All variables studied with the PostureScreen Mobile application during the two postural examinations have undergone changes in the sense that after eliminating interferences and performing occlusal equilibration the posture had considerably improved. It is noticeable during frontal examination that the head deviation level (in cm) was significantly reduced from 0.59 cm to the right to 0.05 cm to the left, being very close to the body's vertical axis.

	10/17/17	11/28/16	Change	
Estimated Head Weight	5.0 kg	4.9 kg	-0.1 kg	-1.6%
Effective Head Weight	12.0 kg	12.4 kg	0.3 kg	2.7%

Body Region	Lateral Translations		Lateral Angulations	
	10/17/17	11/28/16	10/17/17	11/28/16
Head	2.87cm anterior	4.33cm anterior	10.20° extended	15.40° extended
Shoulder	7.34cm posterior	6.70cm posterior	7.39° extended	6.72° extended
Hip/Pelvis	5.97cm anterior	4.88cm anterior	8.82° extended	7.00° extended
Knees	0.64cm anterior	4.38cm anterior	0.84° extended	6.96° extended
Total	16.83cm	20.29cm	27.2°	36.1°

Fig. 8. Estimated effective head weight change and average lateral displacements.

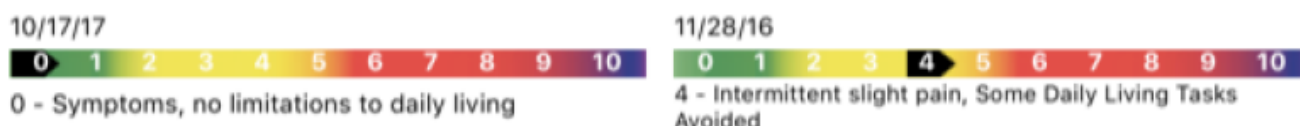

Fig. 9. Pain scale.

As a whole, the body’s anterior translation in this position decreased from 3.37 cm to 2.65 cm and the anterior angulation was reduced from 3.7 ° to 0 ° (Figure 4).

When comparing the two posterior examinations, there is a noticeable reduction of the body’s posterior translation from 5.88 cm to 3.41 cm. The posterior angulation has also decreased. (Figure 5).

Upon right lateral examination, one notices significant improvements between the two sets of results. Deviation of the head towards the front is reduced from 6.42 cm to 2.37 cm and knee deflection towards the front decreases from 4.74 cm to 0.27 cm. The overall lateral translation at this position decreased from 24.62 cm to 19.25 cm. The lateral angulation decreased from 46.3° to 27.0° - head flexion reduced from 22.91° to 8.13° and knee flexion decreased from 7.43° to 0°(Figure 6).

Improvements in posture are also obvious when comparing the results from the initial and the second left lateral examination. Posterior deviation of the shoulders was reduced from 5.75 cm to 3.47 cm and anterior knee deflection from 4.01 cm to 1 cm. As a whole, lateral translation at this position was reduced from 15.96 cm to 14.41 cm (Figure 7)

The estimated head weight and the physical measured weight of the head were not subject to significant changes. The average lateral head deviation towards the front decreased from 4.33 cm to 2.87 cm and from 4.38 cm to 0.64 cm at knee level. The average head deviation angle and the body’s average deviation angle (examined in lateral plane) were reduced (Figure 8). An improvement in the patient’s health and comfort is also obvious when examining the pain scale (Figure 9).

Discussion

This case shows the impact of occlusal dysfunction both on the TMJ and the orofacial muscles as well as on the body’s posture. A pathological dental occlusion creates a tonus imbalance in the masticatory muscles that triggers a series of compensatory mechanisms, modifying the tonus of the spinal muscles and therefore the posture.

The presence of interferences during functional movements of the mandible leads to the occurrence of eccentric motion at TMJ level, which overworks the orofacial muscles on the same side. In the patient’s case all of these events culminated in a unilateral algo-dysfunctional orofacial syndrome, which limited TMJ movement on the same side. This was also observed on the axiography.

A study performed by Tecco et al (2010) investigated weather experimentally induced malocclusion could influence the postural loading on feet during walking on Caucasian females. They observed that the percentage of loading and the loading surface of the ipsi-lateral foot, left or right, were found to be significantly lower in experimental induced malocclusion than in habitual occlusion.

In our study, significant deviations were observed during the initial postural examination performed with the PostureScreen Mobile application, which compared the variables to the vertical axis, considered normal.

The patient was re-called 10 months later, after she wore the splint and after removal of all the interferences that triggered the imbalance. The following aspects were observed:

- the disappearance of painful symptoms
 - the axiography revealed the TMJ having regained its mobility during functional movements
 - the postural examination report showed considerable improvement of the body’s position relative to the vertical axis.
- Similar results were obtained by Baldini et al (2012) in the case of a professional athlete who experienced better posture and sport performances after gnathological treatment (intraoral splint). Thus, the effectiveness of occlusal equilibration is clear, as evidenced by both clinical and paraclinical improvement through axiography and postural examination performed with the PostureScreen Mobile application.

Unlike axiography that requires a special device, which is not available in all dental offices, the PostureScreen Mobile application is a cheap postural examination option available to any dentist. Simple, fast and easily reproducible, it does not require costly equipment or an in-depth knowledge of posturology. It

can be used as a method to evaluate and screen posture, allowing a dynamic assessment (multiple examinations at different time intervals) of the patient with the ability to compare the results. The assessment of the effect of occlusal equilibration on posture thus becomes easier.

Conclusions

The influence of occlusal splints' impact on muscle strength is frequently significant. An occlusal change in the stomatognathic system impacts on posture. Occlusal deficits seem to correlate with deteriorated body posture, which, according to the results in our study, can be improved by a myocentric bite position using an intraoral splint.

References

- Baldini A, Beraldi A, Nota A, Danelon F, Ballanti F, Longoni S. Gnathological postural treatment in a professional basketball player: a case report and an overview of the role of dental occlusion on performance. *Annali di Stomatologia* 2012;3(2):51-58.
- Baldini A, Nota A, Cioffi C, Ballanti F, Cozza P. Infrared thermographic analysis of craniofacial muscles in military pilots affected by bruxism. *Aerosp Med Hum Perform* 2015;86(4):374-378.
- Baldini A, Nota A, Cioffi C, Ballanti F, Tecco S. Mandibular position influence on pilots' postural balance analyzed under dynamic conditions. *Cranio* 2016;23:1-5.
- Chaves TC, Turci AM, Pinheiro CF, Sousa LM, Grossi DB. Static body postural misalignment in individuals with temporomandibular disorders: a systematic review. *Braz J Phys Ther* 2014;18 (6):481-501.
- Kandel ER, Schwartz JH, Jessell TM. Principles of neural science. 5th. McGraw-Hill Education/Medical; 2012.
- Ivanenko Y, Gurfinkel VS. Human postural control. *Front Neurosci* 2018;20(12):171.
- Makofsky HW, Goldstein LB. The role of body posture in musculoskeletal pain syndromes. *Pract Pain Manag* 2011;3:31.
- Nakahara H, Nakasato N, Kanno A, Murayama S, Hatanaka K, Itoh H. Somatosensory-evoked fields for gingiva, lip, and tongue. *J Dent Res* 2004;83:307-11.
- Manfredini D, Castroflorio T, Perinetti G, Guarda-Nardini L. Dental occlusion, body posture and temporomandibular disorders: where we are now and where we are heading for. *J Oral Rehabil* 2012;39(6):463-471.
- Piancino MG, Roberi L, Frongia G, Reverdito M, Slavicek R, Bracco P. Computerized axiography in TMD patients before and after therapy with 'function generating bites'. *J Oral Rehabil* 2008;35(2):88-94
- Poșor S, Coman L, Drașoveanu C, Carmen Biriș, Szasz O. Sistemul CADIAS-CADIAX în diagnosticul disfuncțiilor craniomandibulare. *Medicina Stomatologică* 2002;6(4):73-76.
- Ries LGK, Bérzin, F. Analysis of the postural stability in individuals with or without signs and symptoms of temporomandibular disorder. *Braz. Oral Res* 2008;22(4):378-383.
- Rocha T, Castro MA, Guarda-Nardini L, Manfredini D. Subjects with temporomandibular joint disc displacement do not feature any peculiar changes in body posture. *J Oral Rehabil* 2017;44 (2):81-88.
- Silva AG, Punt TD, Sharples P. Head posture and neck pain of chronic nontraumatic origin: a comparison between patients and pain-free persons. *Arch Phys Med Rehabil* 2009;90(4):669-674.
- Tecco S, Polimeni A, Saccucci M, Festa F. Postural loads during walking after an imbalance of occlusion created with unilateral cotton rolls. *BMC Res Notes*.2010;25(3):141.

Authors

- Simona Maria Iacob, Department of Prosthodontics "Iuliu Hațieganu" University of Medicine and Pharmacy, 32 Clinicilor Street, 400006, Cluj-Napoca, Cluj, Romania, EU
- Andrea Maria Chisnoiu, Department of Prosthodontics "Iuliu Hațieganu" University of Medicine and Pharmacy, 32 Clinicilor Street, 400006, Cluj-Napoca, Cluj, Romania, EU
- Mirela Ioana Fluerașu, Department of Prosthodontics "Iuliu Hațieganu" University of Medicine and Pharmacy, 32 Clinicilor Street, 400006, Cluj-Napoca, Cluj, Romania, EU
- Liana Maria Lascu, Department of Prosthodontics "Iuliu Hațieganu" University of Medicine and Pharmacy, 32 Clinicilor Street, 400006, Cluj-Napoca, Cluj, Romania, EU
- Ioana Iacob, Faculty of General Medicine, "Iuliu Hațieganu" University of Medicine and Pharmacy, 6 Victor Babes Street, 400008, Cluj-Napoca, Cluj, Romania, EU
- Radu Chisnoiu, Department of Odontology, "Iuliu Hațieganu" University of Medicine and Pharmacy, 33 Motilor Street, 400003, Cluj-Napoca, Cluj, Romania, EU
- Laurentiu Pascu, Department of Prosthodontics "Iuliu Hațieganu" University of Medicine and Pharmacy, 32 Clinicilor Street, 400006, Cluj-Napoca, Cluj, Romania, EU

Citation Iacob SM, Chisnoiu AM, Fluerașu MI, Lascu LM, Iacob I, Chisnoiu R, Pascu L. Body posture improvement after occlusal correction- a case report. *HVM Bioflux* 2019;11(1):11-17.

Editor Ștefan Cristian Vesa

Received 12 November 2018

Accepted 12 December 2018

Published Online 16 January 2019

Funding None reported

**Conflicts/
Competing
Interests** None reported