

# Incarcerated septic inguinal hernia - an unusual complication of ischiorectal abscess: surgical management

<sup>1</sup>Dan D. Axente, <sup>1</sup>Vlad N. Dudric, <sup>1</sup>Tudor R. Pop, <sup>2</sup>Ioana M. Constantinescu, <sup>3</sup>Adela M. Serban

<sup>1</sup> Department of Surgery, „Iuliu Hatieganu” University of Medicine and Pharmacy, Cluj-Napoca, V-th Surgical Clinic, Cluj-Napoca, Cluj, Romania; <sup>2</sup> Department of Surgery, „Iuliu Hatieganu” University of Medicine and Pharmacy, Cluj-Napoca, II-nd Surgical Clinic, Cluj-Napoca, Romania; <sup>3</sup> Department of Internal Medicine, „Iuliu Hatieganu” University of Medicine and Pharmacy, Heart Institute “Niculae Stancioiu” Cluj-Napoca, Cluj-Napoca, Romania.

**Abstract.** Perianal abscesses are frequent surgical emergencies. Perianal abscesses are usually treated successfully by surgical drainage through perianal incision. In very rare situations these suppurations can extend to the high supralelevator space and from here the evolution towards severe local and systemic complications can be possible. The aim of this article is to present the diagnosis and treatment issues in a patient suffering from ischiorectal abscess with supralelevator extension resulting in purulent discharge incarcerated in the content of inguinal hernia. We present the possible evolution towards a rare and serious local and systemic complication of a common surgical emergency, frequently encountered in surgical pathology.

**Key Words:** ischiorectal fossa, supralelevator abscess, inguinal hernia

**Copyright:** This is an open-access article distributed under the terms of the Creative Commons Attribution License, which permits unrestricted use, distribution, and reproduction in any medium, provided the original author and source are credited.

**Corresponding Author:** V. N. Dudric, e-mail:dudricvlad@gmail.com

## Introduction

Perianal abscess is a frequent surgical emergency, with a higher incidence in men (Adamo et al 2016). The classification is mainly based on the position the abscess has in relation to the internal and external anal sphincter (Parks et al 1976). Ischiorectal abscess occurs when the purulent collection extends through the external anal sphincter and subsequently develops into the fatty and fibrous tissue of the ischiorectal fossa.

The occurrence of pelvic subperitoneal abscesses by the spontaneous extension of ischiorectal abscesses through the levator ani muscles is rare. In exceptional situations, these supralelevator abscesses can cause septic locoregional and systemic complications that can pose serious diagnostic and treatment problems. In January 2017, Anandhi et al published two cases of perianal abscesses that had progressed to retroperitoneal necrotizing fasciitis. In 2013, Peng et al, and later in 2016, Hsieh et al presented their experience related to the association of the ilioinguinal approach for two cases of ischiorectal abscess with extension to the upper presacral space and iliac fossa. All of these cases of complicated perianal abscesses presented in these articles required multiple operative sites for access and drainage of purulent collections with supralelevator extension.

## Surgical technique and therapeutic strategy

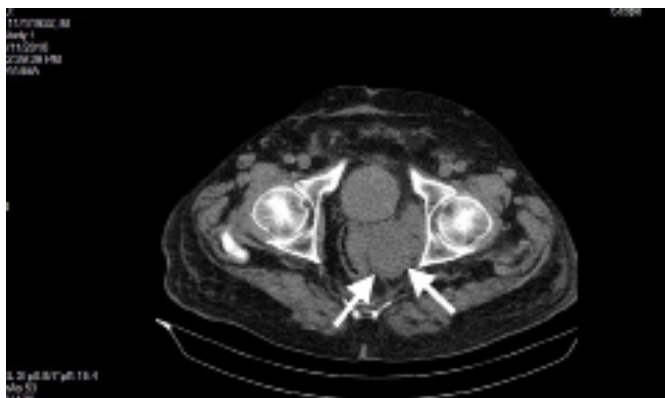
We report an 84-year-old patient who was brought to the emergency department with a 5-day history of perianal pain, fever,

and altered general condition. The patient had personal history of myocardial infarction, left ventricular dysfunction, essential hypertension, chronic bronchitis, obesity - grade II, left-side inguinal hernia.

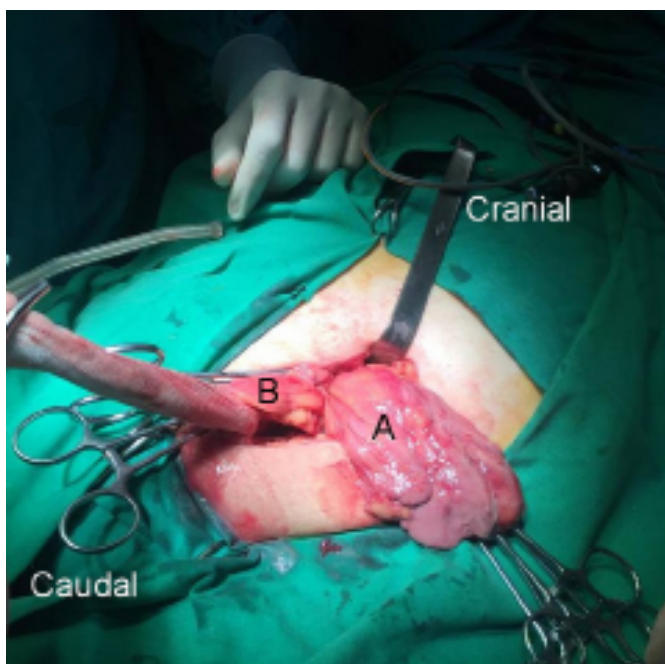
Twelve hours before, in another hospital in the Infectious Diseases Section, non-contrast computed tomography of the abdomen and pelvis was performed, raising suspicion of a perianal abscess collection within the left ischiorectal fossa with supralelevator extension, the pelvic subperitoneal collection compressing the upper rectum (Fig. 1, arrows).

Upon admission, after a coughing effort, the patient complained of sudden inguinal pain of increased intensity. General physical examination showed tachycardia (110 beats per minute) and fever (39°C). The left perianal region of the ischiorectal fossa was characterized by significant oedema, hyperaemia, spontaneous pain and pain with palpation, and extremely painful digital rectal exam. The obese patient revealed globular abdomen painless to palpation, with the presence of peristaltic sounds. The left inguinal region was characterized by irreducible inguinal hernia, with spontaneous pain and pain with palpation. Laboratory investigations showed neutrophilic leukocytosis (21,000/ml). The short initial resuscitation with intravenous fluids, antibiotics and pain relievers was followed by surgery with general anaesthesia and orotracheal intubation.

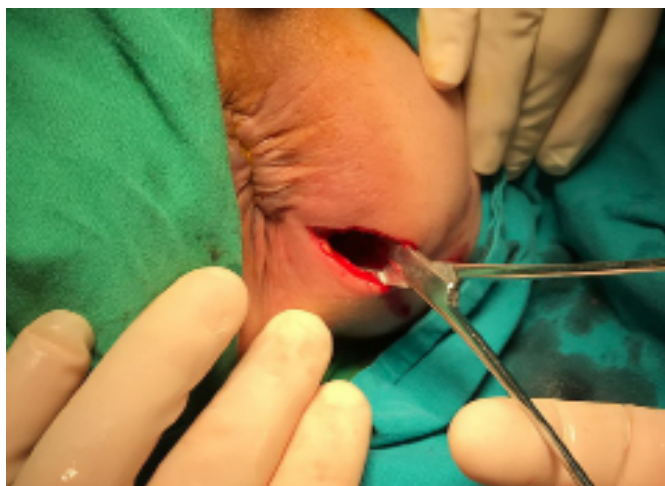
With the patient initially placed in dorsal decubitus position, the first step consisted in the surgical treatment of the painful incarcerated hernia. Upon the opening of the inguinal canal, there was evidence of Bendavid Type II inguinal hernia that only



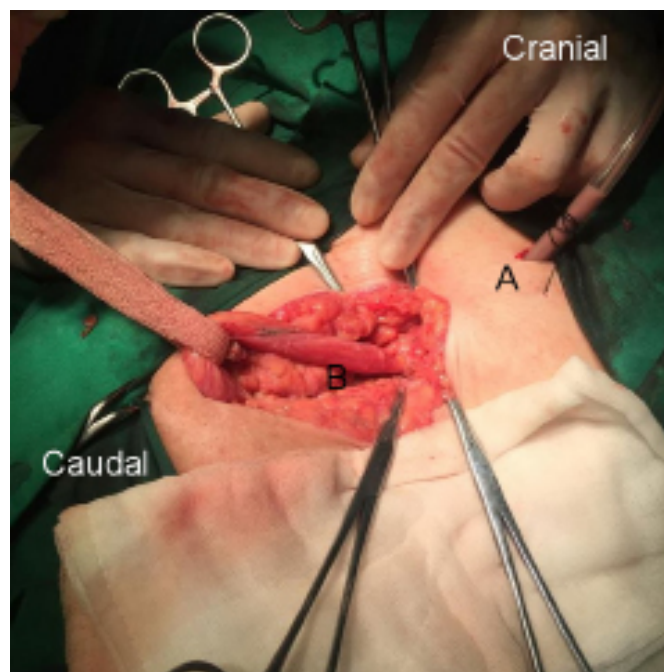
**Fig. 1** Computed tomography scan: axial view demonstrating the pelvic subperitoneal collection compressing the upper rectum (arrows)



**Fig. 2** Intraoperative picture showing the inguinal approach: A. devitalized preperitoneal adipose tissue fragments and pus evacuated from hernia contents, B. spermatic funicle



**Fig. 3** Intraoperative picture: left perianal incision and drainage



**Fig. 4** Intraoperative picture: A. extraperitoneal external drainage with a perforated tube exteriorized through transparietal counter incision, B. spermatic funicle and the repaired inguinal posterior wall – Bassini procedure

involved the posterior wall of the inguinal canal, with the normal anatomy of the deep inguinal ring. About 150 ml of odourless pus and devitalized preperitoneal adipose tissue fragments were evacuated from hernia contents (Fig. 2).

Digital exploration revealed an extraperitoneal purulent collection in the paravesical, pararectal and pelvic subperitoneal space. The patient was then placed in lithotomy position. A wide left perianal incision was performed, with the evacuation of 200 ml of pus of similar appearance (Fig. 3). The digital and instrumental examination revealed a 2-3 cm communication between the abscess cavity of the ischiorectal fossa and the supralevator abscess and the direct left-sided inguinal wall defect. The following procedures were performed: debridement, lavage, extraperitoneal external drainage with a perforated tube exteriorized through transparietal counter incision, superior to the deep inguinal ring (Fig. 4). The drainage was placed through the pararectal space and through the levator ani muscle breach, parallel to the rectum down to the ischiorectal fossa. The remaining cavity in the ischiorectal fossa was subjected to wound dressing. Hernia repair was performed via tissue technique, Bassini technique and subcutaneous drainage.

The patient was admitted to the intensive care unit for 7 days with the diagnosis of septic shock, acute respiratory failure requiring mechanical ventilation, and acute kidney failure. The patient required vasoactive treatment with noradrenaline. Intravenous antibiotic therapy was established according to the antibiogram test. The following procedures were performed: irrigation with saline solution through the left iliac fossa, extraperitoneal drainage twice a day, debridement and cleansing with antiseptic solution and wound dressing of the remaining cavity from the ischiorectal fossa with local antibiotic for 10 days. The patient was released from hospital 17 days after the

surgical procedure with a healed inguinal wound and a granular and partially epithelialized perianal plaque.

One year and a half after surgery the patient is free of symptoms. Informed consent was obtained from the participant included in the study.

## Discussions

The choice of presenting the surgical management of this specific situation was determined by the particularity of the evolution of ischio-rectal fossa abscesses and the high difficulty in terms of diagnosis and treatment.

Perianal abscesses are among the most common surgical emergencies. The clinical picture consisting of intense perianal pain, fever and leukocytosis in conjunction with the clinical examination is in most cases sufficient to provide a definite diagnosis. In rare cases when the patient's septic condition is not consistent with local clinical signs, or when atypical symptoms such as abdominal pain, extensive cellulitis, or unfavorable evolution after surgical drainage are associated, a severe evolution of these suppurations can occur. Suspicion of supralelevator extension of a perianal suppuration cannot be confirmed by clinical examination only and requires emergency pelvic CT.

The presence of the pus collection in the pelvic subperitoneal space can rarely lead to local and severe systemic complications that are difficult to diagnose and treat. In the specialty literature, several cases of extension of the suppurative process from a perianal abscess to the retroperitoneal tissue or of extended posterior retroperitoneal necrotizing fasciitis have been reported (Anandhi et al 2017; Butt et al 2017). Of the severe rare complications of perianal suppurations, in 2015 Toh et al published a case of Fournier's gangrene with the suppurations starting from a perianal abscess. In 2016 another rare case was published by Gujrathi et al consisting of an inflammatory irritation of the sciatic nerve by the fusion of a supralelevator abscess. Such particular situations require prompt surgical treatment, which involves a simultaneous approach by use of incisions placed in distinct anatomical regions. The combined perianal and ilioinguinal approach, either uni- or bilaterally, is used and described by Peng in two cases of extended supralelevator abscesses in the iliac fossae (Peng et al 2013, Hsieh et al 2016). The perianal approach combined with the lumbar retroperitoneal approach in posterior necrotizing fasciitis is used and described by Anandhi et al (2017) while the perianal approach combined with the transabdominal one is described by Sanyal et al (2012).

## Conclusion

The evolution towards severe local and systemic complications of a perianal abscess should be considered in the cases where the symptomatology or evolution of these perianal suppurations is complex or inconsistent with the local clinical picture of the lesion. The request for abdominoperineal CT should be considered in these cases. Surgical treatment should be prompt and customized for the specific clinical and imaging situation. Simultaneous multilocular surgical approach may be a necessity in these situations.

## References

- Adamo K, Sandblom G, Brännström F, Strigård K. Prevalence and recurrence rate of perianal abscess--a population-based study, Sweden 1997-2009. *Int J Colorectal Dis* 2016;356:669-73. doi:10.1007/s00384-015-2500-7.
- Parks AG, Gordon PH, Hardcastle JD. A classification of fistula-in-ano. *Br J Surg* 1976;356:1-12. doi:10.1002/bjs.1800630102.
- Anandhi A, Sahoo A, Barathi D, et al. Retroperitoneal Necrotizing Fasciitis Masquerading as Perianal Abscess – Rare and Perilous. *Cureus* 2017;9(1):e982. doi:10.7759/cureus.982.
- Peng KT, Hsieh MC, Hsu WH, Li YY, Yeh CH. Anterior ilioinguinal incision for drainage of high-located perianal abscess. *Tech Coloproctol* 2013;17:455–458.
- Hsieh MC, Huang WS, Chin CC, Kuo YH, Peng KT. Drainage of a complicated high perianal abscess: a bilateral ilioinguinal approach. *Tech Coloproctol* 2016;20(8):595-6. doi:10.1007/s10151-016-1480-0.
- Butt UI, Bhatti S, Wadood A, Rehman UA et al. A case report of pneumo-retro-peritoneum: An unusual presentation of ischio-rectal abscess. *Ann Med Surg (Lond)* 2017;26;20:66-68. doi: 10.1016/j.amsu.2017.06.023.
- Toh JW, Gibson K, Vanlioglu B, Ang S, Ong E (2015) Rapid progression of perianal abscess into Fournier's gangrene. *ANZ J Surg* 85(3):192-3. doi: 10.1111/ans.12811.
- Gujrathi R, Gupta K, Ravi C, Pai B. Sciatica: An Extremely Rare Complication of the Perianal Abscess. *Pol J Radiol* 2016;6;81:370-373.
- Sanyal S, Khan F, Ramachandra P. Successful management of a recurrent supralelevator abscess: a case report. *Case Rep Surg* 2012;2012:871639. doi: 10.1155/2012/871639.

## Authors

- Dan D. Axente, Department of Surgery, „Iuliu Hatieganu” University of Medicine and Pharmacy, Cluj-Napoca, 5-th Surgical Clinic, 11-th Tabacarilor Street, 400139, Cluj-Napoca, Cluj, Romania, EU, email: d\_axente@yahoo.com
- Vlad N. Dudric, Department of Surgery, „Iuliu Hatieganu” University of Medicine and Pharmacy, Cluj-Napoca, 5-th Surgical Clinic, 11-th Tabacarilor Street, 400139, Cluj-Napoca, Cluj, Romania, EU, email: dudricvlad@gmail.com
- Tudor R. Pop Department of Surgery, „Iuliu Hatieganu” University of Medicine and Pharmacy, Cluj-Napoca, 5-th Surgical Clinic, 11-th Tabacarilor Street, 400139, Cluj-Napoca, Cluj, Romania, EU, email: poptudorradu@gmail.com
- Ioana M. Constantinescu, Department of Surgery, „Iuliu Hatieganu” University of Medicine and Pharmacy, Cluj-Napoca, 2-nd Surgical Clinic, 5-th Clinicilor Street, 400006, Cluj-Napoca, Cluj, Romania, EU, email: ioanacostantinescu2003@yahoo.com
- Adela M. Serban, Department of Internal Medicine, „Iuliu Hatieganu” University of Medicine and Pharmacy, Cluj-Napoca, Heart Institute “Niculae Stancioiu” Cluj-Napoca, 21-st Matorilor Street, 400001 Cluj-Napoca, Romania, EU, email: adelamserban@yahoo.com

<b>Citation</b>	Axente D, Dudric VN, Pop TR, Constantinescu IM, Serban AM. Incarcerated septic inguinal hernia - an unusual complication of ischiorectal abscess: surgical management. HVM Bioflux 2018;10(3):154-157.
<b>Editor</b>	Stefan Vesa
<b>Received</b>	12 September 2018
<b>Accepted</b>	26 September 2018
<b>Published Online</b>	29 September 2018
<b>Funding</b>	None reported
<b>Conflicts/ Competing Interests</b>	None reported