

Diagnostic and treatment challenges in the centrally mediated abdominal pain syndrome – a case report

¹Mirela G. Perné, ²Mircea V. Milaciu, ²Ioana Para, ²Vasile Negrean, ²Dorel P. Sâmpolean, ²Teodora G. Alexescu, ²Lorena Ciumărnean

¹“Octavian Fodor” Regional Institute of Gastroenterology and Hepatology, Cluj-Napoca, Romania

²Department V, IVth Medical Discipline, “Iuliu Hațieganu” University of Medicine and Pharmacy, Cluj-Napoca, Romania

Abstract. Aim: The objective of this report is to present the diagnostic challenges in the case of a 73-years-old woman who presented for an atypical abdominal pain, experienced during the last 40 years, with very short calm periods. Case report: Between 1973 and 2016, the patient had multiple admissions and medical consultations, different opinions about her symptoms being raised by her doctors. She had undergone therapy with antiseptic, anti-inflammatory agents, regulators of gut motility, gastric anti-secretory drugs. The experienced response to treatment was always poor, no drug being found useful in those 40 years. Discussion: Due to the presence of chronic visceral pain of undetermined etiology and in the absence of organ damage (as stated by biological, imagistic and endoscopic tests), according to Rome IV criteria we established the diagnosis of centrally mediated abdominal pain syndrome. The treatment was initiated with low dosage tricyclic antidepressants, namely 25 mg Amitriptyline, which led to the complete remission of the abdominal pain after about one month of treatment. Conclusion: This clinical case emphasizes the difficulty of implementing a clear diagnostic algorithm for the centrally mediated abdominal pain syndrome. Also, it highlights the need to improve time management and hospitalization costs, the importance of establishing a therapeutic approach and a doctor-patient relationship based on trust, as well as the need for a multidisciplinary team approach.

Key Words: centrally mediated abdominal pain syndrome, functional disorders, functional abdominal pain, tricyclic antidepressants

Copyright: This is an open-access article distributed under the terms of the Creative Commons Attribution License, which permits unrestricted use, distribution, and reproduction in any medium, provided the original author and source are credited..

Corresponding Author: M. Milaciu, email: mircea_milaciu@yahoo.com

Introduction

Centrally mediated abdominal pain syndrome, formerly known as functional abdominal pain syndrome, is characterized by chronic, recurrent or continuous abdominal pain that does not occur as a consequence of organ or systemic disease. Centrally mediated pain is not influenced by common physiological stimuli such as diet, defecation, exercise, or menstruation, and lasts at least 6 months before the diagnosis is established (Keefe et al 2016). The unexplained chronic visceral pain occurs in the absence of organ damage, proven by biological, imagistic and endoscopic tests. Patients often describe the pain in emotional terms, being located in major anatomical areas of the abdomen, usually associated with psychiatric comorbidities (anxiety, depression, somatization disorder), but there is no specific profile for diagnosis; these details can guide physicians for the diagnosis of central abdominal pain. (Clouse et al 2006, Drossman et al 1982). The prevalence of this pathology varies from 0.5% to 2.1% and women are twice as likely to experience it. Approximately 80% of patients with centrally mediated abdominal pain presented themselves to a doctor at least three times a year and have requested various endoscopic imaging techniques, and besides that, 2.7% of them have undergone surgery, mainly hysterectomy and laparoscopic exploration (Drossman et al 1993, Thompson et al 2002, Koloski et al 2002).

The purpose of presenting this clinical case is to emphasize the difficulty of implementing the diagnostic workup for this

pathology, altogether with finding the efficient treatment for these patients.

To our knowledge, this is the first case reporting this syndrome in the literature.

Case report

The 73-year-old patient from the rural environment, retired, with a history of hypertension, with Type 2 Diabetes Mellitus (controlled by diet and antidiabetic drugs since 2006), antral erythematous gastritis, irritable bowel syndrome, second grade internal hemorrhoids, who underwent cholecystectomy and subtotal hysterectomy for uterine fibroids in 1973, presented for diffuse abdominal pain, more pronounced in the umbilical region, the left hypochondrium and the bilateral flanks. She also accused associated appetite loss, asthenia and fatigue. Symptoms had an insidious onset about 40 years ago, characterized by abdominal pain experienced “all over the abdomen” that sometimes irradiates in the lumbar region, with a nonspecific character, manifested by ‘permanent’ stinging, stabbing or pressure of varying intensity for about 40 years, with very short calm periods. The associated general symptoms are characterized by ‘weakness’, ‘malaise’, ‘irritation’, the patient describing the situation as ‘unbearable, nobody can diagnose it.’

Between 1973 and 2016, the patient had multiple admissions and medical consultations, resulting in various diagnoses such as antral erythematous gastritis, internal hemorrhoids, irritable

bowel syndrome, cholelithiasis. She had undergone therapy with antiseptic, anti-inflammatory agents, regulators of gut motility, gastric antisecretory drugs. Each time she experienced poor response to treatment, no drug being found useful in those 40 years, with the observation that intravenous preparations were more effective than those administered intramuscularly.

During admission, the patient showed slightly altered general condition, suffering face expression, grade I obesity, sensitivity to deep palpation of the umbilical region and bilateral flanks, and positive Carnett's test for visceral pain. No other pathological changes were identified during general examination.

Biologically, the following were detected: hyperglycemia, mixed dyslipidemia, elevated levels of HbA1c and anti-TPO antibodies, blood in urine, normal parameters for coproparasitological examination.

During the last 6 months, prior to the current hospitalization, the patient performed numerous complementary examinations, namely upper GI endoscopy, lower GI endoscopy, abdominal ultrasound, thyroid ultrasound, MRI of the abdomen and pelvis, and MRI of the lumbar and thoracic spine, which did not bring arguments of organ impairment to justify the presence of abdominal pain and its persistence for 40 years.

Investigations were followed by the determination of anti-gliadin and anti-endomysium antibodies to exclude gluten-sensitive enteropathy, delta-amino levulinic acid and urinary porphyrins for the exclusion of porphyria, and plumbemia for the exclusion of lead poisoning. All these suspicions were invalidated by the normal values of the parameters.

Differential diagnosis was also performed with adherence syndrome following surgery characterized by chronic abdominal pain resembling cramps and associated with abdominal distention; with diabetic autonomic neuropathy that clinically manifests itself as chronic abdominal pain resembling cramps, but with nocturnal occurrence. In the case of irritable bowel syndrome, according to Rome IV criteria (2016), abdominal pain occurs together with transit changes and improves with defecation (Drossman et al 2016, Schmulson et al 2017). In the present case, abdominal pain is chronic, but it does not occur concurrently with transit changes, it does not disappear after defecation, it does not appear nocturnally and it is not associated with abdominal distension. The pain described by the patient is persistent, and its onset was prior to surgery for subtotal hysterectomy.

In this context, describing pain in emotional terms and not being able to identify common physiological stimuli (nutrition, defecation, exercise) that influence the appearance of pain, has led us to think of a functional component of this type of pain. Centrally mediated abdominal pain syndrome may be differentiated from other functional gastrointestinal disorders by its strong central component, by its independence from motility disorders and by signs that target the visceral component of pain. In order to differentiate between parietal and visceral pain, we considered Carnett's sign useful on clinical examination. Palpation of the abdominal wall was performed in dorsal decubitus so that the abdominal wall would be relaxed. Then, as the abdominal muscles contracted and the sensitivity to palpation of the central abdominal region was objectified, the patient was asked to lift her torso slowly without resting her arms. Sensitivity to palpation has decreased and we considered this test as positive for visceral pain (Ballantyne et al 2013).

Due to the presence of chronic visceral pain, of undetermined etiology, and in the absence of organ damage (as stated by biological, imagistic and endoscopic tests), according to Rome IV criteria published in 2016, we established the diagnosis of functional abdominal pain (Drossman et al 2016).

Once diagnosed, it was recommended to initiate treatment with low dosage tricyclic antidepressants, namely 25 mg Amitriptyline, as recommended by IASP (International Association for the Study of Pain, Ballantyne et al 2013) and to re-evaluate the case after 8 weeks. At the same time, the treatment of comorbidities associated with oral antidiabetic drugs for diabetes mellitus (Metformin 1000 mg 1-0-1, Glyclazide 60 mg 1-0-1), anti-hypertensive agents and hypolipidemic agents was continued.

The patient returned to admission 8 weeks after the initiation of tricyclic antidepressant therapy and reported the remission of abdominal pain after about one month of treatment, but after approximately 6 weeks from treatment onset, she stopped medication on her own initiative, even though abdominal pain had disappeared. She explained her decision as determined by the occurrence of anticholinergic side effects such as constipation (1 stool every 3 days, of firm consistency, no pathological products), and due to the stigmatization of "psychiatric drugs". It was decided to continue treatment with Amitriptyline, with regulators of intestinal transit and probiotics.

According to the International Association for Study of Pain, the first treatment option for functional abdominal pain is Amitriptyline. If there is no improvement after 6 to 8 weeks of treatment, the next class of drugs is represented by selective serotonin reuptake inhibitors (Duloxetine); in case of therapeutic failure after another 6-8 weeks of therapy, with patients presenting the persistence of painful physical symptoms, it is recommended to introduce psychotherapy in addition to the above-mentioned drug classes (Ballantyne et al 2013). Though in our case the therapy was successful after approx. 6 weeks following initiation of treatment, we recommended psychological support to increase confidence in the recommendations received and to find effective strategies to treat social stigma in a positive way, avoiding related treatment discontinuation in the future, the case being reassessed following continuous treatment with tricyclic antidepressants after 8 weeks.

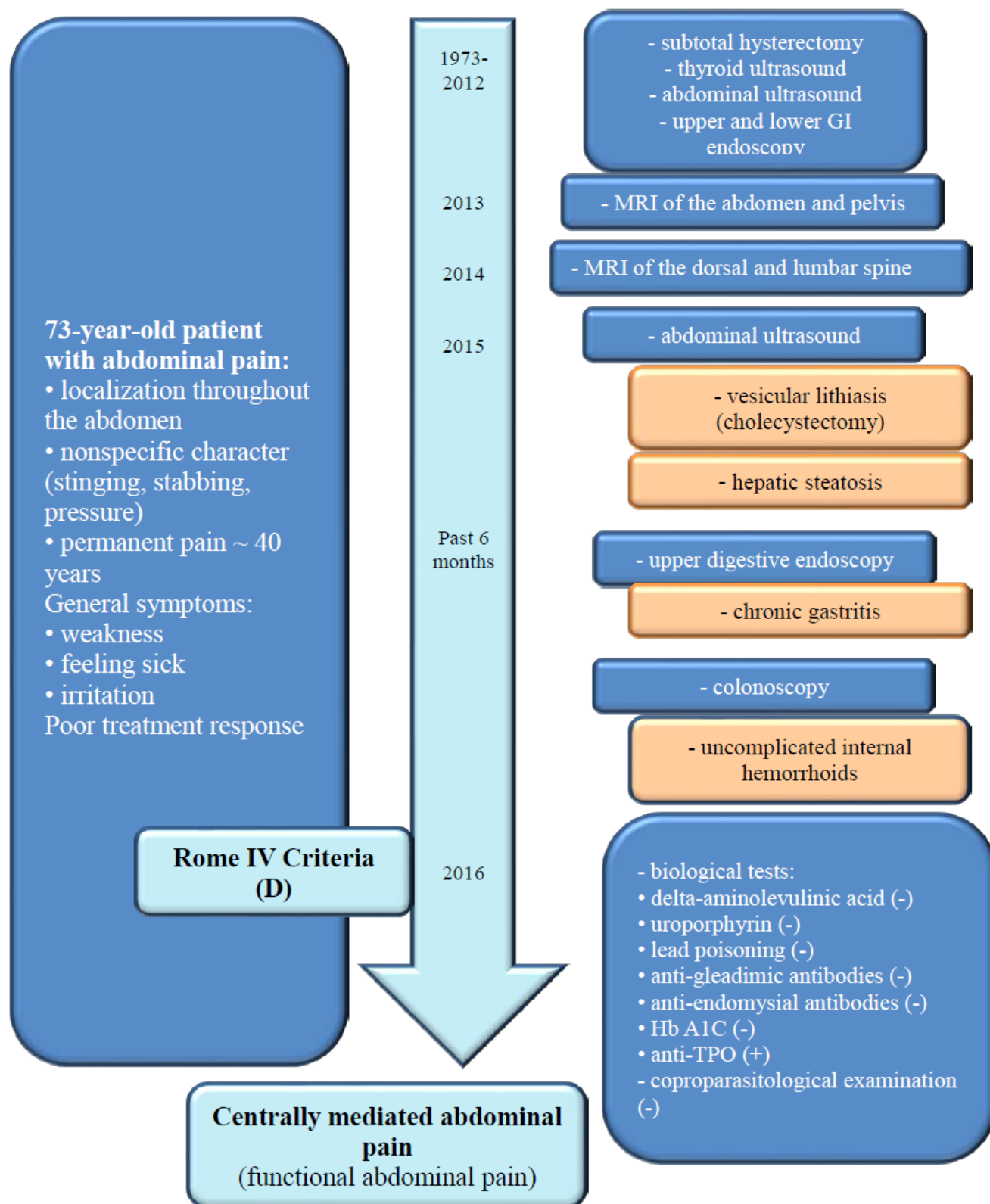
Informed consent was obtained from the patient prior in preparing the present manuscript. The full history and summary of our patients' symptoms and diagnostic workup is detailed in Figure 1.

Discussion

Abdominal pain is a common symptom for which most patients seek medical examination. Patient history and clinical examination are essential in establishing a diagnosis, while paraclinical examinations (biological tests, imaging and endoscopic techniques) help confirm the diagnosis.

However, in some cases, there is no organ damage to explain this type of pain. Functional abdominal pain is characterized on one hand by the absence of organ damage to justify pain and on the other hand by the fact that patients are not able to describe the localization of pain in certain abdominal regions, rather referring to it as experienced throughout the abdomen (Ryu et al 2018). In our case, persistent pain has been present for about 40 years, and felt "all over the abdomen".

Figure 1. Diagnostic workup in our patient's case



To date, irritable bowel syndrome has been the most commonly diagnosed functional digestive disorder. However, a new type of pathology has been identified, a new disease entity, that is functional abdominal pain, whose characteristics cannot be fully integrated into irritable bowel syndrome (Lacy et al 2017). According to Rome IV criteria, functional abdominal pain was renamed centrally mediated abdominal pain syndrome and it is to be distinguished from irritable bowel syndrome by the nature of pain that is persistent, recurrent, the onset of pain occurring 6 months before diagnosis, not being influenced by physiological events, interfering with daily activities, not simulated, and described in emotional terms (Drossman et al 2016).

According to the patient's description, pain is non-specific, felt as stinging, stabbing or pressure. Generally associated symptoms such as malaise, weakness, irritation - "it is unbearable, nobody can establish a diagnosis" and poor treatment response - "no efficient drug in 40 years", intravenous formulations being more effective than those administered intramuscularly enhance the emotional description of pain. At the same time, patients with painful abdominal syndrome report the chronology of painful events in detail, especially with regard to surgical interventions (Farmer et al 2014). Similarly, in our case, the patient also reported the chronology of painful episodes in detail for each year when she had undergone surgery for hysterectomy and cholecystectomy, as well as for biological, imaging and endoscopic examinations.

There is currently no clear diagnostic algorithm or absolute consensus on the type of therapy to be used in patients with functional pathologies. A rigorous anamnesis of clinical history of persistent or recurrent abdominal pain lasting at least 6 months, the lack of association with physiological events, the absence of warning signs during clinical examination, and the belief that the patient does not mimic pain should direct us towards this diagnosis (Thompson et al 1999).

In order to manage such a case successfully, it is very important to take into account the doctor-patient relationship. Most of these patients have been examined by various doctors, who established different diagnoses, even accusing them of mimicking their pain, or underestimating their symptoms. Thus, patients feel disappointed, and this leads to the search for another clinician to conduct more investigations, involving other costs, and so the cycle resumes (Lacy et al 2017). In the case presented here, we noticed that over the past 40 years various diagnoses have been established, unable to explain the persistence of abdominal pain, fuelling the patient's disappointment and increasing her impatience in finding the right clinician. The most challenging aspect in managing the functional patient is to establish a doctor-patient relationship based on trust, empathy and disease validation, so treatment compliance will increase significantly. Antidepressants are generally accepted as the first line of pain management in functional abdominal pain, although, to date, there is a lack of robust data in the centrally mediated abdominal pain syndrome's management. In the treatment of functional pathologies, two broad classes of antidepressants are used: tricyclic antidepressants and serotonin-norepinephrine reuptake inhibitors (Farmer et al 2014). The latter have anxiolytic effects, low side effects, but the therapeutic efficacy is inferior to that of tricyclic antidepressants.

In the present case we have chosen Amitriptyline as therapeutic agent, which is the preferred first-line treatment (IASP, 2013) (Ballantyne et al 2013). The antinociceptive mechanism of the action of tricyclic antidepressants such as Amitriptyline is not clearly defined in functional diseases, but three mechanisms of action have been described. First, the modulation of descending inhibitory pathways; second, through binding at the NMDA receptor on spinal dorsal horn and finally via direct inhibition of Na⁺/K⁺ channels on spinal afferents (Farmer et al 2014). Virtually, it increases the amount of neurotransmitters that block the transmission of gastrointestinal pain at the central level. It has analgesic effect when administered in low doses and antidepressant effect when administered in high doses (Schumlon et al 2017).

After a discussion with the patient and after establishing realistic therapeutic goals, we decided for low-dose Amitriptyline (25 mg) administered in the evening to avoid side effects such as somnolence. Clinical evolution was favourable, with the disappearance of pain after about 6 weeks of treatment. However, the patient stopped the treatment due to the occurrence of anticholinergic side effects such as constipation and dry mucous membranes, which could have been tolerated, but mainly because of the stigmatization of "psychiatric drugs".

Analyzing the patient's detailed clinical history and the fact that one of the reasons for treatment discontinuation on her own initiative was due to the social stigma of a user of "psychiatric drugs", we concluded that the psychological exam and psychotherapy were not part of the diagnostic and therapeutic algorithm of this patient. Referring to our search in the literature, we have not found a case-report to serve as a guide in the management of such a case, from our point of view a multidisciplinary approach would have been necessary to achieve realistic goals, combining the psychological and pharmacological characteristics in order to achieve and strengthen the therapeutic success in this case (Farmer et al 2014).

Conclusion

Centrally mediated abdominal pain is a type of abdominal pain that interferes with daily activities and has been present for at least 6 months prior to diagnosis. Pain can be persistent, almost constant or recurring. Positive diagnosis is based on Rome IV criteria, in the absence of warning symptoms and based on the long duration of symptoms. The management of this functional condition is based on the doctor-patient relationship and the use of controversial drug classes such as tricyclic antidepressants. In our case, there is a long history of abdominal pain, with multiple clinical and paraclinical examinations performed over many years. The lack of organ damage or a systemic condition to explain the persistence of pain, as well as the patient's emotional description of pain, have guided us towards the diagnosis of functional abdominal pain.

There is a need for a clear algorithm regarding the diagnostic workup and the treatment for the centrally mediated abdominal pain syndrome.

References

Clouse RE, Mayer EA, Aziz Q, et al. Functional abdominal pain syndrome. *Gastroenterology* 2006;130:1492-1497.

Drossman DA, Li Z, Andruzzi E, et al. US householder survey of functional gastrointestinal disorders. Prevalence, sociodemography, and health impact. *Dig Dis Sci* 1993;38:1569–1580.

Drossman DA. Functional Gastrointestinal Disorders: History, Pathophysiology, Clinical Features, and Rome IV. *Gastroenterology* 2016;150:1262–1279.

Drossman DA. Patients with psychogenic abdominal pain: six years' observation in the medical setting. *Am J Psychiatry* 1982;139:1549–1557.

Farmer AD, Aziz O. Mechanisms and management of functional abdominal pain. *J Roy Soc Med* 2014;107(9):347–354.

International Association for the Study of Pain. *Pain Clinical Updates*, Vol. XXI, Issue June 2013 Edited by Jane C. Ballantyne, MD, FRCA Anesthesiology, Pain Medicine USA.

Keefer L, Drossman DA, Guthrie E, Simrén M, Tillisch K, Olden K, Whorwell PJ. Centrally Mediated Disorders of Gastrointestinal Pain. *Gastroenterology* 2016;150:1408–1419.

Koloski NA, Talley NJ, Boyce PM. Epidemiology and health care seeking in the functional GI disorders: a population-based study. *Am J Gastroenterol* 2002;97:2290–2299.

Lacy BE and Pate NK. Rome Criteria and a Diagnostic Approach to Irritable Bowel Syndrome. *J Clin Med* 2017;6(11):pii:E99.

Ryu HS, Choi SK. Clinical Approach to Abdominal Pain as Functional Origin. *Korean J Gastroenterol* 2018;71(2):89–93.

Schmulson MJ, Drossman DA. What is new in Rome IV. *J Neurogastroenterol Motil* 2017;23(2):151–163.

Thompson WG, Irvine EJ, Pare P, et al. Functional gastrointestinal disorders in Canada: first population based survey using Rome II criteria with suggestions for improving the questionnaire. *Dig Dis Sci* 2002;47:225–235.

Thompson WG, Longstreth GF, Drossman DA, Heaton KW, Irvine EJ, Müller-Lissner SA. Functional bowel disorders and functional abdominal pain. *Gut* 1999;45:II43–II47.

Vanner SJ, Depew WT, Paterson WG, et al. Predictive value of the Rome criteria for diagnosing the irritable bowel syndrome. *Am J Gastroenterol* 1999;94:2912–2917.

Authors

•Mirela Georgiana Perné, “Octavian Fodor” Regional Institute of Gastroenterology and Hepatology, Cluj-Napoca, Romania; email: albmirela@yahoo.ro

•Mircea Vasile Milaciu, “Iuliu Hațieganu” University of Medicine and Pharmacy, 8 Victor Babeș street, Cluj-Napoca, Romania; email: mircea_milaciu@yahoo.com

•Ioana Para, Iuliu Hațieganu” University of Medicine and Pharmacy, 8 Victor Babeș street, Cluj-Napoca, Romania; email: ioana.para@yahoo.com

•Vasile Negrean, Iuliu Hațieganu” University of Medicine and Pharmacy, 8 Victor Babeș street, Cluj-Napoca, Romania; email: Vasile.Negrean@umfcluj.ro

•Dorel Partene Sâmpolean, “Iuliu Hațieganu” University of Medicine and Pharmacy, 8 Victor Babeș street, Cluj-Napoca, Romania; email: dorelsampelean@hotmail.com

•Teodora Gabriela Alexescu, Iuliu Hațieganu” University of Medicine and Pharmacy, 8 Victor Babeș street, Cluj-Napoca, Romania; email: teodora_alexescu@yahoo.co.uk

•Lorena Ciumărnean, “Iuliu Hațieganu” University of Medicine and Pharmacy, 8 Victor Babeș street, Cluj-Napoca, Romania; email: lorena_ciumarnean@yahoo.com

Citation Perné MG, Milaciu MV, Para I, Negrean V, Sâmpolean D, Alexescu TG, Ciumărnean L. Diagnostic and treatment challenges in the centrally mediated abdominal pain syndrome – a case report. *HVM Bioflux* 2018;10(3):149–153.

Editor Stefan Vesa

Received 30 August 2018

Accepted 28 September 2018

Published Online 28 September 2018

Funding None reported

**Conflicts/
Competing
Interests** None reported