

# CD20 negative relapse of a follicular lymphoma after chemoimmunotherapy

<sup>1,2</sup>Cristina Bagacean, <sup>4</sup>Isabelle Quintin-Roue, <sup>3</sup>Jean-Christophe Ianotto, <sup>5</sup>Yves Renaudineau, <sup>3</sup>Adrian Tempescul, <sup>1</sup>Doinel Radeanu, <sup>1</sup>Adriana Muresan, <sup>1,2</sup>Mihnea Zdrenghea

<sup>1</sup>“Iuliu Hatieganu” University of Medicine and Pharmacy, Cluj-Napoca, Romania; <sup>2</sup>“Prof. Dr. Ion Chiricuta” Institute of Oncology, Cluj-Napoca, Romania; <sup>3</sup> Department of Clinical Hematology, Institute of Cancerology and Hematology, Brest University Medical School, France; <sup>4</sup>Laboratory of Pathoanatomy, Brest University Medical School, France; <sup>5</sup>Laboratory of Immunology, Brest University Medical School, France

**Abstract.** A chimeric antibody targeting CD20, rituximab is the first monoclonal antibody approved in cancer treatment, and is currently used in practically all B cell malignancies. Expression of CD20 is limited to mature and precursor B cells, and the histological demonstration of its presence in a tumour warrants the inclusion of rituximab in its therapy. However, repeated administration of rituximab can lead to the disappearance of CD20 molecule expression at B cell surface, rendering the drug useless. We here present a case of follicular lymphoma showing CD20 expression loss at relapse, emphasizing the importance of re-biopsy at relapse/progression.

**Key Words:** CD20, shaving, rituximab, follicular lymphoma.

**Copyright:** This is an open-access article distributed under the terms of the Creative Commons Attribution License, which permits unrestricted use, distribution, and reproduction in any medium, provided the original author and source are credited.

**Corresponding Author:** D. Radeanu, email: doinelra@yahoo.com.

## Introduction

Follicular lymphoma (FL) is the second most common form of Non-Hodgkin's lymphoma in the western world, characterized by multiple remissions and relapses, and a tendency for transformation to large B-cell lymphoma (“A clinical evaluation of the International Lymphoma Study Group classification of non-Hodgkin's lymphoma. The Non-Hodgkin's Lymphoma Classification Project,” 1997). The advent of immunotherapy in lymphoma is related to the demonstration of efficacy of a chimeric monoclonal anti CD20 antibody, rituximab, in FL. Current specific treatment of symptomatic FL includes rituximab, either as a single agent, or in association with chemotherapy, using various combinations of anthracycline-containing regimens such as CHOP (Cyclophosphamide, Doxorubicin, Vincristine and Prednisone), or cytarabine-containing regimens such as the association DHAOx (Dexamethasone, cytarabine and Oxaliplatin), a less nephrotoxic version of the classical regimen including cisplatin. We report the case of a FL patient showing loss of the CD20 molecule at relapse, after repeated treatment courses with rituximab alone and in combination with chemotherapy.

## Case description

A 56 years old man presenting multiple enlarged lymph nodes was diagnosed with FL, with a FL international prognostic index of 2. Cervical lymph node biopsy showed infiltration with centrocytes and centroblasts, grade 2 (6-10 centroblasts per high-power field) according to World Health Organisation criteria.

The tumor cells were positive for CD20 and CD10, negative for CD5 and CD23, and overexpression of BCL2 gene was demonstrated by molecular biology. The computed tomography was associated to 18-F-FDG PET scan, revealing a stage III A disease according to Ann-Arbor criteria, as bone marrow biopsy was negative for involvement.

An initial “watch and wait” approach was decided, but, six months later, signs of progression (growth of cervical and inguinal lymph nodes) were observed and it was decided to treat the patient with standard 375mg/m<sup>2</sup> weekly doses of single agent rituximab for four weeks, followed by standard maintenance single agent rituximab perfusions at same dose every second month. Two months after the treatment started, at the first follow-up/ restaging, a complete clinical remission was observed, but positivity at 18-F-FDG PET scan was present (for retroperitoneal and inguinal nodes). Rituximab maintenance was continued with the same schedule, and eight months later the cervical nodes reappeared. At that point, it was decided to stop maintenance and administer another course of 4 perfusions of rituximab 375mg/m<sup>2</sup> with dexamethasone (40 mg daily for four days) every week, with the complete clinical regression of the enlarged nodes. Maintenance treatment was stopped.

Four months later the patient relapsed with cervical lymph node enlargement. Six cycles of CHOP-21 chemotherapy plus rituximab (R-CHOP) were administered. A complete isotopic remission was confirmed, and he was put again on maintenance rituximab therapy at 375mg/m<sup>2</sup> every two months. After 6 cycles of maintenance, cervical lymph nodes reappeared and they

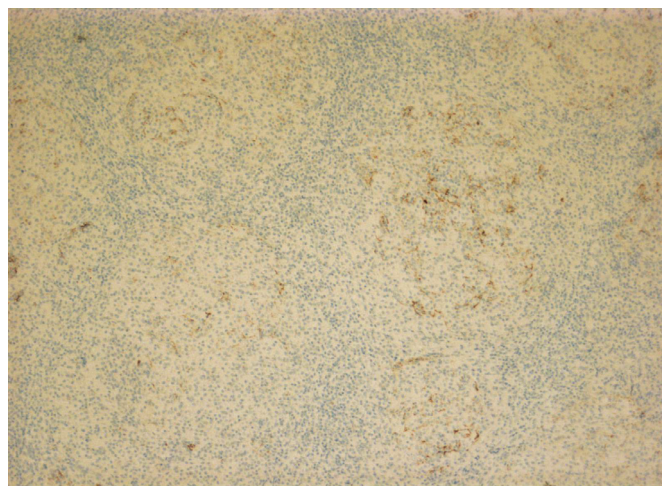
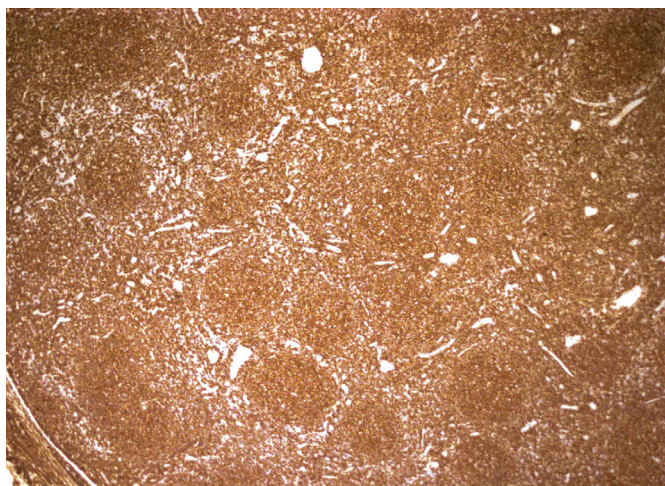


Fig. 1. Immunohistological analysis of CD 20 expression on lymph node biopsies, before (left) and after (right) treatment with Rituximab.

remained unaffected by two cycles of a rescue protocol combining rituximab with DHAOx. The histological as well as the molecular analysis of a newly biopsied cervical node were identical to the diagnostic biopsy, except for the presence of CD20 which was undetectable, although CD79a was positive as seen in Photo 1. The caryotype was complex with translocation (14;18) in 83% of metaphases. FISH did not identify a deletion of p53.

## Discussion

Rituximab has proven efficacy either alone or in combination with chemotherapy in the treatment of FL (Vidal *et al* 2009). Three main acting mechanisms are attributed to rituximab: antibody-dependent cellular cytotoxicity (ADCC) through recruitment of effectors cells via their Fc $\gamma$  receptor, complement dependent cytotoxicity (CDC) by activating the classical pathway; and direct apoptosis (Renaudineau *et al* 2009). In turn, B cells may escape rituximab activity through different mechanisms including Fc $\gamma$ RIIIA 158-Phe/Phe polymorphism affecting ADCC, an abnormal clearance of the monoclonal antibody (mAb), the presence of human chimeric antibodies (HACA) that recognize the murine component of rituximab, or modulation of the CD20 molecule at the cell surface. Different mechanisms have been reported leading to the loss of CD20 molecule at the cell surface: “shaving”, as described in B-cell chronic lymphocytic leukemia and mantle cell lymphoma (Beum *et al* 2011), expression of an alternative splicing variant that down regulate cell surface expression (Beum *et al* 2006), defect in transcription factors (Henry *et al* 2010) and an epigenetic control of the promoter (Mankai *et al* 2008). Due to the very mechanism of action of rituximab, a transient loss of CD20 expression in chronic lymphocytic leukemia immediately after rituximab infusion has been described, but CD20 B cells quickly re-appear in the bloodstream (Kennedy *et al* 2004).

It has been demonstrated that the “shaving” process occurs when target cell populations become saturated and exhausted after repeated or increased doses of anti-CD20 mAbs. Under such conditions, the activatory Fc $\gamma$  receptor, rather than mediating phagocytosis of the target cells, can rip a fragment of the target cell membrane including the target antibody, stripping the cell of the mAb and antigen (Beum *et al* 2011). As far as we know,

no other causes or risk factors for CD20 “shaving” than cell saturation and exhaustion have been identified.

In relapsed prior responders to rituximab monotherapy with indolent lymphomas, the response rate at re-treatment with the same agent seems to be lower than 50%, and one explanation of this phenomenon may be the loss of CD20 expression (Duman *et al* 2012). It is well known that rituximab improves outcome in patients with most B cell lymphomas when co-administered with chemotherapy. Thus, it is presumable that the loss of response to rituximab would worsen treatment outcome in these patients, as compared to patients that preserve CD20 expression at relapse, even if relevant studies are lacking.

In our heavily rituximab-pretreated patient, either alone or in combination with chemotherapy, we observed the disappearance of CD20 at the cell surface of cells. The patient was Fc $\gamma$ RIIIA 158-Val/Phe, its pharmacokinetic was normal and no HACA were detected, thus excluding an alteration of the ADCC or antibody metabolism. The tissue architecture and other cell markers were identical to those at the time of diagnosis.

Our finding re-emphasizes that patients relapsing after rituximab should be re-tested for CD20 expression in order to adapt therapy, because further administration of rituximab may not be warranted. Despite disappearance of CD20 at the surface of target cells being reported in chronic lymphocytic leukemia even since the advent of rituximab, re-biopsy or re-testing for CD20 positivity is not a common, ubiquitous practice even in the present. For this small fraction of patients, several ways to reduce shaving or to up-regulate CD20 expression may prove to be of interest in the future (Beum *et al* 2006; Hiraga *et al* 2009; Mankai *et al* 2009). Regardless of the mechanism involved in the disappearance of CD20 expression on target cells, the most important practical consequence we are aiming to highlight, is adapting treatment strategies such as to exclude rituximab and novel CD20 targeting mAbs like ofatumumab and, more recently, obinutuzumab, thus sparing the patient the added risk of this immunotherapy, and reducing significant costs associated with these agents.

## Acknowledgement

The authors acknowledge financial support from POSDRU grant no. 159/1.5/138776 titled: “Model colaborativ institutional pentru

translatarea cercetarii stiintifice biomedicale in practica clinica” (Dr. Urian), Romanian National Authority for Scientific Research, CNCS - UEFISCDI (project number PN-II-RU-PD-2011-3-0277) (Dr Zdrenghea and Bagacean), and grant 1494 /2014 from the University of Medicine and Pharmacy Cluj (Dr. Zdrenghea).

## References

- A clinical evaluation of the International Lymphoma Study Group classification of non-Hodgkin’s lymphoma. The Non-Hodgkin’s Lymphoma Classification Project. *Blood* 1997;89(11):3909-3918.
- Beum PV, Kennedy AD, Williams ME, Lindorfer MA, Taylor RP. The shaving reaction: rituximab/CD20 complexes are removed from mantle cell lymphoma and chronic lymphocytic leukemia cells by THP-1 monocytes. *J Immunol* 2006;176(4):2600-2609. doi: 176/4/2600
- Beum PV, Peek EM, Lindorfer MA, Beurskens FJ, Engelberts PJ, Parren PW, van de Winkel JG, Taylor RP. Loss of CD20 and bound CD20 antibody from opsonized B cells occurs more rapidly because of trogocytosis mediated by Fc receptor-expressing effector cells than direct internalization by the B cells. *J Immunol* 2011;187(6):3438-3447. doi: 10.4049/jimmunol.1101189
- Duman BB, Sahin B, Ergin M, Guvenc B. Loss of CD20 antigen expression after rituximab therapy of CD20 positive B cell lymphoma (diffuse large B cell extranodal marginal zone lymphoma combination): a case report and review of the literature. *Med Oncol* 2012;29(2):1223-1226. doi: 10.1007/s12032-011-9955-3
- Henry C, Deschamps M, Rohrlich PS, Pallandre JR, Remy-Martin JP, Callanan M, et al. Identification of an alternative CD20 transcript variant in B-cell malignancies coding for a novel protein associated to rituximab resistance. *Blood* 2010;115(12):2420-2429. doi: 10.1182/blood-2009-06-229112
- Hiraga J, Tomita A, Sugimoto T, Shimada K, Ito M, Nakamura S, et al. Down-regulation of CD20 expression in B-cell lymphoma cells after treatment with rituximab-containing combination chemotherapies: its prevalence and clinical significance. *Blood* 2009;113(20):4885-4893. doi: 10.1182/blood-2008-08-175208
- Kennedy AD, Beum PV, Solga MD, DiLillo DJ, Lindorfer MA, Hess CE, Densmore JJ, Williams ME, Taylor RP. “Rituximab infusion promotes rapid complement depletion and acute CD20 loss in chronic lymphocytic leukemia.” *J Immunol* 2004;172(5):3280-3288.
- Mankai A, Bordron A, Renaudineau Y, Martins-Carvalho C, Takahashi S, Ghedira I, et al. Purine-rich box-1-mediated reduced expression of CD20 alters rituximab-induced lysis of chronic lymphocytic leukemia B cells. *Cancer Res* 2008;68(18):7512-7519. doi: 10.1158/0008-5472.CAN-07-6446
- Mankai A, Buhe V, Hammadi M, Youinou P, Ghedira I, Berthou C, et al. Improvement of rituximab efficiency in chronic lymphocytic leukemia by CpG-mediated upregulation of CD20 expression independently of PU.1. *Ann N Y Acad Sci* 2009;1173:721-728. doi: 10.1111/j.1749-6632.2009.04614.x
- Renaudineau Y, Devauchelle-Pensec V, Hanrotel C, Pers JO, Saraux A, Youinou P. Monoclonal anti-CD20 antibodies: mechanisms of action and monitoring of biological effects. *Joint Bone Spine* 2009;76(5):458-463. doi: 10.1016/j.jbspin.2009.03.010
- Vidal L, Gafter-Gvili A, Leibovici L, Dreyling M, Ghilmini M, Hsu Schmitz SF, et al. Rituximab maintenance for the treatment of patients with follicular lymphoma: systematic review and meta-analysis of randomized trials. *J Natl Cancer Inst* 2009;101(4):248-255. doi: 10.1093/jnci/djn478

## Authors

- Cristina Bagacean, “Iuliu Hatieganu” University of Medicine and Pharmacy, 8 Babes Street, 400012, Cluj-Napoca, Romania, “Prof. Dr. Ion Chiricuta” Institute of Oncology, 34-36 Republicii Street, 400015 Cluj-Napoca, Romania, e-mail: bagacean.cristina@umfcluj.ro
- Isabelle Quintin-Roue, Laboratory of Pathoanatomy, Brest University Medical School, 2 Avenue Maréchal Foch, 29200 Brest, France, e-mail: isabelle.quintin-roue@chu-brest.fr
- Jean-Christophe Ianotto, Hematology Department, Institute of Cancerology and Haematology, 2 Avenue Maréchal Foch, 29200 Brest, France, e-mail: jean-christophe.ianotto@chu-brest.fr
- Yves Reneaudineau, Research Unit INSERM ESPRI, ERI29/EA2216 Immunotherapy and B Cell Diseases, Réseau épigénétique et Réseau canaux ioniques du Cancéropôle Grand Ouest, Labex IGO, European University of Brittany, 2 Avenue Maréchal Foch, 29200 Brest, France, e-mail: yves.renaudineau@univ-brest.fr
- Adrian Tempescul, Hematology Department, Institute of Cancerology and Haematology, 2 Avenue Maréchal Foch, 29200 Brest, France, e-mail: adrian.tempescul@chu-brest.fr
- Doinel Radeanu, “Iuliu Hatieganu” University of Medicine and Pharmacy, 8 Babes Street, 400012, Cluj-Napoca, Romania, e-mail: doinelra@yahoo.com
- Adriana Muresan, “Iuliu Hatieganu” University of Medicine and Pharmacy, 8 Babes Street, 400012, Cluj-Napoca, Romania, e-mail : muresanadriana@yahoo.com
- Mihnea Zdrenghea, “Iuliu Hatieganu” University of Medicine and Pharmacy, 8 Babes Street, 400012, Cluj-Napoca, Romania, “Prof. Dr. Ion Chiricuta” Institute of Oncology, 34-36 Republicii Street, 400015 Cluj-Napoca, Romania, e-mail: mzdrenghea@umfcluj.ro

**Citation** Bagacean C, Quintin-Roue I, Ianotto JC, Renaudineau Y, Tempescul A, Radeanu D, Muresan A, Zdrenghea M. CD20 negative relapse of a follicular lymphoma after chemoimmunotherapy. *HVM Bioflux* 2015;7(4):302-305.

**Editor** Ștefan C. Vesa

**Received** 30 August 2015

**Accepted** 23 September 2015

**Published Online** 26 September 2015

**Funding** POSDRU grant no. 159/1.5/138776 titled: "Model colaborativ institutional pentru translatarea cercetarii stiintifice biomedicale in practica clinica", Romanian National Authority for Scientific Research, CNCS - UEFISCDI (project number PN-II-RU-PD-2011-3-0277), and grant 1494 /2014 from the University of Medicine and Pharmacy Cluj

**Conflicts/  
Competing  
Interests** None reported