

# A case report of recurrent respiratory papillomatosis progressed into a loco-regionally advanced laryngeal carcinoma

Cristina Țiple, Magdalena Chirilă, Florina V. Dinescu, Marcel Cosgarea

<sup>1</sup> Department of Otorhinolaryngology, “Iuliu Hatieganu” University of Medicine and Pharmacy, Cluj-Napoca, Romania.

**Abstract.** In this article, we present the clinical course of a patient who had more than 30 operations for recurrent laryngeal papillomatosis associated with HPV type 11 infection, and who was diagnosed with a laryngeal squamous cell carcinoma at the age of 34 years. Other risk factors such as smoking or hereditary tendency to malignant tumors were associated in this case. It is known that Recurrent respiratory papillomatosis (RRP) has the potential to suffer malignant transformation. The risk of cancer must be considered in all cases of laryngeal papillomatosis, requiring special attention especially in cases with multiple relapses.

**Key Words:** recurrent respiratory papillomatosis, malignant transformation, human papilloma virus.

**Copyright:** This is an open-access article distributed under the terms of the Creative Commons Attribution License, which permits unrestricted use, distribution, and reproduction in any medium, provided the original author and source are credited.

**Corresponding Author:** F. V. Dinescu, e-mail: eu\_vera@yahoo.com.

## Introduction

Recurrent respiratory papillomatosis (RRP) is a rare condition caused solely by human papilloma virus (HPV) and is characterized by recurrent growth of papillomas in the respiratory tract (Katsenos & Becker 2011). RRP occurs in both children and adults, and manifests most often in children younger than five years, corresponding to juvenile-onset or in persons in the fourth decade of life (adult-onset). Juvenile onset recurrent respiratory papillomatosis (JORRP) is a rare type of HPV infection (Mauz et al 2014). Laryngeal papillomatosis is caused by common low-risk HPV types 6 and 11, and high-risk HPV types 16 and 18 frequently present in malignant lesions (Torrente et al 2011; Reidy et al 2004). Although HPV types 6 and 11 are low risk HPV types, are capable to determine malignancy in adult type (Vambutas et al 1993). The HPV type-11 are characterized by more aggressive disease, which require more surgical intervention, frequently tracheotomy, malignant transformation, and higher mortality (Gerein al 2005). The molecular mechanisms in the carcinogenesis of low risk HPV-associated cancers are still unknown until to date (Huebbers et al 2013). The management of this entity still remains challenging since no specific definitive treatment exists.

## Case report

The patient was a 34 old male, diagnosed with laryngeal papillomatosis at the age of three. Written informed consent was obtained from the patient for publication of this case report and any accompanying images. Between the ages of three and twenty, multiple interventions were necessary and were followed by a stable phase for approximately 13 years. HPV typing by multiplex

polymerase chain reaction (PCR) detected HPV type 11. The patient had never been treated with adjuvant therapies available for this disease: quadrivalent HPV (types 6/11/16/18), Cidofovir or other adjuvant therapies. Patient smoked one pack a day for 16 years. Mother's patient died of larynx cancer ten years ago. At the age of 34 years, the patient returns for recurrence of dysphonia. An endoscopy revealed large papillomas growth in the glottic area. The neck CT-scan with contrast agent showed a large mass at the right true vocal cord, extended to the right Morgagni ventricle, right false vocal cord, right arytenoid, subglottic level and to the paraglottic space (Fig. 1).

A larynx biopsy was performed. The histopathological examination showed the transformation to squamous cell carcinoma. The classification for malignant tumor was T4aN0M0. The patient received 3 cycles x TPF (drugs in the Cisplatin-Taxotere-5 Fluorouracil combination) induction chemotherapy, according to the Oncologic Committee's decision, and a partial remission of tumor was obtained. The assessment was made in the third week after the third cycle of chemotherapy through the endoscopy examination and neck CT-scan with contrast agent (Fig. 2). After one months from chemotherapy, the patient was submitted to total laryngectomy with total thyroidectomy and bilateral selective neck dissection, at the Ear, Nose and Throat Department of the Emergency County Hospital of Cluj-Napoca, in May 2014. Voice restorations was obtained with Traheoesophageal voice prosthesis (TEP). Postoperative the patient was submitted to adjuvant radiotherapy (dose of 60 Gy). Presently, at one year after total laryngectomy the disease remains stable without recurrence. Postoperative follow up is made by clinical examination and neck CT-scan. The patient is well and has resumed normal daily activities. Patient no longer smokes.

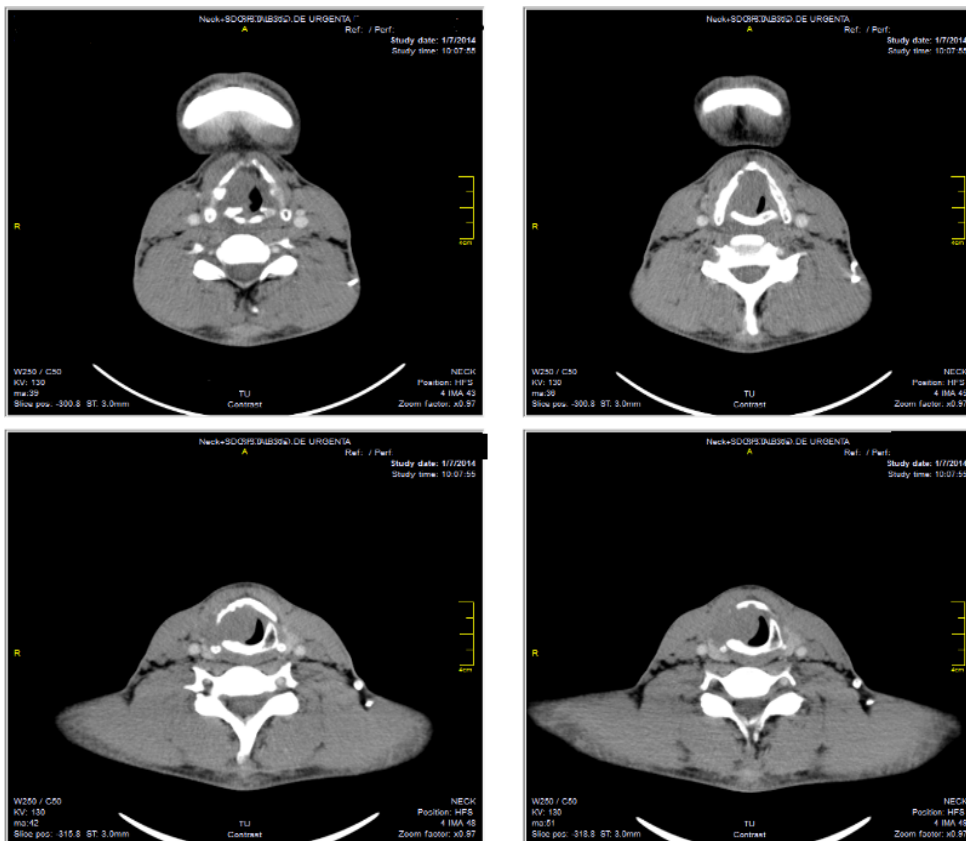


Fig 1. The neck CT-scan images with contrast before treatment illustrating the bulky tumor at the right true vocal cord, the right Morgagni ventricle, right false vocal cord, right arytenoid, extended to the subglottic level and to the paraglottic space

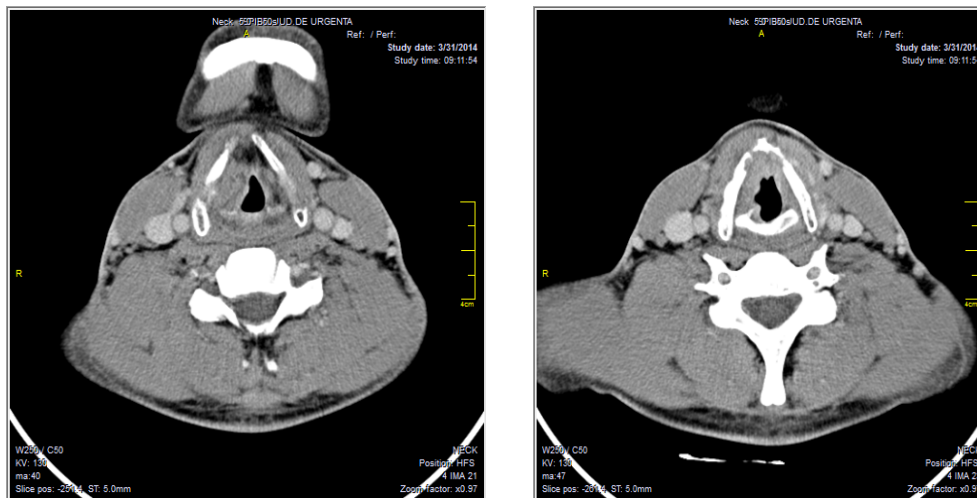


Fig. 2. The neck CT -scan images show a partial remission of the tumor after chemotherapy,the tumor involving the right true vocal cord , right false vocal cord with subglottic extension

## Discussion

JORRP is a rare disease which is usually diagnosed in early childhood (Mauz et al 2014). We report a case with juvenile onset type laryngeal papillomatosis with HPV type 11 infection, with multiple surgeries and malignant transformation, who was submitted to total laryngectomy at the age of 34 years. Age at onset of the RRP is a well-known factor in estimating aggressiveness and severity of the disease (Izadi et al 2012). The juvenile onset is considered to be more aggressive than the adult type, but severe cases of RRP can appear in adults (Leung et al 2007; Goon et al 2008). According to Izadi et al younger patients and with HPV-11 seemed to have more severe problems, but these

findings did not achieve statistical significance (Izadi et al 2012). Also, Wiatriak and colleagues showed that younger age at diagnosis is associated with a more aggressive disease and the need for more frequent surgical procedures (DerKay&Wiatriak 2008). The evolution of laryngeal papillomatosis is generally unpredictable. Despite its mostly benign nature, RRP may undergo malignant transformation to squamous cell carcinoma. Badaracco et al (2000) investigated the association of HPV infection to head and neck carcinomas and the results showed that HPV infection may be associated to a proportion of head and neck carcinomas but its association is not as obvious as that found in cervical cancer. Syrjänen (2005 ) also indicate that the role of HPV in laryngeal carcinomatosis remains controversial.

No specific treatment has been shown to be efficient in eradicating RRP and all surgical and adjuvant therapies serve only to reduce the severity of the illness, eliminating the primary source of disease would be of great benefit (Hoff&Koltai 2012). Chirila&Bolboaca (2014) showed on a short series of cases that the quadrivalent HPV (types 6/11/16/18) vaccine and intralesional administration of Cidofovir had a good results and was efficient in the treatment of our patients with RRP. Hočevar-Boltežar et al reinforced these findings providing conclusions of a 5-years follow-up study on anti-HPV vaccination (2014). In our case report the patient had never been treated with adjuvant therapies. According to other studies, benefits of adjuvant therapies including local injection of Cidofovir in aggressive cases of RRP have been reported in both children and adults (Durvasula&Richter 2013; Clamp&Saunders 2013; Chadha&James 2012 ). The good results with the reduced of the aggressiveness of the disease after adjuvant therapies have been described in several studies (Aaltonen et al 2002).

Because the patient was a smoker we raised the question: does the smoking associated with HPV play a role in malignant transformation of the RRP? It is known that tobacco and alcohol abuse are the most important risk factors for laryngeal squamous cell carcinoma (LSCC); however, molecular evidence has supported a role for HPV, particularly HPV-16, in the pathogenesis of LSCC (Kreimer et al 2005). Smoking may independently leading to malignant transformation, or facilitate viral integration in DNA damaged areas of the genome (Huebbers et al 2013). On the other hand, Applebaum et al (2007) found that smoking and drinking was not associated with the risk of head and neck squamous cell carcinoma among those whose blood tested positive for HPV16 . Also, Rehberg&Kleinsasser (1999), concluded that the role of smoking as a co-factor in the development of carcinoma ex-papilloma is still not clear. Hereditary tendency to malignant tumors were present in this case. Patient's mother died of larynx cancer. Several studies have been published in which most have noticed that HPV type 11 is related with a more aggressive course. Based on the findings presented until now in all the studies, it seems that an infection by the 'low risk' HPV types 11 no means excludes the possibility of developing a laryngeal carcinoma, until now assigned to the 'high risk' type HPV-16 only. As well as in the study of Lindeberg et al (1989) the present case report support for the role of HPV as an etiological agent in laryngeal squamous cell carcinoma, most probably acting synergistically with carcinogens (smoking, and hereditary tendency to malignant tumors).

## Conclusion

The risk of malignant transformation must be considered in all cases of laryngeal papillomatosis, need special attention in particular cases with numerous interventions.

## Acknowledgments

This paper was published under the frame of European Social Fund, Human Resources Development Operational Programme 2007-2013, project no. POSDRU/159/1.5/S/138776.

## References

- Aaltonen LM, Rihkanen H, Vaheri A (2002) Human papilloma virus in larynx. *Laryngoscope* 112(4):700–707.
- Applebaum KM, Furniss CS, Zeka A, Posner MR, Smith JF, Bryan J, et al. Lack of association of alcohol and tobacco with HPV16-associated head and neck cancer. *J Natl Cancer Inst* 2007;99(23):1801-10.
- Badaracco G, Venuti A, Morello R, Muller A, Marcante ML. Human papillomavirus in head and neck carcinomas: prevalence, physical status and relationship with clinical/pathological parameters. *Anticancer Res* 2000;20(2B):1301-5.
- Chadha NK, James A. Adjuvant antiviral therapy for recurrent respiratory papillomatosis. *Cochrane Database Syst Rev* 2012; 12:CD005053.
- Chirilă M, Bolboacă SD. Clinical efficiency of quadrivalent HPV (types 6/11/16/18) vaccine in patients with recurrent respiratory papillomatosis. *Eur Arch Otorhinolaryngol* 2014;271(5):1135-42.
- Clamp PJ, Saunders MW. Systematic review of intralesional Cidofovir dosing regimens in the treatment of recurrent respiratory papillomatosis. *Int J Pediatr Otorhinolaryngol* 2013;77(3):323-8.
- Derkey CS, Wiatrak B. Recurrent respiratory papillomatosis: a review. *Laryngoscope* 2008;118(7):1236-47.
- Durvasula VS and Richter GT. Intralesional Cidofovir as adjuvant for the successful management of aggressive respiratory papillomatosis in an infant. *Int J Pediatr Otorhinolaryngol* 2013;77 (11):1912-5.
- Gerein V, Rastorguev E, Gerein J, Draf W, Schirren J. Incidence, age at onset, and potential reasons of malignant transformation in recurrent respiratory papillomatosis patients: 20 years' experience. *Otolaryngol Head Neck Surg* 2005;132(3):392-4.
- Goon P, Sonnex C, Jani P, Stanley M, Sudhoff H. Recurrent respiratory papillomatosis: an overview of current thinking and treatment. *Eur Arch Otorhinolaryngol* 2008;265:147–151.
- Hočevar-Boltežar I, Matičič M, Sereg-Bahar M, Gale N, Poljak M, Kocjan B, Zargi M. Human papilloma virus vaccination in patients with an aggressive course of recurrent respiratory papillomatosis. *Eur Arch Otorhinolaryngol* 2014;271(12):3255-62.
- Hoff SR, Koltai PJ. Operative management of juvenile-onset recurrent respiratory papillomatosis. *Oper Tech Otolaryngol* 2012;23:117–123.
- Huebbers CU, Preuss SF, Kolligs J, Vent J, Stenner M, Wieland U, et al. Integration of HPV6 and Downregulation of AKR1C3 Expression Mark Malignant Transformation in a Patient with Juvenile-Onset Laryngeal Papillomatosis. *PLoS One* 2013;8(2):e57207.
- Izadi F, Hamkar R, Ghanbari H, Abdolmotallebi F, Jahandideh H. The role of Human papilloma virus (HPV) genotyping in recurrent respiratory papillomatosis in Rasoul Akram Hospital. *Med J Islam Repub Iran* 2012;26(2):90-3.
- Katsenos S and Becker HD. Recurrent Respiratory Papillomatosis: A Rare Chronic Disease, Difficult to Treat, with Potential to Lung Cancer Transformation: Apropos of Two Cases and a Brief Literature Review. *Case Rep Oncol* 2011;4(1):162-71.
- Kreimer AR, Clifford GM, Boyle P, Franceschi S. Review Human papillomavirus types in head and neck squamous cell carcinomas worldwide: a systematic review. *Cancer Epidemiol Biomarkers Prev* 2005;14(2):467-75.
- Leung R, Hawkes M, Campisi P. Severity of juvenile onset recurrent respiratory papillomatosis is not associated with socioeconomic status in a setting of universal healthcare. *Int J Pediatr Otorhinolaryngol* 2007;71:965–972.
- Lindeberg H, Syrjänen S, Kärjä J, Syrjänen K. Human papillomavirus type 11 DNA in squamous cell carcinomas and pre-existing multiple laryngeal papillomas *Acta Otolaryngol* 1989;107(1-2):141-9.

Mauz PS, Zago M, Kurth R, Pawlita M, Holderried M, Thiericke J, et al. A case of recurrent respiratory papillomatosis with malignant transformation, HPV11 DNAemia, high L1 antibody titre and a fatal papillary endocardial lesion. *Virology* 2014;11:114.

Rehberg E, Kleinsasser O. Malignant transformation in non-irradiated juvenile laryngeal papillomatosis. *Eur Arch Otorhinolaryngol* 1999;256(9):450-4.

Reidy PM, Dedo HH, Rabah R, Field JB, Mathog RH, Gregoire L, Lancaster WD. Integration of human papillomavirus type 11 in recurrent respiratory papilloma-associated cancer. *Laryngoscope* 2004;114(11):1906-9.

Syrjänen S. Human papillomavirus (HPV) in head and neck cancer. *J Clin Virol* 2005;32(Suppl 1):S59-66.

Torrente MC, Rodrigo JP, Haigentz M Jr, Dikkers FG, Ronaldo A, Takes RP, Olofsson J, Ferlito A. Human papillomavirus infections in laryngeal cancer. *Head Neck* 2011;33(4):581-6.

Vambutas A, DiLorenzo TP, Steinberg BM. Laryngeal papilloma cells have high levels of epidermal growth factor receptor and respond to epidermal growth factor by a decrease in epithelial differentiation. *Cancer Res* 1993;53:910-914.

## Authors

Cristina Țiple, Department of Otorhinolaryngology, “Iuliu Hatieganu” University of Medicine and Pharmacy, 8 Victor Babes Street 400012, Cluj-Napoca, Cluj, Romania, EU, email:cristinatiple@yahoo.com

Magdalena Chirilă, Department of Otorhinolaryngology, “Iuliu Hatieganu” University of Medicine and Pharmacy, 8 Victor Babes Street 400012, Cluj-Napoca, Cluj, Romania, EU, email:chirila\_magda@yahoo.com

Florina V. Dinescu, Department of Otorhinolaryngology, “Iuliu Hatieganu” University of Medicine and Pharmacy, 8 Victor Babes Street 400012, Cluj-Napoca, Cluj, Romania, EU, email:eu\_vera@yahoo.com

Marcel Cosgarea, Department of Otorhinolaryngology, “Iuliu Hatieganu” University of Medicine and Pharmacy, 8 Victor Babes Street 400012, Cluj-Napoca, Cluj, Romania, EU, email:rcosgarea@yahoo.com

<b>Citation</b>	Țiple C, Chirilă M, Dinescu FV, Cosgarea M. A case report of recurrent respiratory papillomatosis progressed into a loco-regionally advanced laryngeal carcinoma. <i>HVM Bioflux</i> 2015;7(4):260-263.
<b>Editor</b>	Ștefan C. Vesa
<b>Received</b>	17 August 2015
<b>Accepted</b>	29 August 2015
<b>Published Online</b>	31 August 2015
<b>Funding</b>	European Social Fund, Human Resources Development Operational Programme 2007-2013, project no. POSDRU/159/1.5/S/138776
<b>Conflicts/ Competing Interests</b>	None reported