

Respiratory chondromesenchymal hamartoma: case reports and literature review

Florina-V. Dinescu, Magdalena Chirilă, Cristina Țiple, Marcel Cosgarea

¹ Department of Otorhinolaryngology, “Iuliu Hatieganu” University of Medicine and Pharmacy, Cluj-Napoca, Romania.

Abstract. We report 2 cases of respiratory chondromesenchymal hamartoma (RCMH), rare, benign lesion, in 2 adult females. In Case 1 we had a 67 years-old woman and in Case 2 an 18 years-old woman. RCMH usually occurs in younger patients and more frequently in boys. In Case 1, the patient complained of chronic bilateral obstruction, posterior rhinorrhea and hyposmia. The tumor was located in nasal septum and it extended to the sphenoid sinus. In Case 2, she accused intermittent right hearing loss, and the lesion was in nasopharynx. Both cases underwent surgery. The procedure was conducted endonasally and endoscopically under a general anesthesia and the mass was removed. The post-operative period was uneventful. The certain diagnosis was histopathologic. After the surgery, there were no signs of recurrence, at 6 months for Case 1 and one year for Case 2.

Key Words: chondromesenchymal hamartoma, case report.

Copyright: This is an open-access article distributed under the terms of the Creative Commons Attribution License, which permits unrestricted use, distribution, and reproduction in any medium, provided the original author and source are credited.

Corresponding Author: C. Țiple, e-mail: cristinatiple@yahoo.com

Introduction

Hamartomas are benign tumors, “defined as aberrant differentiation, which may produce a mass of disorganized but mature specialized cells or tissue indigenous to the particular site”, as it was shown by Fitzhugh et al (2008). Hamartomas tend to originate from the lung, kidney, liver, spleen and intestine according to the literature (Fitzhugh et al 2008; Mortuaire et al 2007; Marin et al 2013). They do not regress spontaneously. They do not have propensity for infiltration or metastasis (Eloy et al 2011). Nasal chondromesenchymal hamartoma (NCMH) was first described by McDermott in 1998, and presented seven cases that occurred mostly in very young children. Mezenchymal predominant hamartomas are poorly represented in literature, especially in nose and nasopharynx (Eloy et al 2011). NCMH may be extensive, locally destructive and extend into the intracranial space and it can be misdiagnosed as a cancer (Priest et al 2010). The challenge of this disease is the correct diagnosis and treatment by simple excision (Mattos et al 2011).

Case reports

Case 1

A 67-years-old woman from urban environment presented to Ear, Nose and Throat Department of the Emergency County Hospital of Cluj-Napoca in February 2015, with a 1 year history of progressive nasal bilateral obstruction, posterior rhinorrhea and hyposmia. The patient was also known to have had a history of appendectomy, duodenal ulcer surgery, classic cholecystectomy, kidney stones surgery, total hysterectomy, acute pancreatitis and hepatitis C.

The nasal endoscopy revealed an irregular mass located in the posterior region of the nasal septum. The consistency of the mass

was solid (figure 1). The magnetic resonance imaging (MRI) of the nose and sinuses revealed a large heterogeneous tissue mass measuring 48 mm x 33 mm x 30 mm, located in 2/3 posterior part of left nasal fossa and with protrusion in left sphenoid sinus.

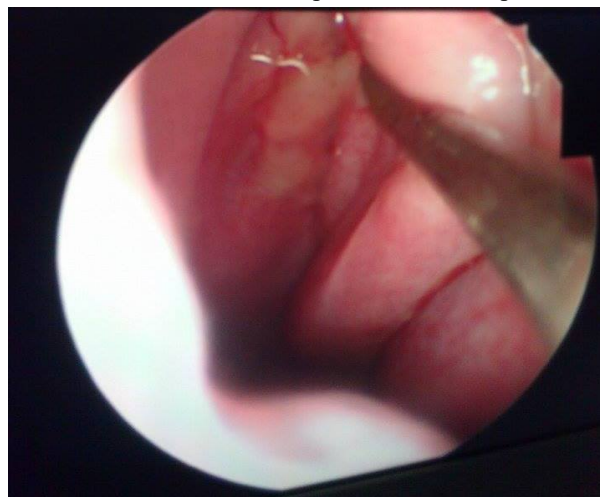


Fig. 1. Nasal endoscopy in Case 1: an irregular, whitish mass located in the 2/3 posterior part of the nasal septum

Differential diagnosis was made with inflammatory polyp, inverted papilloma and sinonasal adenocarcinoma to avoid an overly aggressive treatment. The certain diagnosis was made by histopathology of the specimen.

The patient underwent surgery. The procedure was conducted endonasally and endoscopically under a general anesthesia with atropine, Dormicum, dexamethasone, fentanyl, propofol, etomidate, Tracrium, Sevorane and Miofilin, and the surgery lasted 45 minutes. The mass was progressively dissected from

the 2/3 posterior part of the nasal septum and the left sphenoid sinus till the bony part. The patient presented chronic infection in left sphenoid sinus (figure 2). The postoperative period was uneventful. On histopathologic examination the tumour had nasal and sinus mucosa, subjacent stroma with mixed moderate inflammatory and mature cartilage islands in lobules architecture, surrounded by rare spindle cells without atypia, which alternates with myxoid areas; no atypical or malignant elements. We diagnosed the mass as NCMH (figure 3). At the 6th month examination there were no signs of recurrence.

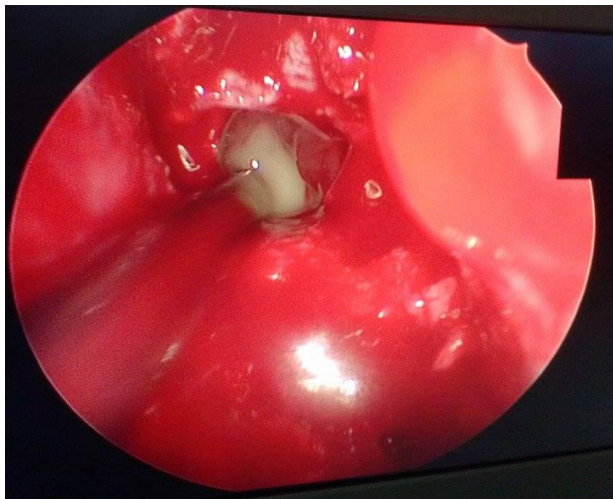
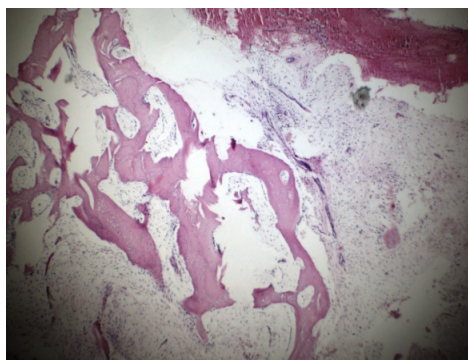
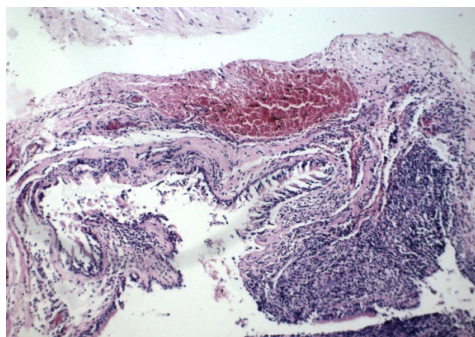


Fig. 2. Intraoperative nasal endoscopy in Case 2: the left sphenoid sinus with pus and whitish mass in left nasal fossa



a. Mature lobular cartilage island which are surrounded by spindle cells and hematic infiltrate.



b. Pseudostratified epithelium, ulcerated and subjacent stroma with mixed moderate inflammatory cells.

Fig. 3. Microscopic appearance of nasal chondromesenchymal hamartoma (hematoxylin and eosin stain, x10)

Case 2

A 18 years-old woman from urban environment came to Ear, Nose and Throat Department of the Emergency County Hospital of Cluj-Napoca in November 2010 because the endocrinologist has discovered a right nasopharynx mass upon having a MRI for a non-secreting pituitary adenoma. The patient had intermittent right hearing loss. The patient was diagnosed with non secreting pituitary adenoma, 3 months before the presentation in our service.

Endoscopic examination revealed a pediculate mass, covered with normal mucosa situated in nasopharynx (anterior pillar of the Eustachian tube). The consistency of the mass was solid (figure 4).

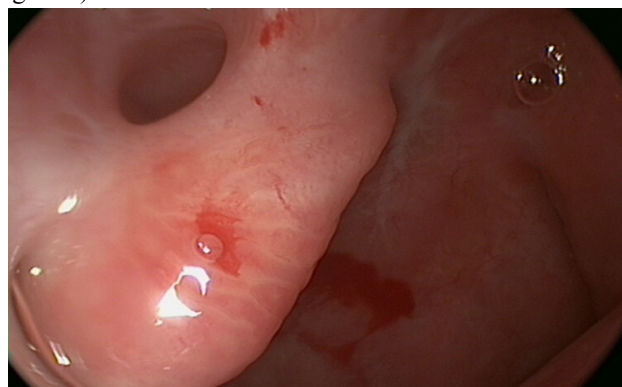


Fig. 4. Endoscopic examination in Case 2: a pediculate mass, covered with normal mucosa situated in nasopharynx (anterior pillar of the Eustachian tube)

The MRI described a mass as a “bridge” on anterior pillar of the Eustachian tube, without any other changes of the nasopharynx. Surgery was performed. The procedure was under general anesthesia with atropine, Midazolam, fentanyl, etomidate, Tracrium, dexamethasone, Sevoflurane, and the surgery lasted 15 minutes. Complete excision through nasal endoscopy was performed. The specimen underwent histological analysis. On histopathologic examination the tumour had nasopharyngeal mucosa, covered by epithelial respirator tissue with edema or chorionic fibrosis and numerous sero-mucous glands; there were focal erosions and ulceration of the epithelium, areas of hemorrhage and moderate rotundonuclear infiltrated; there were also myxoid and condroid tissue fragments, unicellular chondrocytes, dispersed non-atypical. We diagnosed the mass as nasopharynx chondromesenchymal hamartoma. There were no complications during the operation and postoperative period. At 1 year examination there were no signs of recurrence (figure 5).

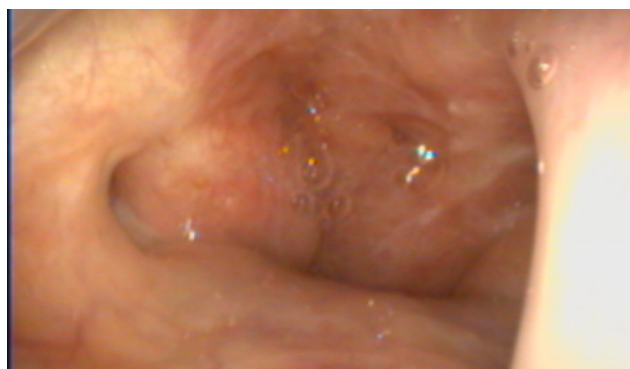

Fig. 5. Endoscopic view in Case 2 at 1 year examination: no signs of recurrence

Both patients were informed about the confidentiality of shared information, and they were requested to sign an official consent form.

Discussion

The term “hamartoma” was introduced by Albrecht in 1904 to distinguish true neoplasm and tumor-like lesion (Albrecht, 1904). This term is now used to describe a focal exaggerated increase of mature and normal cells and tissues. Hamartoma can occur in any organ (Hua et al 2014).

NCMH is a very rare, benign tumor that develops from sino-nasal tract. Because it is locally aggressive and destructive, her appearance may suggest a malignant tumor. In 2013, Li et al described the first case of malignant transformation. Because there are few cases reported in literature, there is no evidence that NCMH can degenerate malignant. NCMH is associated with pleuropulmonary blastoma (PPB), although little is known about the pathogenesis of the disease (Obidan 2014). Because of their predilection for early onset, a genetic predisposition it's possible. However, NCMH can occur in older children, adolescents, adults and elderly patients, and some investigators propose as the etiology of this disease to be the chronic inflammatory process (Mattos 2011). In both our cases the patients did not have any family history of NCMH and Case 1 had chronic inflammatory process in left sphenoid sinus.

Mason et al (2015) found 48 NCMH patients in the English literature. Most cases were male, with male to female ratio of 2.2:1. The mean age was 9.6, and they found 8 adult patients. Condromezenchymal hamartoma can be found in the nasal cavity, paranasal sinuses, nasopharynx and oropharynx and can extend to the orbit, skull base and intracranial (Mason and al 2015). They found only 3 cases of condromezenchymal hamartoma in the nasopharynx.

The clinical manifestations depend on the location and size of the lesion (Eloy et al 2011). The symptoms can include: nasal obstruction, recurrent sinusitis, rhinorrhea, hyposmia, epistaxis, otitis media, eye signs, facial swelling and headaches or facial pain (Eloy et al 2011; Priest et al 2010; Mattos et al 2011; Hua et al 2014; Li et al 2013; Mason and al 2015). In Case 1 she complained of chronic bilateral obstruction, posterior rhinorrhea and hyposmia, and in Case 2 only intermittent right hearing loss. Histologically NCMH are composed of island of a proliferation of mesenchymal cellular elements, such as spindle cells and mixoid stroma, and mature or immature cartilaginous elements, with areas of calcification (Eloy et al 2011; Priest et al 2010; Mattos et al 2011; Hua et al 2014; Li et al 2013; Mason et al 2015). In both cases we found the same result.

Pre-operative imaging of these lesions provide valuable information regarding involvement of adjacent structures. The computed tomography (CT) scan shows a large, heterogeneous mass lesion with typically chondroid calcification. MRI has the advantage of better characterization of soft tissues and to highlight better th tumor invasion in adjacent tissues, compared to CT (Eloy et al 2011; Mattos et al 2011; Mason and al 2015). In both cases the MRI helped us for surgical decision, but we did not have a preoperative suspicion of hamartoma.

Management of NCMH required complete resection to prevent recurrence. An incomplete resection can lead to recurrence and possibility of continued tumor growth (Eloy et al 2011; Priest et

al 2010; Mattos et al 2011; Hua et al 2014; Li et al 2013; Mason and al 2015). In our cases we did an endoscopic surgery. After 6 month in first case, and 1 year in second case we did not have signs of recurrence.

Conclusions

We reported 2 cases of respiratory chondromesenchymal hamartoma, rare, benign lesion, in 2 adult females. In Case 2 the mass was in the nasopharynx, which is extremely rare. In both our cases the patients did not have any nasal, pulmonary or nasopharynx injury, and full endoscopic excision controlled disease. No adjuvant therapy was necessary.

Acknowledgments

This paper was published under the frame of European Social Fund, Human Resources Development Operational Programme 2007-2013, project no. POSDRU/159/1.5/S/138776.

References

- Albrecht E: Ueber hamartome. *Verh Dtsch Ges Pathol* 1904;7:153–157.
- Eloy P, Trigaux H, Nassogne MC, Weynand B, Rombaux P. Nasal chondromesenchymal hamartoma: Case report. *Int J Pediatr Otorhinolaryngol* 2011;6(4):300–303.
- Fitzhugh VA, Mirani N. Respiratory Epithelial Adenomatoid Hamartoma: A Review. *Head and Neck Pathol* 2008;2:203–208.
- Hua X, Huang X, Liao Z, Xian Q, Yu L. Clinicopathological and EBV analysis of respiratory epithelial adenomatoid hamartoma. *Diagnostic Pathology* 2014;9:70.
- Li Y, Yang QX, Tian XT, Li B, Li Z. Malignant transformation of nasal chondromesenchymal hamartoma in adult: a case report and review of the literature. *Histol Histopathol* 2013;28(3):337–44.
- Marin LG, Trombitas V, Albu S. A Case of Respiratory Epithelial Adenomatoid Hamartoma. *Chirurgia* 2013;108(6):904–906.
- Mason KA, Navaratnam A, Theodorakopoulou E, Chokkalingam PG. Nasal Chondromesenchymal Hamartoma (NCMH): a systematic review of the literature with a new case report, *J Otolaryngol Head Neck Surg* 2015;44:2.
- Mattos JL, Early SV. Nasal chondromesenchymal hamartoma: A case report and literature review, *Int J Pediatr Otorhinolaryngol* 2011;6(4):215–219.
- McDermott MB, Ponder TB, Dehner LP. Nasal chondromesenchymal hamartoma: an upper respiratory tract analogue of the chest wall mesenchymal hamartoma. *Am J Surg Pathol* 1998;22:425–433.
- Mortuaire G, Pasquesoone X, Leroy X, Chevalier D. Respiratory epithelial adenomatoid hamartomas of the sinonasal tract. *Eur Arch Otorhinolaryngol* 2007;264:451–453.
- Obidan AA, Ashoor MM. Nasal chondromesenchymal hamartoma in an adolescent with pleuropulmonary blastoma. *Saudi Med J* 2014;35(8):876–8.
- Priest JR, Williams GM, Mize WA, Dehner LP, McDermott MB. Nasal chondromesenchymal hamartoma in children with pleuropulmonary blastoma-A report from the International Pleuropulmonary Blastoma Registry. *Int J Pediatr Otorhinolaryngol* 2010;74(11):1240–1244.

Authors

- Florina-V. Dinescu, Department of Otorhinolaryngology, “Tuliu Hatieganu” University of Medicine and Pharmacy, 8 Victor

Babeş Street, 400012, Cluj-Napoca, Cluj, Romania, EU, email: veradinescu@gmail.com

•Magdalena Chirilă, Department of Otorhinolaryngology, “Iuliu Hatieganu” University of Medicine and Pharmacy, 8 Victor Babeş Street, 400012, Cluj-Napoca, Cluj, Romania, EU, email: magdalena.chirila@gmail.com

•Cristina Țiple, Department of Otorhinolaryngology, “Iuliu Hatieganu” University of Medicine and Pharmacy, 8 Victor

Babeş Street, 400012, Cluj-Napoca, Cluj, Romania, EU, email: cristinatiple@yahoo.com

•Marcel Cosgarea, Department of Otorhinolaryngology, “Iuliu Hatieganu” University of Medicine and Pharmacy, 8 Victor Babeş Street, 400012, Cluj-Napoca, Cluj, Romania, EU, email: rcosgarea@yahoo.com

Citation	Dinescu F-V, Chirilă M, Țiple C, Cosgarea M. Respiratory chondromesenchymal hamartoma: case reports and literature review. HVM Bioflux 2015;7(4):249-252.
Editor	Ștefan C. Vesa
Received	24 August 2015
Accepted	31 August 2015
Published Online	31 August 2015
Funding	European Social Fund, Human Resources Development Operational Programme 2007-2013, project no. POSDRU/159/1.5/S/138776.
Conflicts/ Competing Interests	None reported