

Mast-cell rich perivascular dermatitis accompanying the ulcerative lesions resulting from infection of *Staphylococcus aureus* in C57BL/6 mice

Tohru Kimura

Center for Experimental Animals, National Institutes of Natural Sciences, Nishigo-naka, Myodaiji, Okazaki, Aichi, Japan.

Abstract. The purpose of this study was to investigate the health status of mice and rats in our laboratory animal facilities. In addition, the author encountered sporadic cases of the ulcerative skin lesions, and then the dermatological lesions were evaluated for their macroscopic and microscopic changes. Health monitoring of specific pathogen free (SPF) and conventional animals (mice and rats) was accomplished in our laboratory center for years 2008 through 2011. Our results of rodent health monitoring programs showed that incidence of SPF rodents by *Staphylococcus aureus* (*S. aureus*) was higher than that of conventional rodents ($p < 0.01$). During the health monitoring program, severe ulcerative dermatitis was found in mice of the C57BL/6 strain. The lesions were characterized by full-thickness epidermal coagulation necrosis with extensive ulceration and marked inflammatory cell infiltration in the dermis. Infiltration of dermal mast cells apparently increased in the skin lesions. This study revealed that simplification of the intestinal normal flora caused colonization infection by *S. aureus* in SPF rodents. C57BL/6 mice were predisposed to severe ulcerative dermatitis infected with *S. aureus*. The ulcerative lesions suggested that mast cells should be critically involved in initiating and modulating optimal host responses to bacteria by either inflammatory or anti-inflammatory effects, depending on the course of the host reaction induced by the pathogen (*S. aureus*). This skin disease was diagnosed with mast-cell rich perivascular dermatitis accompanying the ulcerative lesions.

Key Words: *Staphylococcus aureus*, mast-cells, C57BL/6 mice, ulcerative dermatitis, specific pathogen free (SPF)

Copyright: This is an open-access article distributed under the terms of the Creative Commons Attribution License, which permits unrestricted use, distribution, and reproduction in any medium, provided the original author and source are credited.

Corresponding Author: T. Kimura, kimura@nips.ac.jp.

Introduction

C57BL/6 mice and strains on the C57BL/6 mice are uniquely susceptible to ulcerative dermatitis. Ulcerations are seen in the dorsal scapulae, torso, shoulder and facial sites. These lesions are accompanied by severe pruritis-induced self-trauma, progressing from super facial excoriations to deep ulcerations (Sundburg *et al* 1994; Kastenmayer *et al* 2006). Though the etiology of this ulcerative dermatitis is not clarified, investigators proposed multifactorial etiology such as immune-complex vasculitis (Sundburg *et al* 1994), primary follicular dystrophy (Sundberg *et al* 2011), strain-related behavioral manifestation (Garner *et al* 2004; Williams *et al* 2012) and development hair-induced oronasal inflammation (Duarte-Vogel *et al* 2011).

Health monitoring of SPF and conventional animals (mice and rats) was performed in our laboratory center. During this health monitoring program, it was occasionally encountered severe ulcerative dermatitis in C57BL/6 strain mice. It was found that the development of the unique skin lesions was closely associated with the opportunistic infection with *Staphylococcus aureus* (*S. aureus*).

The purpose of this study was to investigate the health status of mice and rats in our laboratory animal facilities [specific pathogen free (SPF) and conventional facilities]. The incidence of *S. aureus* was compared between SPF and conventional rodents.

In addition, severe ulcerative dermatitis in C57BL/6 strain mice was investigated for their macroscopic and microscopic changes.

Materials and Methods

Animals

Mice were housed in polycarbonate cages (W 17.0 × D 35.0 × H 14.0 cm) with bedding made from pure-pulp (Care-feeaz, Hamri Co., LTD., Ibaraki, Japan) in our specific-pathogen-free (SPF) barrier facilities. Rats were housed in Polysulfone cage (W21.5 × H13.3 × D32.3 cm, Seobit Co., Ltd, Tokyo) with wood shavings (Soft tips, Japan SLC Inc., Shizuoka, Japan). The number of mice reared in our facilities was as follows: 2500-4000 SPF mice and 2500-3000 conventional mice. The number of rats was as follows: 200-300 SPF rats and 100-200 conventional rats.

The animal room was maintained at constant temperature (23 ± 1°C) and relative humidity (55±10%). The room air was ventilated 10 to 15 times per hour automatically and 12 hr/12 hr light-dark cycle (lighting 06:00-18:00) was imposed. The SPF animals received commercial radiation sterilized diets (CE-2, Clea Japan Inc., Tokyo, Japan; CMF Spraut (specified diets for transgenic mice which are difficult to rear), Oriental Yeast Co. Ltd., Tokyo, Japan) and water *ad libitum*. These diets were previously sterilized by γ -irradiation at a dose of 30 kilograys (kGy).

Conventional animals were fed with unsterilized diets (CE-2, Clea Japan Inc., Tokyo, Japan) and given to water *ad libitum*. The health status of animals in our SPF and conventional facilities was checked four times a year for the pathogens listed by the Japanese Association of Laboratory Animal Facilities of National University Corporations, and animals were free from all these pathogens. Monitoring infectious agents of experimental rodents (SPF and conventional animals) were shown in Table 1. Health monitoring of SPF and conventional animals (mice and rats) was accomplished in our laboratory center for years 2008 through 2011.

In order to sampling, the following methods were used: the random sampling of individuals from the population and the sampling of sentinel mice capable of acquiring the unwanted infection.

Table 1. Monitoring infectious agents of experimental rodents

Mice	Rats
Mouse hepatitis virus	Sialodacryoadenitis virus (SDAV)
Sendai virus (HVJ)	Sendai virus (HVJ)
Ectromelia virus	Hanta virus
Lymphocytic choriomeningitis virus	
<i>Mycoplasma pulmonis</i>	<i>Mycoplasma pulmonis</i>
<i>Salmonella spp.</i>	<i>Salmonella spp.</i>
<i>Clostridium piliforme</i> (Tyzzer's organism)	<i>Clostridium piliforme</i> (Tyzzer's organism)
<i>Corynebacterium kutscheri</i>	<i>Corynebacterium kutscheri</i>
	<i>Bordetella bronchiseptica</i>
<i>Pasteurella pneumotropica</i>	<i>Pasteurella pneumotropica</i>
<i>Pseudomonas aeruginosa</i>	<i>Pseudomonas aeruginosa</i>
<i>Staphylococcus aureus</i>	<i>Staphylococcus aureus</i>
Endoparasites	Endoparasites
Helminths (Pinworms) etc.	Helminths (Pinworms) etc.
Intestinal protozoa	Intestinal protozoa
Ectoparasites	Ectoparasites
Dermatophytes	Dermatophytes

Statistic analysis

In the incidence of *S. aureus* between SPF and conventional animals, statistical analysis was performed using the χ -square test and Fisher's exact probability test. The criterion for statistic significance was the 0.01 level. When the expected frequency was less than 5, the Fisher's exact probability test was applied to statistic analysis.

Ulcerative dermatitis

Severe ulcerative dermatitis was found in three mice of the C57BL/6 strain. The dermatological lesions were evaluated for their macroscopic and microscopic changes.

The mice were euthanized by carbon dioxide exposure. Immediately after euthanasia, these mice were necropsied and skin samples were taken for the histopathological examinations. The tissue specimens were fixed in 10% neutral buffered formalin, and 4- μ m paraffin sections were stained with hematoxylin and eosine (HE) and toluidine blue (TB).

Bacteriological examinations of lesions were performed by swabbing the skin lesions with a sterile, cotton-tipped applicator. Samples for aerobic culture were inoculated directly onto blood and MaConKey agar. Anaerobic cultures were also inoculated onto blood agar. Bacterial colonies were examined with Gram-stain and further identification was done using standard bacteriological methods (API Staph, Sysmex Co., Ltd., Kobe, Japan).

Results

Health monitoring results

Pasteurella pneumotropica has been occasionally detected in the trachea of the mice reared in conventional facilities. In contrast, both SPF and conventional rodents had *S. aureus* in their intestinal flora. *S. aureus* was the only pathogen which was always detected in the Bacteriological examinations.

The incidence of *S. aureus* in our health monitoring status is shown in Figs 1 and 2. The prevalence of *S. aureus* in SPF mice was significantly higher than in conventional mice (2008, 2009 and total results, $p < 0.01$). There was no difference in the prevalence of *S. aureus* between both SPF and conventional mice (2010 and 2011). Similarly, SPF rats also had a higher prevalence of this microorganism than conventional rats did (2008, 2009, 2011 and total results, $p < 0.01$). There was no difference in the prevalence of *S. aureus* between both SPF and conventional rats (2010).

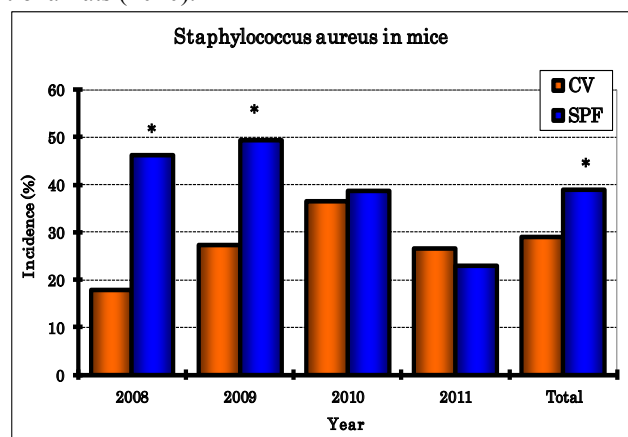


Figure 1. The incidence of infection with *Staphylococcus aureus* in mice. *: $p < 0.01$ [significantly different between conventional (CV) and SPF mice].

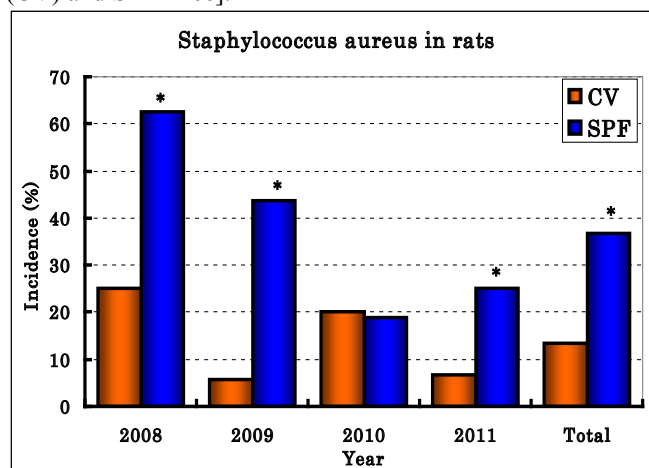


Figure 2. The incidence of infection with *Staphylococcus aureus* in rats. *: $p < 0.01$ [significantly different between conventional (CV) and SPF rats].

Macroscopic findings

The mice showed various degree of papular dermatitis, consisting of mild to moderate alopecia with raised dark red papules on the dorsal trunk. Subsequently, there were irregularly segmental reddish, weeping, or crusty ulcerating skin lesions (1×3 cm in size) over the shoulder, neck, chin and limbs. These papules became more extensive and ulcerated with the advance of the skin disease (Fig. 3). The extensive disfiguring skin lesions appeared pruritic and were self-inflicted by contamination of skin abraded by scratching or biting. As the large ulcerative lesions healed, the mice developed severe contracture of the scarred skin. Although the skin condition had an incidence of less than 1% of mice in our laboratory facilities, ulcerative dermatitis was observed in mice of C57BL/6 strains.

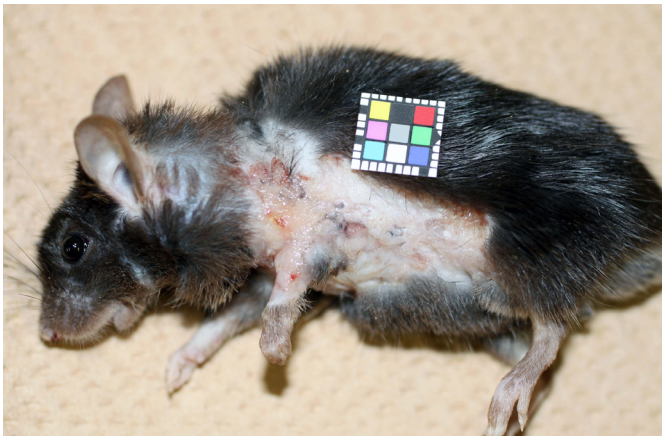


Figure 3. Macroscopic finding of ulcerative dermatitis in a C57BL/6 mouse. Severe ulcerative lesions are seen over the trunk.

Microscopic findings

The lesions were characterized by full-thickness epidermal coagulation necrosis with extensive ulceration and marked inflammatory cell infiltration in the dermis (Fig. 4). The ulcerative lesions were covered with thick dried proteinaceous materials (degenerating nuclear debris, hemorrhage and coagulated serum proteins) and a very large number of inflammatory cells such as neutrophils and lymphocytes. The epidermis adjacent to the ulcer showed hyperplastic changes to various degrees with mild to moderate acanthosis and orthokeratosis. In the underlying granulation tissues, there were an increased number of neutrophils, lymphocytes, macrophages and mast cells. Infiltration of dermal mast cells apparently increased in the skin lesions relative to the normal sites (Fig. 5).

As the lesions repaired, reepithelialization was found in the edge of ulcers. The regenerated epidermis was also acanthotic beneath the adherent crust and mast cells predominated in the dermal inflammation with dilated vasculature (Fig. 6). The dermis exhibited the regular arrangement of granulation tissues in the form of the crust. These findings revealed that histopathological diagnosis was mast-cell rich perivascular dermatitis accompanying the ulcerative lesions.

Discussion

It is known that *S. aureus* is found with a high prevalence in most colonies of laboratory mice. Strangely enough, *S. aureus* is uncommon in wild mice (Hansen 2011).

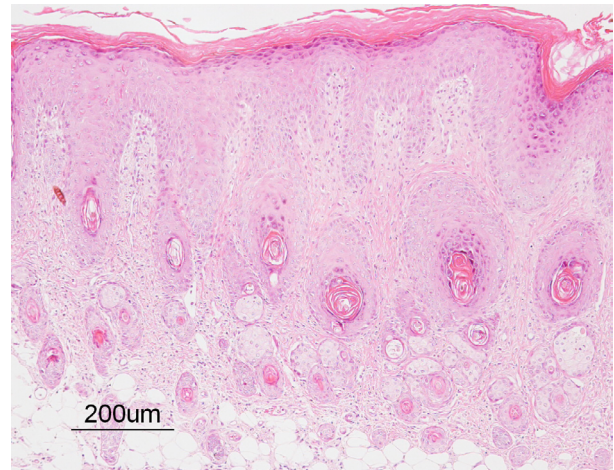


Figure 4. Microscopic finding of ulcerative dermatitis in a C57BL/6 mouse. Full-thickness epidermal coagulation necrosis with extensive ulceration is seen. Marked inflammatory cell infiltration was also found in the dermis. HE stain.

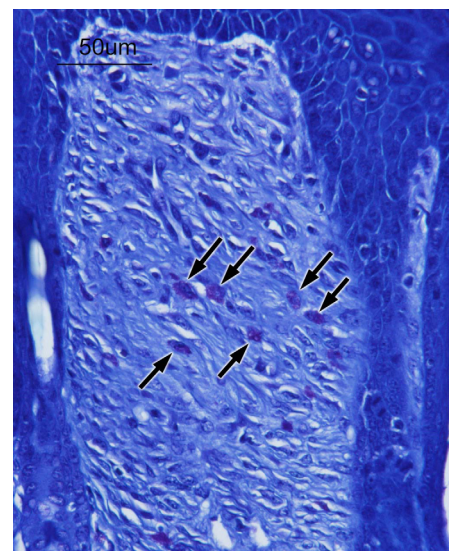


Figure 5. Microscopic finding of ulcerative dermatitis in a C57BL/6 mouse. Infiltration of dermal mast cells can be observed. TB stain.

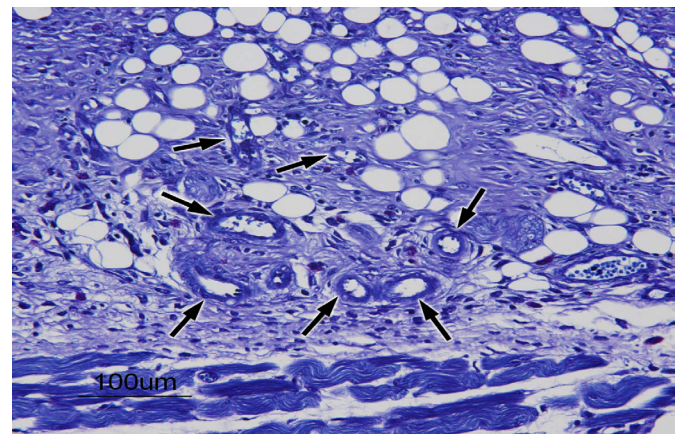


Figure 6. Microscopic finding of ulcerative dermatitis in a C57BL/6 mouse. The dermal inflammation with dilated vasculature can be observed. TB stain.

In our investigation, both mice and rats were considered susceptible to intestinal colonization of *S. aureus*. A high incidence of *S. aureus* in our health monitoring status was a prominent feature in SPF mice and SPF rats.

The *S. aureus* transmission among mice occurs by direct contact with infected mice or people and contaminated equipment. *S. aureus* recovered from asymptomatic and clinically abnormal mice are often identical to the phage types isolated from the animal care staff, documenting that mice can acquire *S. aureus* through human contact (Besch-Williford & Franklin 2007). Thus, some authors consider that the almost ubiquitous presence of *S. aureus* on the skin and mucous membranes of humans (care takers and research staffs) makes direct contact the most common form of *S. aureus* transmission.

Although the nares in humans are frequent sites of colonization by *S. aureus*, the *S. aureus* carrying rate was relatively low (11.3%) for the skin of humans (Nagase *et al* 2002). Other study reported *S. aureus* could be isolated from only 5% of the skin of healthy individuals (Gloor *et al* 1992). It remains unsettled whether *S. aureus* isolated in association with the skin lesions was a simply opportunistic pathogen of devitalized tissues or rather a aggravating factor of this skin condition.

In the present study, there was a significant difference in the prevalence of *S. aureus* between SPF and conventional rodents. Our results of rodent health monitoring programs showed that incidence of SPF rodents by *S. aureus* was higher than in conventional rodents ($p < 0.01$). As the level of microbiological control was elevated in laboratory mice, *S. aureus* tended to colonize on their simplified intestinal flora. This study revealed that simplification of the intestinal normal flora caused colonization infection by *S. aureus* in SPF rodents.

In general, *S. aureus* is described as one of opportunistic pathogens, benignly colonizing host tissues. However, *S. aureus* is capable of liberating virulence factors once the epithelial barrier is breached (Besch-Williford & Franklin 2007). It is known that *S. aureus* has been associated with a multifactorial ulcerative dermatitis condition of laboratory rats (Weisbroth *et al* 2006). Ulcerative dermatitis caused by *S. aureus* and self trauma is a common disease phenomenon in this strain. Ulcerative dermatitis is also known to occur secondarily to immune complex vasculitis (Sundburg *et al* 1994) or to cage mate hair chewing or barbering (Garner *et al* 2004). The underlying vasculature seemed to become involved in the developmental processes of these lesions. It was probable that their bite wounds and scratching the lateral thorax with the toes of the rear legs were some factors in the inoculation of *S. aureus*.

Histopathological examinations showed epidermal degeneration and dermal inflammation with mast cell infiltration. Pathogenic proteins derived from *S. aureus* cause histopathologically epidermal thickening with infiltration of the dermis by mast cells in mice (Hong *et al* 2011). These dermatological changes are associated with the enhanced cutaneous production of IL-4, IL-5, IFN- γ and IL-17 from dermal fibroblasts (Hong *et al* 2011). Mast cells release inflammatory chemical mediators, such as histamine, leukotrienes and prostaglandins, on IgE-mediated stimulation with specific allergens. Furthermore, mast cells produce a wide variety of cytokines, suggesting their active participation in the late-phase reaction and the chronic stage of inflammation (Harvima *et al* 1994; Bradding 1996). Ulcerative

skin lesions were attributed to an increase in these chemical factors from mast cells.

Mast cells can play a role in bacterial skin infection by acting as sentinels of the immune system and as effector cells in immune responses against the pathogens (Metz *et al.*, 2008; Henz 2008). Matsui and Nishikawa reported that percutaneous application of peptidoglycan from *S. aureus* induced an increase in mast cell numbers in the dermis of mice (Matui & Nishikawa 2005). The etiology of this severe dermatitis seemed to be associated with immunological changes in C57BL/6 mice suffering from *S. aureus*-infection.

Mast-cell rich perivascular dermatitis accompanying the ulcerative lesions suggested that mast cells should be critically involved in initiating and modulating optimal host responses to bacteria by either inflammatory or anti-inflammatory effects, depending on the course of the host reaction induced by the pathogen (*S. aureus*). It was probable that increased mast cells caused behavioral abnormalities including overgrooming and frequently observed barbering and scratching behavior.

Conclusions

Our health monitoring results showed that *S. aureus*-infection in SPF rodents was higher than in conventional rodents. This phenomenon was attributable to simplification of the intestinal normal flora in SPF rodents. C57BL/6 mice were predisposed to severe ulcerative dermatitis infected with *S. aureus*. Macroscopically and microscopically, this skin disease was diagnosed as mast-cell rich perivascular dermatitis accompanying the ulcerative lesions.

References

- Besch-Williford, C., Franklin, C. L., 2007. Aerobic gram-positive organisms. In *The Mouse in Biomedical Research*, 2nd edition, Vol. 2 Diseases. Fox, J. G., Barthold, S. W., Davisson, M. T., Newcomer, C. E., Quimby, F. W., Smith, A. G., eds., 2007. pp. 389-406. Academic Press, San Diego, USA.
- Bradding, P., 1996. Human mast cell cytokines. *Clin Exp Allergy* 26:13-19.
- Duarte-Vogel, S. M., Lawson, G. W., 2011. Association between hair-induced oronasal inflammation and ulcerative dermatitis in C57BL/6 mice. *Comp Med* 61:13-19.
- Garner, J. P., Weisker, S. M., Dufour, B., Mench, J. A., 2004. Barbering (fur and whisker trimming) by laboratory mice as a model of human trichotillomania and obsessive-compulsive spectrum disorders. *Comp Med* 54:216-224.
- Gloor, M., Peters, G., Stoika, D., 1992. On the resident aerobic bacterial skin flora in unaffected skin of patients with atopic dermatitis and in normal controls. *Dermatologia* 164:258-265.
- Hansen, A. X., 2011. Health status and health monitoring. In *Handbook of Laboratory Animal Science*. 3rd edition. Vol. 1 Essential Principles and Practices. Hau, J., Schapiro, S. J. eds., 2011, pp. 251-305. CRC Press, Boca Roton, USA.
- Harvima, I. T., Horsmanheimo, L., Nankkarinen, A., Horsmanheimo, M., 1994. Mast cell proteinases and cytokines in skin inflammation. *Arch Dermatol Res* 287:61-67.
- Henz, B. M., 2008. Exploring the mast cell enigma: a personal reflection of what remains to be done. *Exp Dermatol.* 17:91-99.
- Hong S. W., Kim, R. M., Lee, E. Y., Kim, J. H., Kim, Y. S., Jeon, J. M., et al, 2011. Extracellular vesicles derived from *Staphylococcus aureus* induce atopic dermatitis-like skin inflammation. *Allergy* 66:351-359.

- Kastenmayer, R. J., Fain, M. A., Perdue, K. A., 2006. A retrospective study of idiopathic ulcerative dermatitis in mice with a C57 BL/6 background. *J Am Assoc Lab Anim Sci* 45:8-12.
- Matui, K., Nishikawa, A., 2005. Percutaneous application of peptidoglycan from *Staphylococcus aureus* induces an increase in mast cell numbers in the dermis of mice. *Clin Exp Allergy* 35:382-387.
- Metz, M., Siebenhaar, F., Maurer, M., 2008. Mast cell functions in the innate skin immune system. *Immunobiology* 213:251-260.
- Nagase, N., Sasaki, A., Yamashita, K., Shimizu, A., Kitai, S., Kawano, J., 2002. Isolation and species distribution of *Staphylococci* from animal and human skin. *J Vet Med Sci* 64: 245-250.
- Sundburg, J. P., Brown, K. S., McMahon, W. M., 1994. Chronic ulcerative dermatitis in black mice. In *Handbook of Mouse Mutations with Skin and Hair Abnormalities. Animal Models and Biomedical Tools*. Sundburg, J. P. eds., 1994. pp. 485-492. CRC Press, Boca Roton, USA.
- Sundberg, J. P., Taylor, D., Lorch, G., Miller, J., Silva, K. A., Sundberg, B. A., et al, 2011. Primary follicular dystrophy with scarring dermatitis in C57BL/6 mouse substrains resembles central centrifugal cicatricial alopecia in humans. *Vet Pathol* 48:513-524.
- Weisbroth, S. H., Kohn, D. F., Boot, R., 2006. Bacterial, micoplasmal and mycotic infections. In *The Laboratory Rat*, 2nd edition, Suckow, M. A., Weisbroth, S. H., Franklin, C. L. eds., 2006. pp. 339-421. Academic Press, San Diego, USA.
- Williams, L. K., Csaki, L. S., Cantor, R. m., Reue, K., Lawson, G. W., 2012. Ulcerative dermatitis in C57BL/6 mice exhibits an oxidative stress response consistent with normal wound healing. *Comp Med* 62:166-171.

Author

•Tohru Kimura, Center for Experimental Animals, National Institutes of Natural Sciences, 38, Nishigo-naka, Myodaiji, Okazaki, Aichi, 444-8585, Japan, kimura@nips.ac.jp

Citation Kimura, T., 2012. Mast-cell rich perivascular dermatitis accompanying the ulcerative lesions resulting from infection of *Staphylococcus aureus* in C57BL/6 mice. *HVM Bioflux* 4(2):63-67.

Editor Ștefan C. Vesa

Received 20 July 2012

Accepted 2 August 2012

Published Online 7 August 2012

Funding None reported

**Conflicts/
Competing
Interests** None reported