

The effects of chitosan and chitin wound dressings in hairless dogs

Tohru Kimura

Center for Experimental Animals, National Institutes of Natural Sciences, 38, Nishigonaka, Myodaiji, Okazaki, Aichi, 444-8585, Japan; e-mail: kimura@nips.ac.jp

Abstract. The effects on wound healing of chitosan and chitin wound dressings were clinically and histopathologically investigated using a split thickness wound in hairless dogs. Wound dressings used in this study included examined were dried porcine skin (DP skin), cotton type chitosan (CT chitosan) and chitin fiber dressing (chitin FD). Clinically, there were no differences in wound healing among the sites treated with chitosan, chitin and the untreated control sites. In contrast, DP skin and CT chitosan did not promote wound healing. CT chitosan dressings induced severe inflammatory reactions. In the sites treated with chitin FD, wound healing was delayed. Histopathologically, there were few differences in reepithelialization among the sites treated with chitosan, chitin and the WD-untreated sites. The sites treated with DP skin received elastic fibers from DP skin. CT chitosan dressings had a deleterious effect on wound healing (reepithelialization and granulation). Dyskeratosis, congestion, hemorrhage, cellular infiltration, intra- and intercellular edema were seen in the epidermis. Bleeding, infiltration of inflammatory cells and mast cells, and edematous changes were seen in the dermis. In the sites treated with chitin FD, the invasion of mononuclear cells, mast cells and erythrocytes caused the retarded development of reepithelialization. It was concluded that chitosan and chitin had few deleterious effects on wound healing whereas DP skin, CT chitosan and chitin FD induced inflammation in the wound of hairless dogs. In addition, it was clear that there are species differences in the skin reactions to wound dressings. These results suggested special care should be taken in veterinary clinical use of human medical wound dressings.

Key Words: chitin, chitosan, dried porcine skin, hairless dogs, wound dressings, wound healing.

Introduction. Chitin (β -(1-4)-N-Acetyl-D-Glucosamine) is a cellulose-like biopolymer which is widely distributed as an important structural element of the integuments of arthropods, particularly crustaceans, molluscs, unicellular organisms, seaweeds and fungi. Chitosan, a mucopolysaccharide having structural characteristics similar to glycosamines, is the alkaline deacetylated product of chitin. These polysaccharides have been introduced into pharmaceutical and cosmetic technology, where they can be used as a vehicle for drugs (Miyazaki et al 1990; Yoshida 1993) or as a component of moisturizers (Muzzarelli 1983). In medicine, their reconstructing properties are used to make bandages shaped like contact lenses for damaged corneas, to prepare wound dressings for the treatment of burns and ulcers, and to make sutures (Muzzarelli 1983; Jayasree et al 1995; Costain et al 1997). Chitosan and chitin are believed to be nontoxic and ideal biopolymers in spite of lack of adequate data on their safety. However, adverse reactions of chitosan and chitin have begun to be reported in cosmetic and medical fields (Cleenewerck et al 1994; Tanaka et al 1997; Pereira et al 1998).

Recently, we have established a colony of hairless hybrids of Mexican hairless dogs (Kimura et al 1993). Hairless dogs have been utilized for investigating delayed contact dermatitis (Kimura & Doi 1994ab) and for evaluating dermatotoxicity of agricultural chemicals (Kimura et al 1998), all-*trans*-retinoic acid (Kimura & Doi 1998), and corticosteroids (Kimura & Doi 1999).

The purpose of this study was to investigate potential dermatotoxicity of chitosan, chitin and wound dressings made of their derivatives, using the split thickness wound of hairless dogs.

Materials and Methods

Dogs

Three male dogs were used in this study. They were N4 hairless hybrids resulting from the breeding of male N3 hairless dogs and female beagle dogs.

Dogs were individually housed in stainless steel cages (90× 90 × 90 cm) in an animal room controlled at 24±1°C and 55±5% relative humidity with 10 to 15 exchanges of 100% fresh air/hour and 12-hour light (7AM to 7PM), 12-hour dark (7PM to 7AM) cycle. They were fed a commercial dry dog food (Labo D Standard, Nihon Nosan Kogyo Co., Ltd., Yokohama, Japan) and water *ad libitum*.

Wound dressing (WD)

The following reagents and dressing materials were tested in this study: 1. chitosan (Wako Pure Chemical Industries, Ltd., Osaka, Japan), 2. chitin (Sigma Chemical Co., St. Louis, USA), 3. dried porcine skin (DP skin, Alloask D, Taiho Yakuin Co., Ltd., Tokyo, Japan), 4. cotton type chitosan materials (CT chitosan), 5. chitin fiber dressing (chitin FD) and 6. WD-untreated (only bandage, control). CT chitosan was medical grade chitosan derivatives modified into water-soluble materials. Six split thickness wounds were made on the dorsal site of the animal.

Procedures

The duration of this experiment was 21 days following wound creation. The animals were anesthetized with ketamine hydrochloride (10 mg/kg, Ketalar, Sankyo Co., Ltd., Tokyo, Japan) after medetomidine (20 µg/kg, s.c., Domitol, Meiji Seiyaku Co., Ltd., Tokyo, Japan) premedication. Split thickness wounds (2×2 cm) were made on the dorsal skin of each dog, using sterile surgical blades (Feather Safety Razor Co., Ltd., Osaka, Japan). The blade of a scalp was used to dissect the epidermis and the upper layer of the dermis over the whole wound area. After irrigating the wound with sterile physiological saline and 0.05% chlorhexidine gluconate (Hibitane, Sumitomo Seiyaku, Co. Ltd., Osaka, Japan), each reagent or dressing material was applied to the split thickness wound at a rate of approximately 10 mg/cm² (Fig. 1). The WD-treated sites were covered with transparent adhesive polyurethane film (Tegaderm, 3M Health Care, Tokyo, Japan). Canine protective jackets and Elizabethan collars (Tsubawa Yoko Co., Ltd., Tokyo, Japan) were used to prevent the dogs from dislodging the dressings or from peeling off. The WD-treated sites were kept under the wet environment during this study. Keeping wounds moist allows normal epidermal migration at the same level as the undamaged epidermis and without shrinkage. The dressings were changed on day 1, 3, 7, 14 and 21 of the study. The adhesive polyurethane film was also changed on these days.

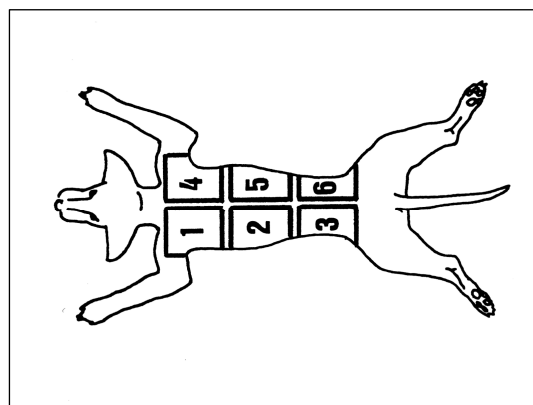


Figure 1. Diagram of the dorsal skin sites examined in a hairless dog.
1 = chitosan; 2 = chitin; 3 = DP skin; 4 = CT chitosan; 5 = chitin FD;
6 = untreated (control)

Clinical evaluations

Clinical observations were done before the study and daily during the WD-treatment. The WD-treated sites were evaluated daily through the transparent adhesive film, and clinically observable changes (reepithelialization, granulation, inflammatory reactions and exudation) were photographed.

Histopathological examination

Tissue specimens were obtained from both treated and untreated sites of the dorsal skin of each dog using a 6-mm biopsy punch under general anesthesia with medetomidine on the day before the study, and at 7, 14 and 21 days after the study start. Skin specimens were fixed in 10% neutral buffered formalin, and 4- μ m paraffin sections were stained with hematoxylin and eosin and toluidine blue, and by van Gieson's and Weigert's staining. The total severity of epidermal and dermal changes was graded as negligible (–), slight (\pm), mild (+), moderate (++) and marked (+++).

Results

Gross appearances

Controls: By 14 to 21 days after the beginning of this study, complete reepithelialization and granulation developed in the WD-untreated sites. Throughout this study, there were no abnormal reactions such as wound infection and contraction in the WD-untreated sites. Additionally, we could observe no abnormal findings in exudate formation and skin reaction adjacent to the wound. The wounds were completely reconstructed at the end of the study.

Chitosan dressings: Except for the time of reepithelialization, there were no differences in wound healing between the sites treated with chitosan and the WD-untreated sites. After 14 days of treatment with chitosan, the skin showed reepithelialization and became pigmented (Fig. 2).

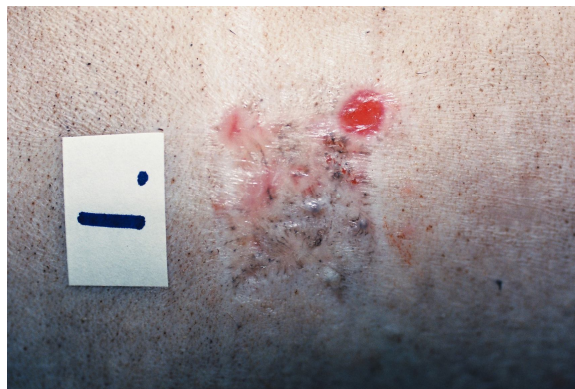


Figure 2. Gross appearance of the site after 14 days of the treatment with chitosan. Reepithelialization and pigmentation are seen.

Chitin dressings: Although the sites treated with chitin were judged to be adequately reepithelialised after 14 days of treatment, chitin subsequently caused moderate inflammatory reactions in the skin. Except for this respect, the process of the wound healing in the sites treated with chitin was similar to that in the sites treated with chitosan.

Dried porcine dressings: The treatment with DP skin delayed wound healing in the skin of hairless dogs, as compared with the WD-untreated sites (Fig. 3). In the sites treated with DP skin, neither reepithelialization nor granulation was sufficiently completed by 21 days after treatment. Exudate formation and skin reaction adjacent to the wound were clearly found. In some portions of the split-thickness wounds, the surface and the periphery of the wounds showed moderate inflammatory reactions 14

days after beginning the treatment with DP skin. At the end of the study, wound healing were not observed in the site treated with DP skin.

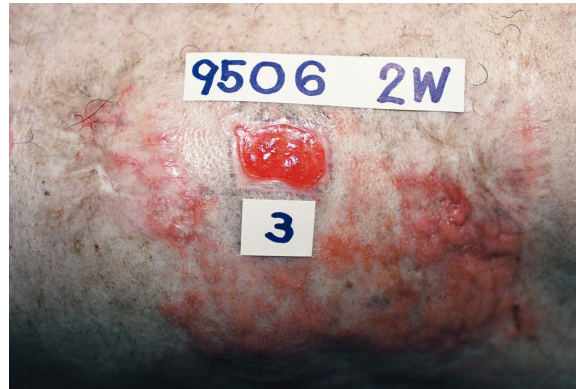

Figure 3. Gross appearance of the site after 21 days of the treatment with DP skin. Wound healing is not seen.

Cotton type chitosan dressings: From the day after treatment with CT chitosan, inflammatory reactions developed around the wounds. Although reepithelialization was observed by 14 days after beginning the treatment with CT chitosan, erythematous reactions became apparent in the course of the treatment with CT chitosan (Fig. 4). In addition, a large amount of exudate appeared on the wound surface for 7 to 10 days after beginning of the treatment with CT chitosan. CT chitosan did not accelerate wound healing in the skin of hairless dogs. The sites reepithelialised by applying chitosan, chitin and CT chitosan showed a number of comedones after 21 days of the treatment.

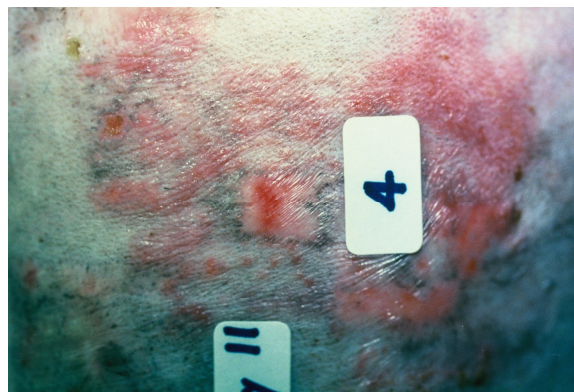

Figure 4. Gross appearance of the site after 14 days of the treatment with CT chitosan. Severe erythematous reaction is seen.

Chitin fiber type dressings: In the sites treated with chitin FD, wound healing was apparently delayed in comparison with the sites treated with other dressings. During this treatment, considerable exudation and/or bleeding from the wound surface were observed. Skin reaction adjacent to the wound was moderate. At the end of the study, no wound healing was noted. Formation of granulation tissue and reepithelialization were inhibited by covering with chitin FD (Fig. 5).

Histopathological findings

Controls: At 7 days after the beginning of this study, the WD-untreated sites showed the reepithelializing process. The reconstructed skin had a thick epidermal structure consisting of 8 to 10 cell layers. In the dermis, fibroblasts proliferated and produced granulation tissue, while inflammatory cells were sparsely observed. By 14 to 21 days of this study period, the epidermis became flat and the basal layer was mildly pigmented with melanin granules. Collagen fibers were newly synthesized and neovascularization was also found in the reconstituted dermis (Fig. 6).

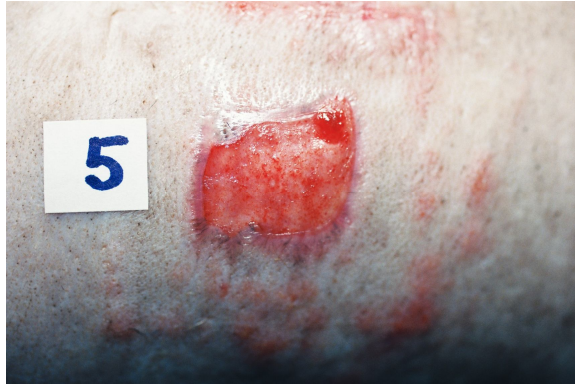

Figure 5. Gross appearance of the site after 21 days of the treatment with chitin FD. Wound healing is apparently delayed.

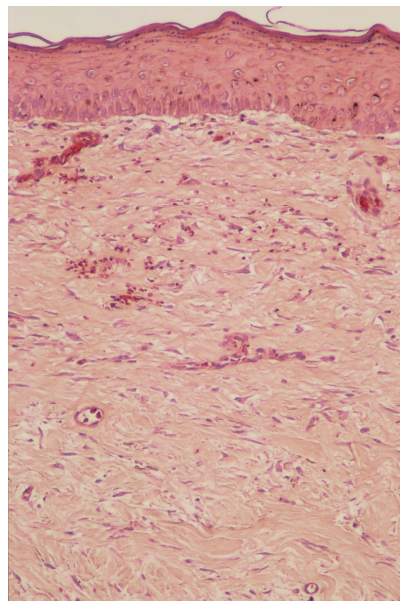


Figure 6. WD-untreated skin at 21 days after beginning of this study. HE. $\times 175$.

Chitosan dressings: After 7 days of the treatment with chitosan, thick epidermis and granulation tissues are observed in the split thickness wounds. Punch biopsies revealed a progressive increase in the thickness of the epidermal layer. During treatment with chitosan, dermatotoxicity such as necrosis, congestion and infiltration of inflammatory cells was not found. In the course of reepithelialization, there were no apparent differences between the sites treated with chitosan and the WD-untreated sites.

Chitin dressings: The sites treated with chitin exhibited moderate congestion and vasodilation with inflammatory cells in the dermis after 14 days of treatment. There were few differences in reepithelialization between the sites treated with chitin and the WD-untreated sites. In the sites treated with chitosan and chitin, the repaired skin of hairless dogs had some comedo-like lesions associated with occlusion of sebaceous glands by reepithelialization.

Dried porcine dressings: DP skin was very irritating to the wounds of hairless dogs and inhibited reepithelialization. Thin epidermal layers began to extend from the wound margins. There was a greater extent of infiltration of inflammatory cells beneath the newly formed epidermis. The regenerating epidermis and dense exudations contained elastic fibers which seemed to be derived from DP skin and to be contributing to the severe inflammatory reactions in the wounds (Fig. 7).

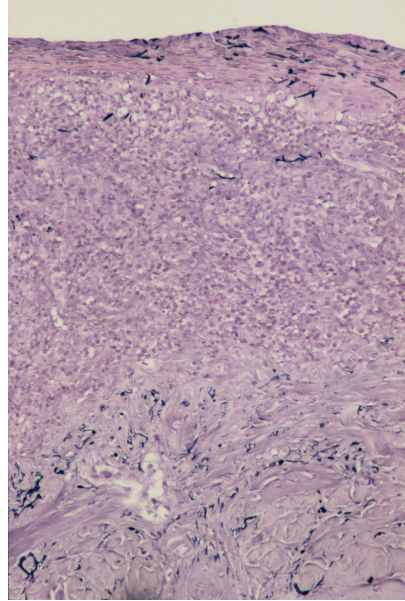


Figure 7. Dorsal skin after 7 days of the treatment with DP skin. Thin epidermal layer and marked inflammatory cell infiltration with elastic fibers derived from DP skin. HE. $\times 175$.

Cotton type chitosan dressings: CT chitosan had deleterious effects on wound healing (reepithelialization and formation of granulation tissue) in hairless dogs. The sites treated with CT chitosan for 7 days showed epidermal degeneration such as dyskeratosis, congestion, hemorrhage, cellular infiltration, intracellular edema and intercellular edema. In the dermis, there were bleeding, infiltration of inflammatory cells and edematous changes (Fig. 8). A number of degranulated mast cells were observed in the dermis, especially around the capillary vessels. In the dermal-epidermal junction, disruption of the basement membrane was found. After 14 days of treatment with CT chitosan, the above-mentioned dermatological changes became apparent. In some repaired portions, so-called "birds-eye-structure" characterized by pyknotic nuclei and vacuolated granular cells were observed (Fig. 9). After 21 days of the treatment with CT chitosan, the arrangement of the collagen fibers in the reepithelialized skin was sparse and disorderly.

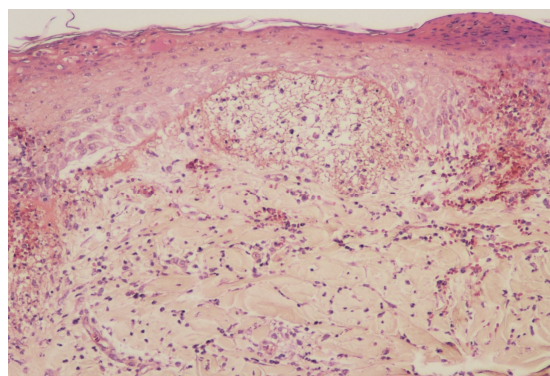


Figure 8. Dorsal skin after 7 days of the treatment with CT chitosan. Epidermal degeneration, bleeding and inflammatory cell infiltration with edematous changes are seen. HE. $\times 280$.

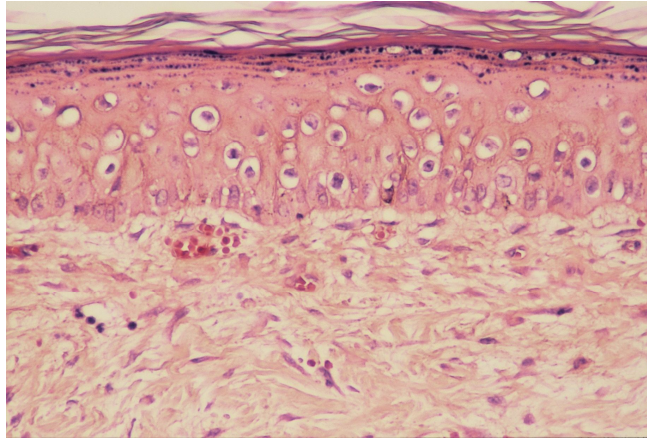


Figure 9. Dorsal skin after 14 days of the treatment with CT chitosan. "Birds-eye-structure" is seen. HE. \times 350.

Chitin fiber type dressings: After 7 days of the treatment with chitin FD, a large amount of exudate covered the surface of the wounds. The invasive stage of fibroblasts, mononuclear cells, mast cells and erythrocytes showed the retarded development of reepithelialization (Fig. 10). After 14 to 21 days of the treatment with chitin FD, there was marked dermal edema which was characterized by hemorrhage and disordered arrangement of collagen fibers. Throughout this study, histopathologically, we did not find that the sites treated with wound dressings were in a more advanced stage of reepithelialization than the undressed wounds. Histopathological findings during treatment with wound dressings are summarized in Table 1.

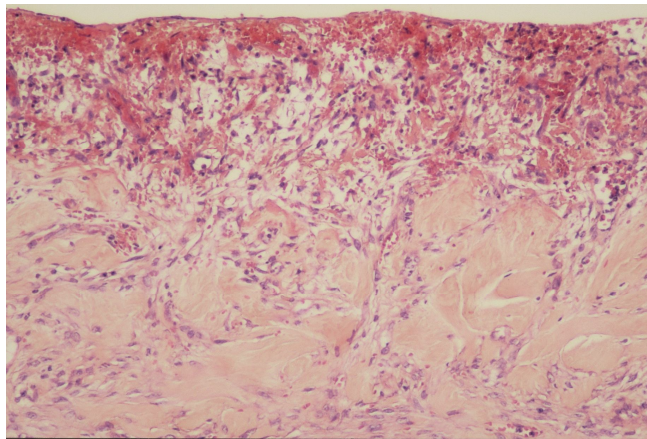


Figure 10. Dorsal skin after 7 days of the treatment with chitin FD. A large amount of exudate covers the wound surface. HE. \times 175.

Discussion. The split thickness wounds treated with chitosan, chitin and wound dressings made of these materials were macroscopically and histopathologically examined. In addition, wound healing in the site treated with each dressing was compared with that in the WD-untreated site.

Chitin did not induce inflammatory reactions until 14 days after beginning of the treatment. This material dissolved slightly in the wound fluid. It is presumed that insoluble and nonabsorbable chitin was not severely toxic to the wound of hairless dogs. Hairless dogs developed comedo-like lesions in the sites treated with chitosan and chitin. These lesions were similar to sebaceous cysts observed after long-term treatment of human wounds with occlusive dressings.

Table 1

Histopathological findings in the split thickness wounds of hairless dogs after treatment with wound dressings

<i>Findings</i>	<i>Chitosan</i>	<i>Chitin</i>	<i>DP skin</i>	<i>CT chitosan</i>	<i>Chitin FD</i>	<i>Control</i>
Epidermis						
Reepithelialization	+	+	- to ±	±	-	+
Dyskeratosis	-	-	-	++	-	-
Thickening	++	++	-	± to ++	-	++
Rete ridges	++	++	-	± to ++	-	++
Infiltration of inflammatory cells	-	-	+++	+++	+++	-
Fibroblasts	-	-	-	-	+++	-
Erythrocytes	-	-	-	-	+++	-
Mast cells	-	-	-	-	+++	-
Intracellular edema	-	-	-	++	-	-
Intercellular edema	-	-	-	++	-	-
Birds-eye structures	-	-	-	++	-	-
Disruption of the basement membrane	-	-	-	+++	-	-
Pigmentation	+	+	-	-	-	+
Dermis						
Granulation	++	++	±	- to ±	-	++
Congestion	±	++	+++	+++	++	±
Hemorrhage	±	++	+++	+++	++	±
Edema	-	-	++	++	++	-
Neovascularization	+	++	+	++	++	+
Vasodilatation	+ to ++	++	+	++	++	+
Infiltration of inflammatory cells	- to ±	++	+++	+++	++	±
Degranulated mast cells	- to ±	- to ±	- to ±	++ to +++	+	- to ±
Arrangement of collagen fibers	+	+	±	±	±	+
Sebaceous cysts	+	++	-	±	-	++

The degree of histopathological changes: - = negative; ± = slight; + = mild;

++ = moderate; +++ = marked.

Throughout this study, chitosan did not show any toxic effects in the treated sites. Treatment with this agent revealed no discernible accelerating effects in wound healing, as compared with non-treatment. In the wound healing process, there were no differences between the sites treated with chitosan and the WD-untreated sites.

DP skin is known to be a standard wound dressing used widely in human medicine. It has been established that DP skin is a biodegradable material with good biocompatibility and beneficial biological effects such as acceleration of wound healing (Kuroyanagi & Takao 1995). In contrast, our results revealed that DP skin provoked adverse effects to the wounds of hairless dogs. This skin reaction of hairless dogs seemed to result from absorption of proteins (elastic fibers) derived from the porcine skin, i. e. proteins of different species.

CT chitosan has been demonstrated to induce formation of regularly organized cutaneous tissues and to reduce anomalous wound healing (Biagini et al 1991). Chemical reason for preferring CT chitosan to plain chitosan is its gel-forming ability in contact with

wound fluids in human beings. Dressing with CT chitosan retains the wound exudate to maintain a moist environment at the wound surface and improves wound healing (Biagini et al 1991). Contrary to beneficial results in human clinical reports, the present study revealed that CT chitosan had clinically and histopathologically apparent adverse effects on the split thickness wounds in hairless dogs. Okamoto et al (1993ab; 1995) reported evaluation of CT chitosan on open wound healing in dogs. They described that the experimental dogs showed infiltration of inflammatory cells and a considerable amount of exudate on the wound surface. In laboratory animals, Tanaka et al (1997) studied effects of CT chitosan on BALB/c mice by oral and parental administration. Their results showed that CT chitosan did not evoke the general and cellular abnormalities. Rao & Sharma (1997) performed toxicity tests (acute systemic toxicity test, pyrogen test, eye and skin irritation tests and intramuscular test) of chitosan using mice, guinea pigs and rabbits, and they concluded that chitosan was nontoxic. Clinically and histopathologically, the dermatotoxicity of CT chitosan to hairless dogs was more prominent than that to the other laboratory animals. These findings revealed that there were species differences in the skin reactions to CT chitosan.

Recently, allergic contact dermatitis due to a cream with chitosan gluconate has been reported in human beings (Cleenewerck et al 1994; Pereira et al 1998). In the present study, the skin around the wound treated with CT chitosan exhibited apparent inflammatory reactions. Chitosan derivatives are considered to have some deleterious effect.

In our previous papers (Kimura & Doi 1994ab), we reported that the dermis of hairless dogs contained fewer mast cells than that of haired dogs and Beagles. In the sites treated with CT chitosan, there were a number of mast cells in the dermis. The appearance of degranulated mast cells may be associated with irritating potentials of CT chitosan wound dressings.

Chitin FD is an absorbable material and this dressing has high air permeability and water absorption ability. Several studies (Nakajima et al 1986; Tanaka et al 1997; Su et al 1997) reported toxicologic findings induced by administration of chitosan derivatives. Nakajima et al (1986) reported that an absorbable chitin provoked a great extent of inflammatory cell infiltration. In mice, Tanaka et al.⁷ mentioned that many hyperplastic macrophages were observed in the mesentery and foreign-body giant-cell-type polykaryocytes were found in the spleen. The clinical appearance in this study showed that chitin FD apparently inhibited wound healing. In addition, the histopathological findings demonstrated that chitin FD caused retardation of reepithelialization and granulation in hairless dogs. These results revealed that chitin FD was an unsuitable material for wound dressings in dogs.

In conclusion, chitosan and chitin had few deleterious effects on wound healing whereas DP skin and their derivatives (CT chitosan and chitin FD) induced noticeably high dermatotoxicity in wounds of hairless dogs. In addition, it appears that there are species differences in the skin reactions to wound dressing materials. These results suggested special care should be taken in veterinary clinical use of human medical wound dressings.

Conclusion. Chitosan and chitin had few deleterious effects on wound healing whereas DP skin and their derivatives (CT chitosan and chitin FD) induced noticeably high dermatotoxicity in wounds.

Acknowledgements. The author declares that he is not currently affiliated or sponsored by any organization with a direct economic interest in subject of the article.

References

- Biagini G., Bertani A., Muzzarelli R., Damadei A., DiBenedetto G., Belligolli A., et al, 1991 Wound management with N-carboxybutyl chitosan. *Biomaterials* **12**: 281-286.
- Cleenewerck M. B., Martin P., Laurent D., 1994 Allergic contact dermatitis due to a moisturizing body cream with chitin. *Contact dermatitis* **31**: 196-197.
- Costain D. J., Kennedy R., Ciona C., McAlister V. C., Lee T. D. G., 1997 Prevention of postsurgical adhesions with N, O-carboxymethyl chitosan: Examination of the most

- efficacious preparation and the effect of N, O-carboxymethyl chitosan on postsurgical healing. *Surgery* **121**:314-319.
- Jayasree R. S., Rathinam K., Sharma C. P., 1995 Development of artificial skin (template) and influence of different types of sterilization procedures on wound healing pattern in rabbits and guinea pigs. *Journal of Biomaterials Applications* **10**:144-162.
- Kimura T., Ohshima S., Doi K., 1993 The inheritance and breeding results of hairless descendants of Mexican hairless dogs. *Laboratory Animals* **27**:55-58.
- Kimura T., Doi K., 1994a Dinitrochlorobenzene (DNCB)-induced delayed-type hypersensitivity reaction in the dorsal skin of hairless dogs. *Journal of Toxicologic Pathology* **7**:229-235.
- Kimura T., Doi K., 1994b Age-related changes in skin color and histologic features of hairless descendants of Mexican hairless dogs. *American Journal of Veterinary Research* **55**:480-486.
- Kimura T., Kuroki K., Doi K., 1998 Dermatotoxicity of agricultural chemicals in the dorsal skin of hairless dogs. *Toxicologic Pathology* **26**:442-447.
- Kimura T., Doi K., 1998 Effects of all-trans-retinoic acid on the dorsal skin of hairless dogs. *Toxicologic Pathology* **26**:595-601.
- Kimura T., Doi K., 1999 Dorsal skin reactions of hairless dogs to topical treatment with corticosteroids. *Toxicologic Pathology* **27**:528-535.
- Kuroyanagi Y., Takao Y., 1995 [The kind and feature of wound dressings]. In: Anazawa S. (ed.). Health Publisher, Tokyo, 53-70. [In Japanese]
- Miyazaki S., Yamaguchi H., Takada M., Hou W. M., Takeichi Y., Yasubuchi H., 1990 Pharmaceutical application of biomedical polymers. Preliminary study on film dosage prepared from chitosan for oral drug delivery. *Acta Pharmaceutica Nordica* **2**:401-406.
- Muzzarelli R. A. A., 1983 Chitin and its derivatives: new trend of applied research. *Carbohydrate Polymers* **3**:53-75.
- Nakajima M., Atsumi K., Kifune K., Miura K., Kanamaru H., 1986 Chitin is an effective material for sutures. *Japanese Journal of Surgery* **16**:418-424.
- Okamoto Y., Minami S., Matsushashi A., Sashiwa H., Saimoto H., Shigemasa Y., et al, 1993 Polymeric N-acetyl-D-glucosamine (chitin) induces histionic activation in dogs. *The Journal of Veterinary Medical Science* **55**:739-742.
- Okamoto Y., Minami S., Matsushashi A., Sashiwa H., Saimoto H., Shigemasa Y., Tanigawa T., Tanaka Y., Tokura S., 1993 Application of polymeric N-acetyl-D-glucosamine (chitin) to veterinary practice. *The Journal of Veterinary Medical Science* **55**:743-747.
- Okamoto Y., Shibazaki K., Minami S., Matsushashi A., Tanioka S., Shigemasa Y., 1995 Evaluation of chitin and chitosan on open healing in dogs. *The Journal of Veterinary Medical Science* **57**:851-854.
- Pereira F., Pereira C., Lacerda M. H., 1998 Contact dermatitis due to a cream containing chitin and a carbitol. *Contact Dermatitis* **38**:290-291.
- Rao S. B., Sharma C. P., 1997 Use of chitosan as a biomaterial: Studies on its safety and hemostatic potential. *Journal of Biomedical Materials Research* **34**:21-28.
- Su C. H., Sun C. H., Juan S. W., Hu C. H., Ke W. T., Sheu M. T., 1997 Fungal mycelia as the source of chitin and polysaccharides and their applications as skin substitutes. *Biomaterials* **18**:1169-1174.
- Tanaka Y., Tanioka S., Tanaka M., Tanigawa T., Kitamura Y., Minami S., et al, 1997 Effects of chitin and chitosan particles on BALB/c mice by oral and parental administration. *Biomaterials* **18**:591-595.
- Yoshida T., 1993 [Skin substitutes]. In: Harii K., Moriguchi T. (eds.), [Plastic and Reconstructive Surgery. Advanced Series I -3, Recent Advance in the Treatment of Wounds]. Kokuseido, Tokyo, 106-123. [In Japanese]

Received: 02 June 2011. Accepted: 01 July 2011. Published online: 14 July 2011.

Author: Tohru Kimura, Center for Experimental Animals, National Institutes of Natural Sciences, 38, Nishigonaka, Myodaiji, Okazaki, Aichi, 444-8585, Japan, email: kimura@nips.ac.jp

How to cite this article:

Kimura T., 2011 The effects of chitosan and chitin wound dressings in hairless dogs. *HVM Bioflux* **3**(2):66-75.