

# Case report: Extra-anatomic artery bypass for large brachial pseudoaneurysm related to vascular access for dialysis

<sup>1</sup>Marius Fodor, <sup>2</sup>Dan Olinic, <sup>3</sup>Lucian Fodor

<sup>1</sup> Department of Vascular Surgery, Emergency County Hospital, Cluj-Napoca, Romania; <sup>2</sup> Department of Interventional Angiology, Emergency County Hospital, Cluj-Napoca, Romania <sup>3</sup> Department of Plastic Surgery, Emergency County Hospital, Cluj-Napoca, Romania.

**Abstract.** Pseudoaneurysms related to hemodialysis represent 2-10% of arteriovenous fistula (AVF) complications. They can be treated by percutaneous approach, endovascular procedures or surgery. We present a patient with a large brachial pseudoaneurysm of the upper extremity and critical finger ischemia. One-step surgery involved an extra-anatomic brachial -ulnar bypass using the contralateral great saphenous vein, followed by resection of the pseudoaneurysm, avoiding median nerve lesion and the ischemic time of the upper limb. Good revascularization of the hand was achieved.

**Key Words:** vascular access, brachial pseudoaneurysm, brachial-ulnar artery bypass, end-stage renal disease.

**Copyright:** This is an open-access article distributed under the terms of the Creative Commons Attribution License, which permits unrestricted use, distribution, and reproduction in any medium, provided the original author and source are credited.

**Corresponding Author:** M. Fodor, email: drfodor@yahoo.com

## Introduction

Pseudoaneurysms represent 2-10% of arteriovenous fistula (AVF) complications related to hemodialysis (Amorim et al 2013). They are caused by infection, trauma after repeated punctures, or the degeneration of blood vessel walls (Murphy 2011). Thromboses with distal embolia leading to acute upper limb ischemia and spontaneous rupture with important hemorrhage are the pathways of pseudoaneurysm evolution (Bahia et al 2014). Pseudoaneurysms can be treated by percutaneous approach, endovascular procedures or surgery. The percutaneous injection of thrombotic substance into the pseudoaneurysm can be a good solution for small pseudoaneurysms (Mittal et al 2012). The endovascular approach and open surgical treatment with preservation of the adjacent nerves are recommended for large pseudoaneurysms (Lijftogt et al 2014).

Surgery of the pseudoaneurysm implies resection followed by direct artery reconstruction using a vein or prosthetic graft. Extra-anatomic bypass for the upper extremity is another option. This procedure is carried out before the resection of the pseudoaneurysm in order to avoid the ischemic time of the forearm (Sen et al 2014).

Herein, we present our treatment approach in a patient with a large brachial pseudoaneurysm of the upper extremity and critical finger ischemia.

## Case presentation

A 43-year old male with end-stage renal disease enrolled in a hemodialysis program was admitted to the Department of

Vascular Surgery with a large brachial pseudoaneurysm (7 cm in diameter) of the left upper limb associated with critical limb ischemia (figure 1A).

Seven years ago, the patient underwent a failed attempt at a left radiocephalic fistula with distal ligation of the radial artery. Therefore, a left brachial-cephalic fistula was created. Six years ago, the patient's left brachial-cephalic fistula began to develop an anastomotic aneurysm (5 cm in diameter), which was treated by resection and brachial artery reconstruction with the interposition of a 5 cm prosthetic graft. One year later, a pulsatile brachial mass that progressively grew in size was noted. The Doppler Ultrasound revealed the permeability of the ulnar artery with no flow in the radial artery.

Under general anesthesia, an extra-anatomic brachial-ulnar artery bypass was performed using the heterolateral great saphenous vein (Figure 1B). The proximal anastomosis was end-to-side to the brachial artery, 5 cm above the pseudoaneurysm (Figure 1C). The length of the vein graft was 17 cm and it was passed subcutaneously to the medial part. The distal anastomosis was end-to-side to the ulnar artery (5 cm below the pseudoaneurysm) (figure 1D). The approach to the pseudoaneurysm began after a new midline arm incision (Figure 2A). During resection, it was noted that the pseudoaneurysm (7 cm in diameter) was partially thrombosed and also involved the previous prosthetic graft anastomosis (figure 2B).

The postoperative evolution of the patient was uneventful with complete wound healing.

Six months later, the patient had a good functional left upper limb (Figure 3A) and an extra-anatomic brachial-ulnar artery

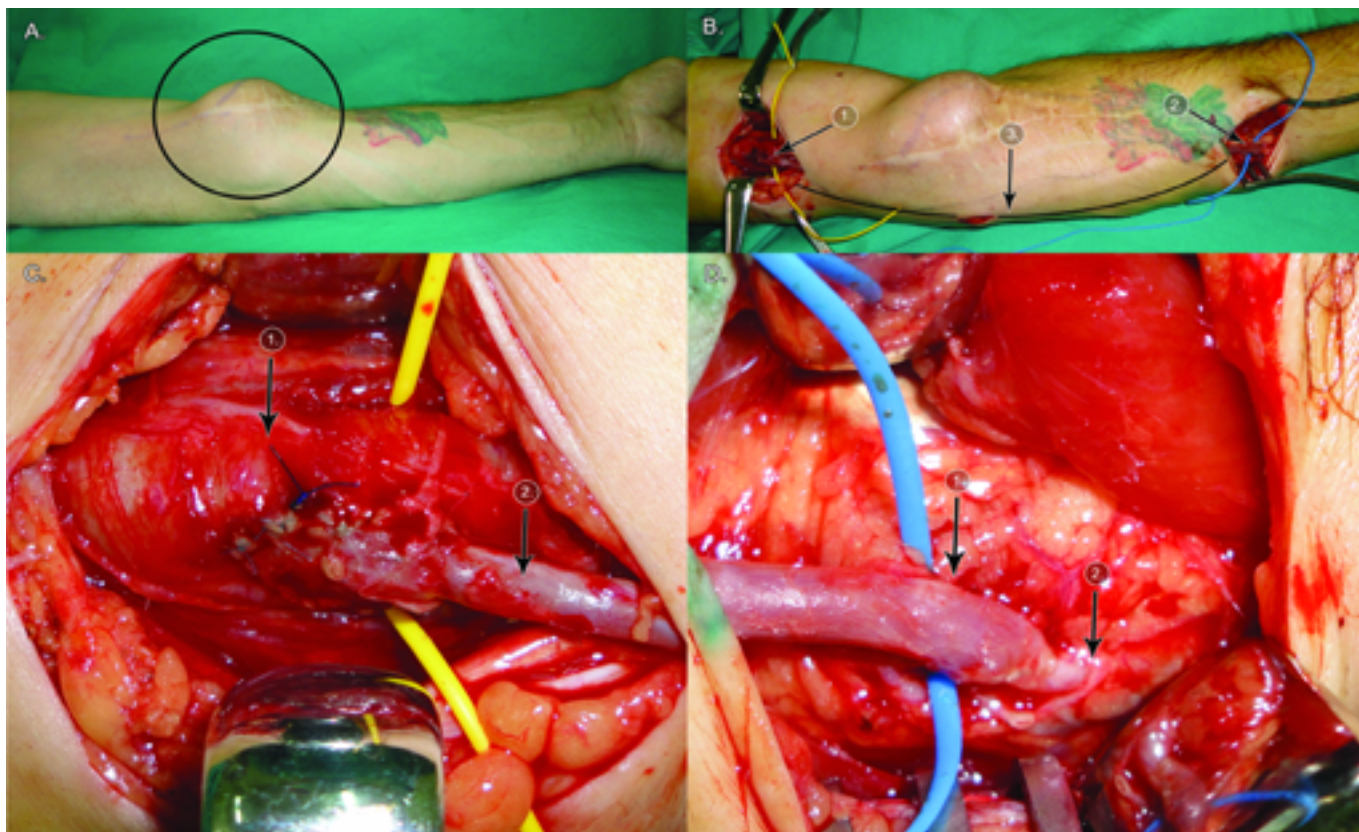


Figure 1 A. Preoperative aspect of brachial pseudoaneurysm (circle) ; B. Extra- anatomic brahial-ular artery bypass (arrow 3); C. Proximal anastomosis (arrow 1- brachial artery and arrow 2- vein graft); D. Distal anastomosis (arrow 1- vein graft and arrow 2- ulnar artery).

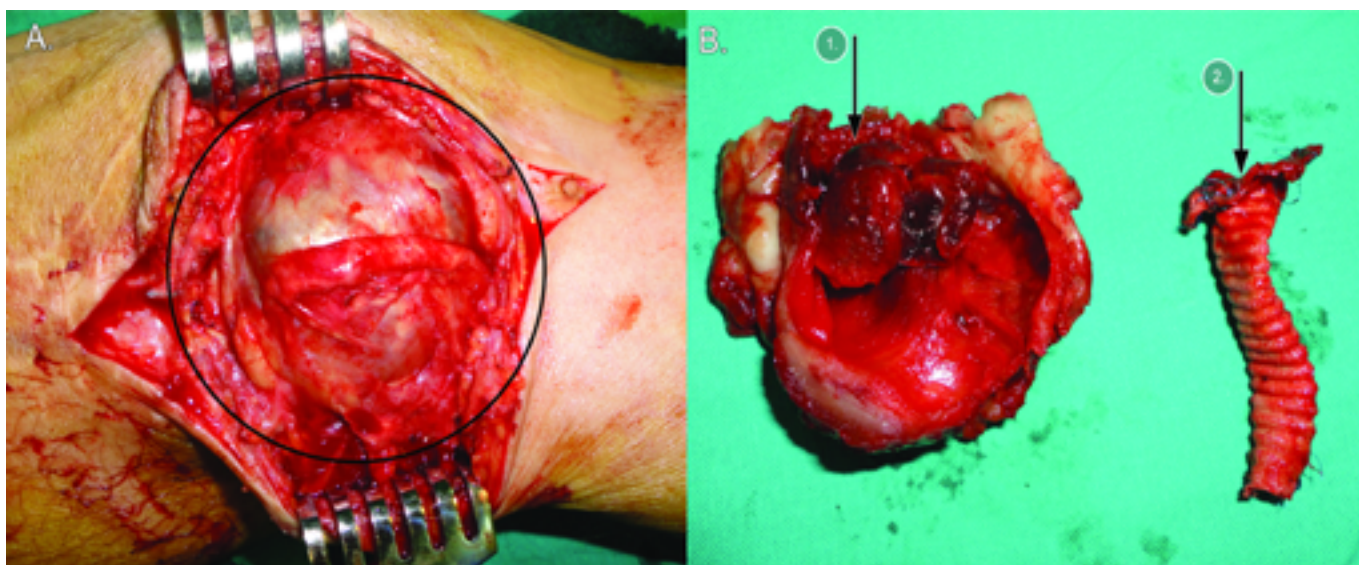


Figure 2 A. Dissected brachial pseudoaneurysm (circle); B. Partial thrombosed pseudoaneurysm (arrow 1) and prosthetic graft (arrow 2).

bypass with adequate blood flow in the forearm and palmar arch, as revealed by arteriography (figure 3B-D). The patient agreed for using his medical data for scientific aim.

**Discussion**

The main complications of synthetic grafts used for AVF include stenosis with possible thrombosis, infection and hand ischemic

syndrome due to a vascular steal mechanism. Neuropathy (especially of the median nerve), increased venous pressure in the upper limb and pseudoaneurysms represent other rare complications. Small pseudoaneurysms (< 1 cm in diameter) can be followed-up without surgical treatment. Larger pseudoaneurysms (> 1 cm in diameter) need surgery because of thrombotic and hemorrhagic risks. The methods of treatment are endovascular or classic (Mittal et al 2012). Percutaneous stent application with the preservation



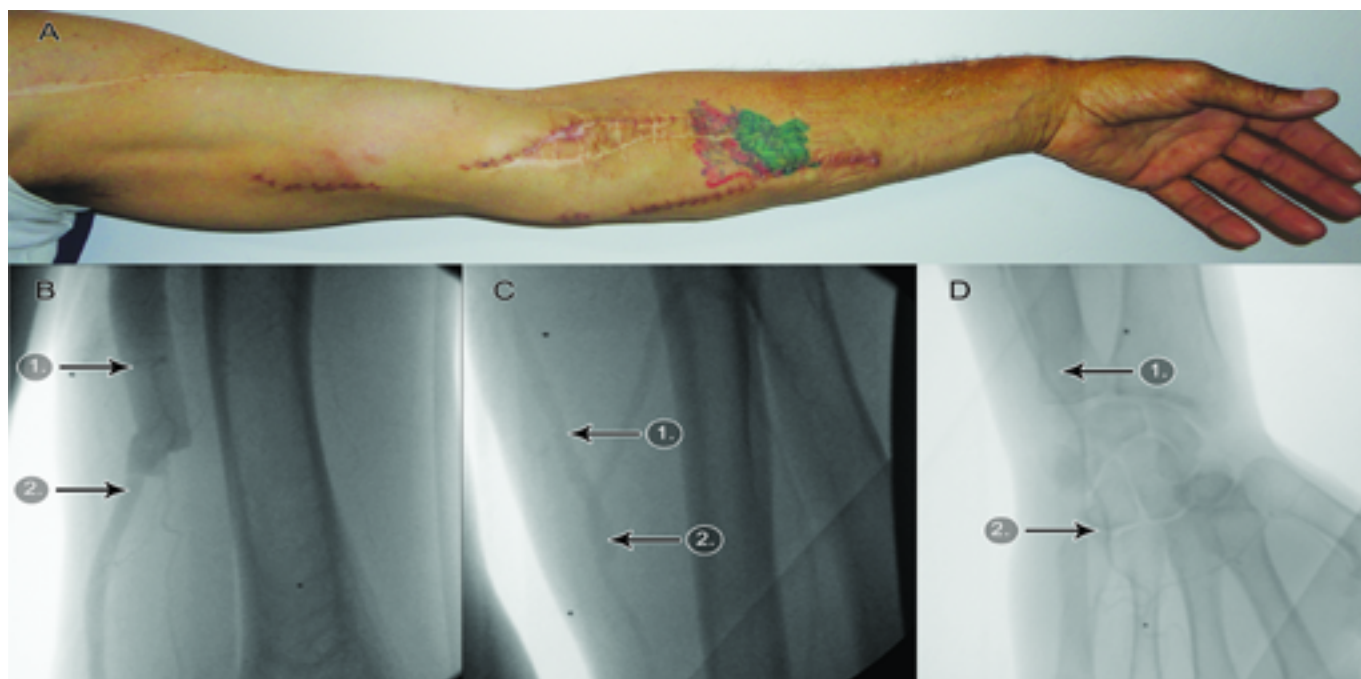


Figure 3 Six months postoperatively : A. Functional upper limb; B. Arm arteriography (arrow 1- brachial artery, arrow 2- vein graft); C. Forearm arteriography (arrow 1- vein graft, arrow 2- ulnar artery); D. Hand arteriography (arrow 1- ulnar artery, arrow-2 arterial palmar arch).

of arteriovenous fistula permeability is the first endovascular treatment choice (Tsetis 2010). In selected cases, pseudoaneurysms can be closed by ultrasound-guided thrombin injection. In both situations, the diameter of the pseudoaneurysm should be below 5 cm (Mittal et al 2012). In our case, as the pseudoaneurysm was 7 cm in diameter, we opted for classical surgery. The reconstruction of the brachial artery is rarely reported in the medical literature. Revision surgery of pseudoaneurysms requires the resection of the modified segment followed by primary suture or graft interposition. Autologous vein graft is the first option for revision surgery in case of AVF complication. Although the prosthetic graft can be an option, it is not preferred due to difficult vascular access for long-term dialysis (Scali et al 2013, Hughes et al 2007).

In the case of large brachial pseudoaneurysms with thrombosis and important associated scar tissue, an extra-anatomic by-pass is indicated before resection in order to avoid median nerve lesion and the ischemic time of the upper limb. We performed an extra-anatomic brachial-ulnar artery bypass because of radial artery thrombosis. The great saphenous vein was used as conduit for bypass because it has long-term patency compared with synthetic grafts when calciphylaxis in end-stage renal disease is present (Ong et al 2012). The arteriography revealed good hand revascularization.

## Conclusion

The extra-anatomic brachial-ulnar artery bypass is useful for saving upper limb extremities in patients with a large brachial pseudoaneurysm developed after revision surgery for AVF.

## References

Amorim P, Sousa G, Vieira J et al., Complications of vascular access for hemodialysis - Limits, imagination and commitment. *Rev Port Cir Cardiorac Vasc* 2013; 20(4):211-219.

Bahia SS, Tomei F, Ozdemir BA et al. Acute limb ischaemia due to focal brachial artery aneurysms complicating brachiocephalic arteriovenous fistula ligation: two recent case reports. *J Vasc Access* 2014;15(5):427-430.

Hughes K, Hamdan A, Schermerhorn M et al. Bypass for chronic ischemia of the upper extremity: results in 20 patients. *J Vasc Surg* 2007;46(2): p. 303-307.

Lijftogt N, Cancrinus E, Hoogervorst EL et al. Median nerve neuropraxia by a large false brachial artery aneurysm. *Vascular* 2014;22(5):378-380.

Mittal R, Stephen E, Keshava SN et al. Percutaneous cyanoacrylate glue embolization for peripheral pseudoaneurysms: an alternative treatment. *Indian J Surg* 2012;74(6):483-485.

Murphy F. The ongoing challenges with renal vascular access. *Br J Nurs* 2011;20(4):6-10.

Ong S, Coulson IH. Diagnosis and treatment of calciphylaxis. *Skinmed* 2012; 10(3):166-170.

Scali ST, Chang CK, Raghinaru D et al. Prediction of graft patency and mortality after distal revascularization and interval ligation for hemodialysis access-related hand ischemia. *J Vasc Surg* 2013;57(2):451-458.

Sen I, Varghese VD, Stephen E et al. Recurrent peripheral embolism following nonunion of the clavicle. *Indian J Orthop* 2014;48(3):329-331.

Tsetis, D. Endovascular treatment of complications of femoral arterial access. *Cardiovasc Intervent Radiol* 2010;33(3):457-468.

## Authors

•Marius Fodor, Department of Vascular Surgery, Emergency County Hospital, 3-5 Clinicilor Street, 400006, Cluj-Napoca, Cluj, Romania, EU, email: drfodor@yahoo.com

•Dan Olinic, Department of Interventional Angiology, Emergency County Hospital, 3-5 Clinicilor Street, 400006, Cluj-Napoca, Cluj, Romania, EU, email: dolinic@yahoo.com

•Lucian Fodor, Department of Plastic Surgery, Emergency County Hospital, 3-5 Clinicilor Street, 400006, Cluj-Napoca, Cluj, Romania, EU, email: lucifodor@outlook.com

<b>Citation</b>	Fodor M, Olinic D, Fodor L. Case report: Extra-anatomic artery bypass for large brachial pseudoaneurysm related to vascular access for dialysis. HVM Bioflux 2017;9(1):16-19.
<b>Editor</b>	Ştefan C. Vesa
<b>Received</b>	9 February 2017
<b>Accepted</b>	17 February 2017
<b>Published Online</b>	February 2017
<b>Funding</b>	None reported
<b>Conflicts/ Competing Interests</b>	None reported