

# Synchronous cancers of the colon and rectum

<sup>1</sup>Daciana N. Chirilă, <sup>1</sup>Nicolae A. Turdeanu, <sup>1</sup>Nicolae A. Constantea, <sup>1</sup>Tudor R. Pop, <sup>1</sup>Sorin D. Porumbel, <sup>2</sup>Cătălina I. Bungărdean, <sup>1</sup>Bogdan Micu, <sup>1</sup>Dan Axente, <sup>3</sup>Sorin Crișan, <sup>4</sup>Constantin Ciuce

<sup>1</sup> Vth Surgical Clinic, “Iuliu Hațieganu” University of Medicine and Pharmacy, Cluj-Napoca, România; <sup>2</sup> Department of Pathology, Clinic County Hospital, Cluj-Napoca, România; <sup>3</sup> Vth Medical Clinic, “Iuliu Hațieganu” University of Medicine and Pharmacy, Cluj-Napoca, Cluj, România; <sup>4</sup> Ist Surgical Clinic, “Iuliu Hațieganu” University of Medicine and Pharmacy, Cluj-Napoca, Romania.

**Abstract.** Objective: we want to evaluate the cases with synchronous malignant tumors of the colon and rectum among the patients admitted in our hospital between 2005-2012. Material and Methods: there is a retrospective study of 20 cases diagnosed with multiple malignant tumors of the large bowel and rectum, collected from the patients observational datas. Results: 6 of these patients died in this period, but the others are still alive and in a good condition. Conclusion: in some sites the cancer has a better survival rate because of an earlier diagnosis, some of these patients develop synchronous or metachronous malignant lesions and in such cases is needed an aggressive approach. There is still a small number of multiple malignant synchronous lesions, usually met with a colorectal localisation, discovered when we investigate the entire large bowel and rectum and not only a small portion of them. A synchronous malignant lesion associated with colorectal cancer can be discovered if the lesion has symptoms or when we perform CT scan, or MRI or another imagistic method which permit the diagnosis. Also, it is important not only for metachronous lesions but for synchronous lesions not diagnosed with the first tumor, an appropriate control of the patients postoperatively, giving the patient a chance of cure.

**Key Words:** Large bowel, rectum, cancer, synchronous lesions.

**Copyright:** This is an open-access article distributed under the terms of the Creative Commons Attribution License, which permits unrestricted use, distribution, and reproduction in any medium, provided the original author and source are credited.

**Corresponding Author:** D.N. Chirilă, dacianachirila@gmail.com

## Introduction

The cancer of the large bowel and rectum accounts for 10% of cancers in men and for 11% of cancers in women. It was the second most-common site-specific cancer in Europe in 2006 (Ferlay *et al* 2007) affecting both men and women (after the breast cancer), with an increasing incidence. One study from western region of Romania revealed that the prevalence of colorectal cancer is relatively high (Fratila *et al* 2010). In men prostatic cancer was on the first place and lung cancer on the second place; in women the first and second places were for breast cancer and colorectal cancer, the third being for endometrial cancer. It is considered that the frequency of the disease increases with age, reaching a maximum around the age of 75 years. A lot of environmental and genetic factors were implicated in the epidemiology of colorectal cancer. Sporadic cancers are frequently diagnosed than the cases in which we know genetic predisposition for colorectal cancer. More than 50% of the malignant tumours arise in the large bowel. Polyps, benign tumours of the large bowel are found in 25% of the cases. A percent of 4-6% of the patients are diagnosed with synchronous cancers (Fante *et al* 1996; Hohenberger 2000). Lynch syndrome (hereditary non-polyposis colorectal cancer) is characterized by mutations that occurs in the DNA mismatch-repair genes. Until now we have information concerning five genes: MSH2 (mutS homolog 2) on chromosome 2p16; MLH1 (mutL homolog 1) on chromosome 3p21; MSH6 (mutS homolog 6) on chromosome 2p16; PMS2 (postmeiotic segregation 2) on chromosome 7p22; and

~~EPCAM or TACSTD1 gene, which is responsible for a small percentage of HNPCC cases, it's deletion mutations inactivate MSH2 (Kovacs *et al* 2009; Ligtenberg *et al* 2009). The affected members of the family tend to develop colon cancers, usually in the right colon, earlier than usually, in their 30's to 40's, being also at elevated risk for developing cancer at different sites: genital, gastric, ureter, bile ducts, brain and skin.~~

Hereditary colon cancer syndromes are caused by specific inherited mutations that can lead to colon polyps, colon cancers, and non-colonic cancers. Hereditary colon cancer syndrome is able affect multiple members of a family. It is considered that 5% of all colon cancers are due to hereditary colon cancer syndromes. Patients who have inherited one of these syndromes have an extremely high risk (90-100%) for developing colon cancer. The risk to develop a colon cancer is 6% if one first degree relative has history of colon cancer; and if there is a second cancer, the risk rises up to 17%.

For the development of colon cancer there are four different sequential mutations found: the APC gene (adenomatous polyposis coli), K-ras, DCC (deleted in colon cancer) and p53 gene. The APC gene is a tumour suppression gene, located on chromosome 5, having an autosomal dominant transmission for FAP. The p53 protein has multiple functions, among them there are: regulation of the cell growth, the repair of DNA, inhibiting the cell growth meanwhile the repair of DNA and the apoptosis. The MYH syndrome is an autosomal recessive form of colorectal adenomatous polyposis, in which the patients develop 10-100 polyps during their 40's and they are at high risk to degenerate

into colon cancer. The responsible gene is MutY Homologue located on the position 1p34.4-p32.1.

Synchronous cancers of colorectum are considered to be those diagnosed preoperatively, intraoperatively or in no more than 6 months period postoperatively. These tumours have to be separate by at least 4 cm distance one from another, without submucosal spread or a satellite lesion of each other (Cunliffe *et al* 1984). In case of not respecting these criteria the tumours are considered as regional spread or metastatic lesions.

## Material and methods

We made a retrospective study of 20 cases which underwent surgical procedures for multiple synchronous tumours of the large bowel and rectum, in a period of 7.5 years, representing 4.76% of all colorectal cancers diagnosed and treated in our hospital. In the same time there were more than 400 cases of colo-rectal cancers. The diagnosis was made on clinical examination, abdominal ultrasound, colonoscopy, barium enema and laparotomy. Only six patients underwent also a CT scan. Usually for the patients without occlusive colorectal cancer the golden standard is colonoscopy. Whenever it is present an occlusive tumour, the preparation of the bowel cannot be done, and also even a colonoscope cannot pass through the stenosis, that is why there still are cases in which the synchronous malignant tumours are not diagnosed preoperatively. Some of them may be diagnosed with a proper intraoperative exploration of the peritoneal cavity and some of them may be diagnosed after surgery with a new colonoscopy or with another occlusive abdominal tumour. 18 patients underwent surgical procedures, one has colonic biopsies and diagnosis but never came for surgical treatment and in one it was initiated a chemotherapy protocol because of advance disease.

## Results

The association of the synchronous malignant tumours were: ascendent colon and right colon angle in two, cecum and right colon flexure in two, sigmoid colon and transverse colon in two, recto-sigmoid junction and rectum in three, upper and lower rectum in one, recto-colic malignant polyposis with multiple colon cancers in two, recto-sigmoid junction and descendant colon in one, left colon angle and sigmoid in one, sigmoid colon in one, right colon angle and descendant colon in one, transverse colon and recto-sigmoidal junction in one, cecum and ascendent colon in one, cecum and descendant colon in one, right colon angle and left colon angle in one. The 2 patients with recto-colic malignant poliposis were not included in a familial syndrome. The surgical operations performed in time for these patients were: total colectomy in 3, segmentary resections in 4, enlarged left hemicolectomy in 3, right hemicolectomy in 6, Hartmann procedure in one, abdomino-perineal rectal resection in 3, ileo-sigmoidostomy in one, transversostomy in 2 and no operation in 2 (one patient underwent chemotherapy because of distant metastases and one is lost in follow-up).

There were 13 males and 7 females, with a median age of 67 (range 38-81). The cancers sites were as in Fig.2. We divided the large bowel and rectum in 9 sites: cecum, the ascendent colon, the hepatic flexure of the colon, the transverse colon, the left flexure of the colon, the descendant colon, the sigmoid

colon, the sigmoidal-rectal junction and the rectum. If we would divide the large bowel and the rectum just in two places, the right and the left colon, we would have a small preponderance of the malignant tumours located on the left side.

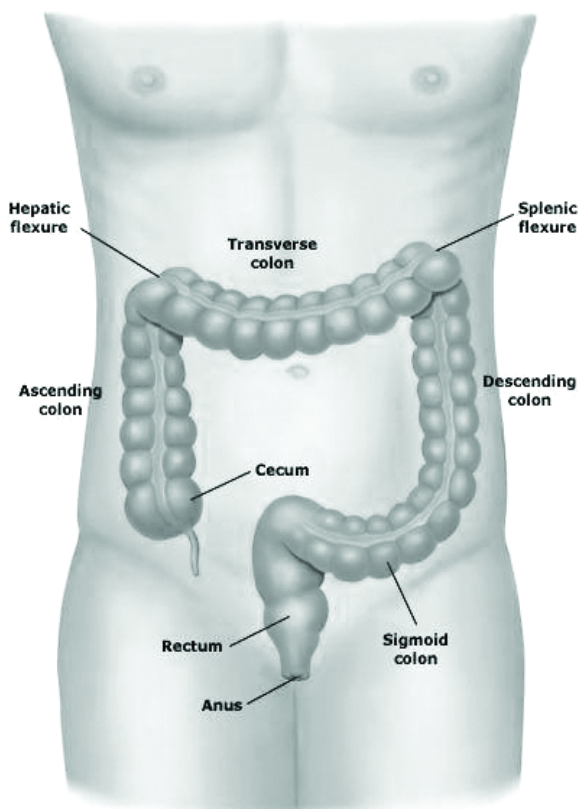


Figure 1. The anatomical sections of the large intestine

There were 13 males and 7 females, with a median age of 67 (range 38-81). The cancers sites were as in Fig.2. We divided the large bowel and rectum in 9 sites: cecum, the ascendent colon, the hepatic flexure of the colon, the transverse colon, the left flexure of the colon, the descendant colon, the sigmoid colon, the sigmoidal-rectal junction and the rectum. If we would divide the large bowel and the rectum just in two places, the right and the left colon, we would have a small preponderance of the malignant tumours located on the left side.

There were 53 tumours most of them on left side of the bowel. An interesting case was that of the patient B.I., diagnosed with 4 large bowel cancers (villous and tubulo-villous adenocarcinoma) 2 cancers on the sigmoid colon, one on the descendant colon and one on the transverse colon, for which was performed a left hemicolectomy with transverso-rectoanastomosis; one year later at a colonoscopic control were found 2 additional cancers (tubulo-vilous adenocarcinoma), one on the transverse colon and the other on the cecum, for which it was performed a right hemicolectomy and also a rectal resection, so it was completed a total rectocolectomy with ileo-anal mechanical anastomosis. Another patient, R.M. diagnosed after a colonoscopy with a recto-sigmoidal malignant tumour with stenosis for which was performed a recto-sigmoidectomy with anastomosis, developed after 4 weeks a cecal diastatic perforation for which was performed a cecostomy.

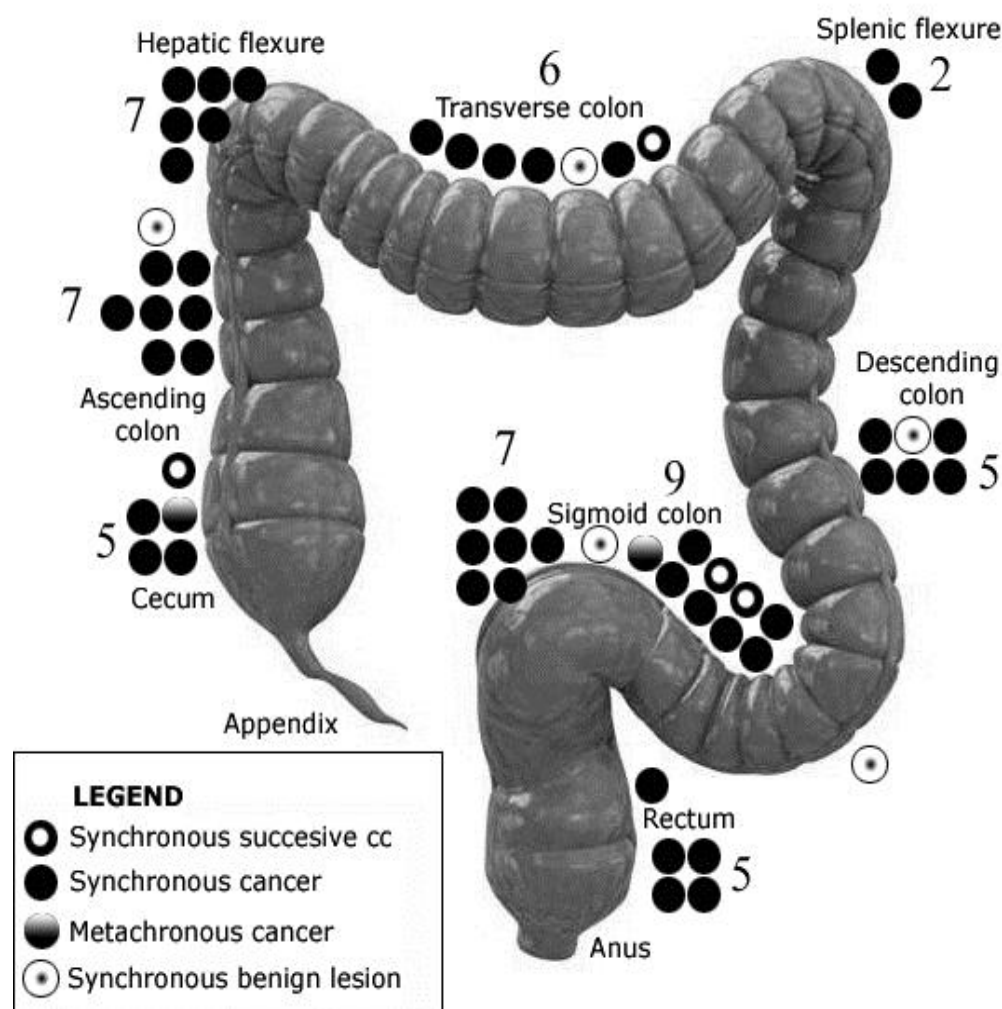


Figure 2. The localisation of colorectal malignant tumours, either synchronous or metachronous for the 20 patients; in the figure are represented also the synchronous benign colorectal tumours (polyps)

The perforation appeared because of an occlusive tumor of the transverse colon, for which it was performed 6 weeks later a segmentary transverse colon resection with transverse colostomy, closed later. This was a typical case of an incomplete diagnosis before surgery and in time of surgery.

This happened because of intestinal occlusion at presentation and a big malignant recto-sigmoidal tumour which did not allow the passage of the endoscope through the tumour and in time of surgical intervention was not performed a careful investigation of the entire colon. The patient is well, 4 years after surgery.

In 2 patients was performed a total colectomy with a J pouch ileo-rectal anastomosis because of multiple tumours, benign (polyps) and malignant.

The surgical treatment for the synchronous colorectal cancers were segmentary resections with restoration of the bowel continuity usually end-to-end, most of them performed manually and in one patient mechanically, in 2 cases at the level of the transverse colon and other 2 on the sigmoid colon; right (6 patients) or left (3 patients) hemicolectomies; total colectomy with ileo-rectal anastomosis in one patient, with ileal J-pouch in 2 patients (Chirilă *et al* 2012); internal by-pass (side-to-side ileo-sigmoidal anastomosis) in one patient; Hartmann resections in 2 patients;

external palliative derivation in 2 patient and in one patient a loop sigmoidostomy after a recto-sigmoidal resection in order to protect the anastomosis. Other surgical procedures done with colorectal procedures were: bilateral adnexectomy in one patient, cholecystectomy in one patient, partial cystectomy in one patient, abdominal wall hernia repair in one patient, adherential syndrome lysis in 4 patients. Some of the patients had secondary neoplasms, especially liver metastases (6 patients), pulmonary metastases (2 patients), or other sites (peritoneal carcinomatosis in 2 patients). The postoperatively complications were: fistula in 2 patients, recovered with medical treatment; an evisceration with second suture of the abdominal wall in one patient; and wound infection in 3 patients. One patient died within 30 days postoperatively because of a stroke. Associated diseases were described in many patients. The most frequent was ischaemic heart disease and hypertension in 6 patients, diabetes mellitus in 6 patients, dislipidemia in 2 patients, in two patients it was diagnosed an alteration of the glucose metabolism, liver cirrhosis in 2 patients, renal chronic failure in 2 patients, bronchial asthma in one patient. The histopathological examination revealed tubular, tubular-vilous, tubulopapillary adenocarcinoma, most of them with mild differentiation and some of them poor differentiated.

In the patients with colorectal polyposis were diagnosed also tubular adenomas, tubulo-villous adenomas with displazia. The patients with colorectal malignant tumours had stage I of disease in 1 patient, stage IIA of disease in 4 patients, stage IIIB in 5 patients, IIIC in one patient and stage IV in 8 patients. One patient did not come for surgical treatment, even if she was diagnosed with synchronous malignant tumours of the right flexure of the colon and the descendant colon (tubular adenocarcinoma). The multiple colorectal malignant tumours were staged according to TNM staging from the American Joint Committee on Cancer (AJCC 2002). The stage was considered the most advanced stage of the tumours, even if there were 6 different stages malignant tumours. Nowadays are still alive only 14 patients, even if some of them are diagnosed with metastases, the most common site being the liver; one patient with liver cirrhosis.

## Discussions

Colorectal cancer was the fourth most common cancer in men and the third most common cancer in women worldwide (Parkin *et al* 2005), even if both incidence and death rates declined not only for colorectal cancer but also for lung cancer, prostate cancer and breast cancer (Jemal *et al* 2008). In 2008 colorectal cancer occupied the third place in men and the second in women (Jemal *et al* 2011). Usually, men have the incidence and mortality rates higher than females. The highest incidence rates were found in 2008 in Australia and New Zealand, Europe, and North America, and the lowest rates were found in Africa and South-Central Asia (Ferlay *et al* 2010). Colorectal cancer incidence rates have increased in some areas previously considered at low risk, among them Spain and some countries within Eastern Asia and Eastern Europe (Center *et al* 2009a). This could have an explanation in changes in dietary patterns, obesity, an increased prevalence of smoking and maybe other factors or combination of them. In the United States was obtained, through an early detection and removal of the premalignant colorectal lesions because of cancer screening, a decrease in the incidence rates for both sexes (Center *et al* 2009b).

Billroth has described for the first time in 1879 a case with multiple malignant tumours in a patient (Billroth 1889, cited by Varty *et al* 1994).

The incidence of multiple primary cancers diagnosed in the colon and rectum is observed between 2 to 5% (Takeuchi *et al* 1997; Chen and Sheen-Chen, 2000; Ueno *et al* 2003; Wang *et al* 2004; Tziris *et al* 2008). This incidence increases to 10-20% in patients with familiar adenomatous polyposis, hereditary non-polyposis, colorectal cancer, and ulcerative colitis (Yoon *et al* 2008). The synchronous colorectal benign neoplasms are frequently reported. The reported incidence of synchronous colorectal carcinoma ranged between 1.7 and 12.4% (Ekelund and Pihl 1974; Welch, 1981; Cunliffe *et al* 1984; Eu *et al* 1993; Hennekinne-Mucci *et al* 2006; Piñol *et al* 2004).

In the period of time studied by us we had more than 500 cases of colorectal malignant tumours, admitted and most of them underwent surgery. There were only 5 cases of metachronous colorectal lesions. Also, in our series, three patients developed metachronous malignant tumours and some of them were synchronously discovered. The survival for patients with synchronous colon cancers was observed to be similar as for

patients with solitary colon tumours, considering the highest stage synchronous tumor (Passman *et al* 1996).

The diagnosis of colorectal malignancies in case of bowel obstruction with incomplete colonoscopy may be obtained with CT colonography, a method with a good quality of images and significant accuracy, being very well tolerated and it is less invasive Neri *et al* 2002; Copel *et al* 2007; Nagata *et al* 2007). We did not perform any CT colonography. The diagnosis in cases without obstruction (15 cases) was made on colonoscopy and barium enema, in the remainder of cases was made either by rectoscopy, or sigmoidoscopy or intraoperatively because of bowel obstruction. It is known that colonoscopy represents the golden standard for the diagnosis of colorectal malignant tumours, because if it is done for the entire colon may reveal any malignant or benign neoplasm, allowing also to perform biopsies which can reveal the type of the tumor. A CT-colonography may be less invasive, better tolerated by cannot allow the performing the biopsies. For the diagnosis it is very useful especially in cases with obstructing tumours, being impossible for the colonoscope to pass through the stenosis into the more proximal segments of the large bowel.

It was observed that the patients with a first tumour located within the proximal colon had a twofold increased the risk for developing metachronous colorectal cancer (Gervaz *et al* 2005). In our series we had also metachronous malignant lesions, some of them synchronously appeared when they were multiple. Also, considering from the point of view of synchronous cancers, there were patients who developed earlier another malignant colorectal tumour.

Our series consists of a small number of patients with synchronous colorectal malignant tumours collected in more than 7 years from a larger number of patients having a colorectal cancer. Usually, colorectal cancer presents alone, as a singular cancer, but in certain conditions (FAP, colorectal polyposis, Lynch syndromes) it may appear multiple cancers with a large bowel localization. We had only one patient diagnosed with familial adenomatous polyposis and other two patients with colorectal malignant polyposis. In this series we had no patient diagnosed with multiple colorectal cancers, part of a hereditary non-polyposis colorectal syndrome. In literature it was sustained that the survival may be better for patients with multiple colorectal tumours (Nikoloudis *et al* 2004) because of an appropriate control of patients. Women have better survival rate than men, and in some series the synchronous cancer is located in the right colon (Derwinger and Gustavsson 2011). We have diagnosed metachronous colorectal cancer because of the surveillance of a previous cancer in 4 patients. In 2 patients the synchronous cancer not diagnosed preoperatively, but it was discovered through an appropriate exploration of the peritoneal cavity. In another case, the synchronous cancer was diagnosed only after a small period of time because of bowel obstruction. This has to underline the importance of a proper exploration of peritoneal cavity, especially in patients without an entire bowel exploration through colonoscopy or CT scan performed preoperatively, usually because of bowel obstruction. The colonoscopy of the entire large bowel and rectum has to be done in order to avoid the remaining in place of a possible tumour (Grodos and Haot 1987), either benign or especially malignant synchronous lesion. Also, colonoscopy has to be made periodically for the residual colon all the rest of patient life

(Evers *et al* 1988) because of metachronous malignant lesions. Many patients had also associated diseases, some of them in advanced stages. The patient lost within 30 days from surgical intervention died because of a stroke, being diagnosed with severe heart disease, atherosclerosis, and arterial hypertension. Our death rate was due to a stage IV of cancer disease. Also, we still have patients diagnosed with liver metastases which are alive 2 or 3 years after the colorectal surgery. The patient diagnosed before surgery with liver cirrhosis is still alive.

It is interesting that even if the patients were not diagnosed with FAP, many of them presented a lot of polyps from which many cancers developed, some of them in same time and some after a period. These patients suffered iterative operations in time, usually not many years after, this giving the advice of performing larger operations and an appropriate surveillance. In cases where a total colonoscopy is impossible to make because of an obstruction and presentation in emergency, we need to perform the entire colonoscopy after surgery because of possible synchronous malignant lesions which cannot be intraoperative discovered by manual palpation. It was said that colonoscopy combined with intraoperative palpation of the entire large bowel are recommended for an early detection of synchronous malignant tumours (Chen *et al* 2000). A more aggressive surgical approach means performing a total colectomy with an ileo-rectal anastomosis, and, where polyps or other lesions are present in the rectum, we could perform a rectocolectomy or even a proctocolectomy with ileostomy.

## Conclusions

Whenever we have a diagnosis of colorectal cancer we have to look for a possible synchronous neoplasm, especially malignant lesions. In order to do this it is necessary to perform an appropriate exploration, clinically and endoscopically. If an entire colonoscopy cannot be done preoperatively, we have an alternative with CT colonography. Also, the intraoperatively exploration of the peritoneal cavity is very important, because it may reveal other synchronous lesions, either benign or malignant, in colorectum or in another place. The clinical surveillance with periodically endoscopy may also diagnose in an useful therapeutic stage a metachronous colorectal malignant lesion. Also, we have to keep in mind that a patient already diagnosed with a colorectal cancer may develop another malignant lesion somewhere else in his/her body.

## References

- AJCC Cancer Staging Manual (Sixth ed.). Springer-Verlag New York, Inc. 2002.
- Billroth, T., 1889. Allgemeine chirurgie pathologie UHD therapie. Reimer 908.
- Bussey, H. J., Wallace, M. H., Morson, B. C., 1967. Metachronous carcinoma of the large intestine and intestinal polyps. *Proc R Soc Med* 60:208-210.
- Bussey, H. J. R., 1975. *Familial Polyposis Coli*. Baltimore: The Johns Hopkins University.
- Center, M. M., Jemal, A., Ward, E., 2009a. International trends in colorectal cancer incidence rates. *Cancer Epidemiol Biomarkers Prev* 18:1688-1694.
- Center, M. M., Jemal, A., Smith, R. A., Ward, E., 2009b. Worldwide variations in colorectal cancer. *CA Cancer J Clin* 59:366-378.
- Chen, H. S., Sheen-Chen, S. M., 2000. Synchronous and "early" metachronous colorectal adenocarcinoma: analysis of prognosis and current trends. *Dis Colon Rectum* 43(8):1093-9.
- Chirilă D. N., Bungărdean C. I., Pop T. P., and Constantea N., 2012. Total colectomy with „J”-reservoir for synchronous neoplasia of the large bowel and rectum. *HVM Bioflux* 4(2):68-75.
- Copel, L., Sosna, J., Kruskal, J. B., Raptopoulos, V., Farrell, R. J., Morrin, M. M., 2007. CT colonography in 546 patients with incomplete colonoscopy. *Radiology* 244:471-478.
- Cunliffe, W. J., Hasleton, P. S., Tweedle, D. E., Schofield, P. F., 1984. Incidence of synchronous and metachronous colorectal carcinoma. *Br J Surg* 71:941-3.
- Derwinger, K., Gustavsson, B., 2011. A study of aspects on gender and prognosis in synchronous colorectal cancer. *Clin Med Insights Oncol* 5:259-64.
- Edwards, B. K., Ward, E., Kohler, B. A., Ehemann, C., Zauber, A. G., Anderson, R. N., et al, 2010. Annual report to the nation on the status of cancer, 1975-2006, featuring colorectal cancer trends and impact of interventions (risk factors, screening, and treatment) to reduce future rates. *Cancer* 116(3):544-573.
- Ekelund, G. R., Pihl B., 1974. Multiple carcinomas of the colon and rectum. *Cancer* 33:1630-1634.
- Eu, K. W., Seow-Choen, F. and Goh, H. S., 1993. Synchronous colorectal cancer in an oriental population. *Int J Colorect Dis* 8(4):193-196.
- Evers, B. M., Mullins, R. J., Matthews, T. H., Broghamer, W. L. and Polk, H. C., 1988. Multiple adenocarcinomas of the colon and rectum. An analysis of incidences and current trends. *Dis Colon&Rectum* 31(7):518-522.
- Fante, R., Roncucci, L., Di Gregorio, C., Tamassia, M.G., Losi, L., Benatti, P., et al, 1996. Frequency and clinical features of multiple tumours of the large bowel in the general population and in patients with hereditary colorectal carcinoma. *Cancer* 77(10):2013-21.
- Ferlay, J., Autier, P., Boniol, M., Heanue, M., Colombet, M., Boyle, P., 2007. Estimates of the cancer incidence and mortality in Europe in 2006. *Ann Oncol* 18:581-92.
- Ferlay, J., Shin, H. R., Bray, F., Forman, D., Mathers, C. and Parkin, D. M., 2010. GLOBOCAN 2008 v1.2, Cancer Incidence and Mortality Worldwide: IARC CancerBase No. 10 [Internet]. Lyon, France: International Agency for Research on Cancer. Available at: <http://globocan.iarc.fr>. 2010.
- Fratila, O., Straciuc, O., Puscasiu, M., Ilias, T., 2010. Endoscopic and histopathologic correlations in colonic cancer. *Annals of RSCB* 15(2):41-47.
- Gervaz, P., Bucher, P., Neyroud-Caspar, I., Soravia, C., Morel, P., 2005. Proximal location of colon cancer is a risk factor for development of metachronous colorectal cancer: a population-based study. *Dis Colon Rectum* 48(2):227-32.
- Glenn, F., McSherry, C. K., 1966. Carcinoma of the distal large bowel. *Ann Surg* 163:838-849.
- Goldgraber, M. B., Kirsner, J. B., 1964. Carcinoma of the colon in ulcerative colitis. *Cancer* 17:657-665.
- Gómez Iglesias, S., Cuñat Albert, E., Torregrosa Puerta, S., Lozano Requena, J. A., Tovar Gómez, O., Del Pino Porres, J., 1989. Synchronous multiple carcinomas of the colon and rectum. Presentation of 18 cases and review of the literature. *Rev Esp Enferm Apar Dig* 76(4):316-20.
- Greenstein, A. J., Sachar, D. B., Pucillo, A., Vassiliades, G., Smith, H., Kreef, I., Geller, S. A., Janowitz, H. D., Aufses, A. H. Jr., 1979. Cancer in universal and left-sided ulcerative colitis: clinical and pathological features. *Mt Sinai J Med* 45:25-32.

- Greenstein, A. J., Slater, G., Heimann, T. M., Sachar, D. B., and Aufses, A. H. Jr., 1986. A comparison of multiple synchronous colorectal cancer in ulcerative colitis, familial polyposis coli, and de novo cancer. *Ann Surg.* 203(2):123–128.
- Grodos, J. and Haot, J., 1987. Synchronous cancers of the colon. *ACTA ENDOSCOPICA* 17(1):11-17.
- Hayes, J. D., Pulford, D. J., 1995. The glutathione S-transferase supergene family: regulation of GST and the contribution of the isoenzymes to cancer chemoprotection and drug resistance. *Crit Rev Biochem Mol Biol* 30(6):445-600.
- Harries, L. W., Stubbins, M. J., Forman, D., Howard, G. C., Wolf, C. R., 1997. Identification of genetic polymorphisms at the glutathione S-transferase Pi locus and association with susceptibility to bladder, testicular and prostate cancer. *Carcinogenesis* 18:641–4.
- Heald, R. J., Bussey, H. J. R., 1975. Clinical experiences at St. Mark's Hospital with multiple synchronous cancers of the colon and rectum. *Dis Colon Rectum* 18:6-10.
- Hennekinne-Mucci, S., Tuech, J. J., Brehant, O., Lermite, E., Bergamaschi, R., Pessaux, P., Arnaud, J. P., 2006. Emergency subtotal/total colectomy in the management of obstructed left colon carcinoma. *Int J Colorectal Dis* 21:538–541.
- Jemal, A., Thun, M. J., Ries, L. A., Howe, H. L., Weir, H. K., Center, M. M., et al, 2008. Annual report to the nation on the status of cancer, 1975-2005, featuring trends in lung cancer, tobacco use, and tobacco control. *J Natl Cancer Inst.* 100:1672-1694.
- Jemal, A., Bray, F., Center, M. M., Ferlay, J., Ward, E., Forman, D., 2011. *Global Cancer Statistics* CA Cancer J Clin 61:69–90.
- Kovacs, M. E., Papp, J., Szentirmay, Z., Otto, S., Olah, E., 2009. Deletions removing the last exon of TACSTD1 constitute a distinct class of mutations predisposing to Lynch syndrome. *Hum Mutat* 30(2):197-203.
- Latournerie, M., Jooste, V., Cottet, V., Lepage, C., Faivre, J., Bouvier, A. M., 2008. Epidemiology and prognosis of synchronous colorectal cancers. *Br J Surg* 95(12):1528-33.
- Ligtenberg, M. J., Kuiper, R. P., Chan, T. L., Goossens, M., Hebeda, K. M., Voorendt, M., et al, 2009. Heritable somatic methylation and inactivation of MSH2 in families with Lynch syndrome due to deletion of the 3' exons of TACSTD1. *Nat Genet* 41(1):112-7.
- McSherry, C. K., Cornell, G. J., Glenn, F., 1969. Carcinoma of the colon and rectum. *Ann Surg* 169: 502-509.
- Meyer, D. J., Coles, B., Pemble, S. E., Gilmore, K. S., Fraser, G. M., Ketterer, B., 1991. Theta, a new class of glutathione transferases purified from rat and man. *Biochem. J* 274:409-414.
- Moertel, C. G., Bargaen, J. A., Dockerty, M. B., 1958. Multiple carcinomas of the large intestine: a review of the literature and a study of 261 cases. *Gastroenterology* 34:85-98.
- Nagata, K., Endo, S., Ichikawa, T., Dasai, K., Moriya, K., Kushihashi, T., Kudo, S. E., 2007. Polyethylene glycol solution (PEG) plus contrast medium vs PEG alone preparation for CT colonography and conventional colonoscopy in preoperative colorectal cancer staging. *Int J Colorectal Dis* 22:69–76.
- Neri, E., Giusti, P., Battolla, L., Vagli, P., Boraschi, P., Lencioni, R., Caramella, D., Bartolozzi, C., 2002. Colorectal cancer: role of CT colonography in preoperative evaluation after incomplete colonoscopy. *Radiology* 223:615–619.
- Nikoloudis, N., Saliangas, K., Economou, A., Andreadis, E., Siminou, S., Manna, I., Georgakis, K., Chrissidis, T., 2004. Synchronous colorectal cancer. *Tech Coloproctol* 8 Suppl 1:s177-9.
- Norrie, M. W., Hawkins, N. J., Todd, A. V., Meagher, A. P., O'Connor, T. W., Ward, R. L., 2002. The role of hMLH1 methylation in the development of synchronous sporadic colorectal carcinomas. *Dis Colon Rectum* 45(5):674-80.
- Oya, M., Takahashi, S., Okuyama, T., Yamaguchi, M., Ueda, Y., 2003. Synchronous Colorectal Carcinoma: Clinico-pathological Features and Prognosis. *Jpn J Clin Oncol* 33(1):38–43
- Parkin, D. M., Bray, F., Ferlay, J., Pisani, P., 2005. Global cancer statistics, 2002. *CA Cancer J Clin* 55: 74–108.
- Passman, M. A., Pommier, R. F., Vetto, J. T. 1996. Synchronous colon primaries have the same prognosis as solitary colon cancers. *Dis Colon&Rectum* 39(3):329-334.
- Ritchie, J. K., Hawley, P. R., Lennard-Jone, J. E., 1981. Prognosis of carcinoma in ulcerative colitis. *Gut* 22:752-755.
- Takeuchi, H., Toda, T., Nagasaki, S., Kawano, T., Minamisono, Y., Maehara, Y., Sugimachi, K., 1997. Synchronous multiple colorectal adenocarcinomas. *J Surg Oncol* 64(4):304-7.
- Tziris, N., Dokmetzioglou, J., Giannoulis, K., Kesiosoglou, I., Sapalidis, K., Kotidis, E., Gambros, O., 2008. Synchronous and metachronous adenocarcinomas of the large intestine. *Hippokratia* 12(3):150-2.
- Ueno, M., Muto, T., Oya, M., Ota, H., Azekura, K., Yamaguchi, T., 2003. Multiple primary cancer: an experience at the Cancer Institute Hospital with special reference to colorectal cancer. *Int J Clin Oncol* 8:162–167.
- Varty, P. P., Boulos, P. B., Delrio, P., 1994. Survival in colorectal carcinoma associated with previous extracolonic cancer. *Ann R Coll Surg Engl* 76:180-184.
- Wang, H. Z., Huang, X. F., Wang, Y., Ji, J. F., Gu, J., 2004. Clinical features, diagnosis, treatment and prognosis of multiple primary colorectal carcinoma. *World J Gastroenterol* 10(14):2136-9.
- Wang, H., Zhang, Z. G., Song, C., Wang, B., 2006. Clinical research of synchronous colorectal neoplasms. *Zhonghua Wai Ke Za Zhi* 44(21): 1498-500.
- Welch, J. P., 1981. Multiple colorectal tumours . An appraisal of natural history and therapeutic options. *Am J Surg*;142:274–80.
- West, N. J., Boustiere, C., Fischbach, W., Parente, F., Leicester, R. J., 2009. Colorectal cancer screening in Europe: differences in approach; similar barriers to overcome. *Int J Colorectal Dis* 24:731-740.
- Yalcinkaya, U., Ozturk, E., Ozturk, T., Yerci, O., Yilmazlar, T., 2008. P53 expression in synchronous colorectal cancer. *Saudi Med J* 29(6):826-31.
- Yamamoto, S., Yoshimura, K., Ri, S., Fujita, S., Akasu, T., Moriya, Y., 2006. The risk of multiple primary malignancies with colorectal carcinoma. *Dis Colon Rectum* 49(10 Suppl):S30-6.
- Yoon, J. W., Lee, S. H., Ahn, B. K., Baek, S. U., 2008. Clinical characteristics of multiple primary colorectal cancers. *Cancer Res Treat* 40(2):71-4.

## Authors

- Daciana N. Chirilă, „Iuliu Hațieganu” University of Medicine and Pharmacy, Cluj-Napoca, Department of Surgery, 5th Surgical Clinic, 11th Tăbăcarilor Street, 400139, Cluj-Napoca, Romania, EU, e-mail: dacianachirila@gmail.com
- Nicolae A. Turdeanu, „Iuliu Hațieganu” University of Medicine and Pharmacy, Cluj-Napoca, Department of Surgery, 5th Surgical Clinic, 11th Tăbăcarilor Street, 400139, Cluj-Napoca, Romania, EU, e-mail: turdeanustela@yahoo.com
- Nicolae A. Constantea, „Iuliu Hațieganu” University of Medicine and Pharmacy, Cluj-Napoca, Department of Surgery, 5th Surgical Clinic, 11th Tăbăcarilor Street, 400139, Cluj-Napoca, Romania, EU, e-mail: nicuconstantea@yahoo.com
- Tudor R. Pop, „Iuliu Hațieganu” University of Medicine and Pharmacy, Cluj-Napoca, Department of Surgery, 5th Surgical

Clinic, 11th Tăbăcarilor Street, 400139, Cluj-Napoca, Romania, EU, e-mail: poptudor\_2003@yahoo.com

•Sorin D. Porumbel, 5th Surgical Clinic, 11th Tăbăcarilor Street, 400139, Cluj-Napoca, Romania, EU, e-mail: sorinporumbel@yahoo.com

•Cătălina I. Bungărdean: Municipal Clinical Hospital, Department of Pathology, 11th Tăbăcarilor Street, 400139, Cluj-Napoca, Romania, EU, e-mail: mariabun2002@yahoo.com

•Bogdan Micu, „Iuliu Hațieganu” University of Medicine and Pharmacy, Cluj-Napoca, Department of Surgery, 5th Surgical Clinic, 11th Tăbăcarilor Street, 400139, Cluj-Napoca, Romania, EU, e-mail: micubogdan@yahoo.com

•Dan Axente, „Iuliu Hațieganu” University of Medicine and Pharmacy, Cluj-Napoca, Department of Surgery, 5th Surgical Clinic, 11th Tăbăcarilor Street, 400139, Cluj-Napoca, Romania, EU, e-mail: d\_axente@yahoo.com

•Sorin Crișan, Department of Internal Medicine, 5th Medical Clinic, Municipal Hospital, „Iuliu Hațieganu” University of Medicine and Pharmacy, 11th Tăbăcarilor Street, 400139, Cluj-Napoca, Cluj, Romania, EU, email: crisan.sorin@gmail.com

•Ciuce Constantin, „Iuliu Hațieganu” University of Medicine and Pharmacy, Cluj-Napoca, Department of Surgery, 1st Surgical Clinic, 3-5th Clinicilor Street, 400139, Cluj-Napoca, Romania, EU, e-mail: cciuce@umfcluj.ro

**Citation** Chirilă, D. N., Turdeanu, N. A., Constantea, N. A., Pop, T. R., Porumbel, S. D., Bungărdean, C. I., Micu, B., Axente, D., Crișan, S., Ciuce, C., 2012. Synchronous cancers of the colon and rectum and other sites. *HVM Bioflux* 4(3):83-89.

**Editor** Ștefan C. Vesa

**Received** 16 September 2012

**Accepted** 1 October 2012

**Published Online** 9 October 2012

**Funding** None reported

**Conflicts/  
Competing  
Interests** None reported